

Tissue Engineering: Current Research

Chapter 1

The “Self-Assembly” Approach for Lower Urinary Tract Tissue Engineering: Regenerative Medicine and Disease Modelling

Sasseville S^{1,2}, Boudreau M^{1,3}, Pellerin FA^{1,4}, Caneparo C^{1,5}, Pellerin E^{1,3}, Chabaud S¹, Bolduc S^{1,6,7}

All three first authors contributed equally

¹Centre de Recherche en Organogénèse Expérimentale/LOEX, Regenerative Medicine Division, CHU de Québec-Université Laval Research Center, Québec, QC G1J 1Z4, Canada.

²Faculté de Sciences et Génie, Biologie, Université Laval, Québec, QC G1V 0A6, Canada.

³Faculté de Médecine, Sciences Biomédicales, Université Laval, Québec, QC G1V 0A6, Canada.

⁴Faculté de Sciences et Génie, Microbiologie, Université Laval, Québec, QC G1V 0A6, Canada.

⁵Faculté de Médecine, Biologie cellulaire et moléculaire, Université Laval, Québec, QC G1V 0A6, Canada.

⁶Division of Urology, Department of Surgery, CHU de Québec-Université Laval, Québec, QC G1V 4G2, Canada.

⁷Department of Surgery, Faculty of Medicine, Laval University, Québec, QC G1V 0A6, Canada.

*Correspondence to: Bolduc S, Centre de Recherche en Organogénèse Expérimentale/LOEX, Regenerative Medicine Division, CHU de Québec-Université Laval Research Center, Québec, QC G1J 1Z4, Canada.

Email: Stephane.Bolduc@fmed.ulaval.ca

Keywords: Tissue engineering; bladder; cancer; cystitis; urethra; hypospadias; stricture; self-assembly.

Abbreviations: 3D: three-dimensional; ALS: amyotrophic lateral sclerosis; BAMG: bladder acellular matrix graft; BCG: Bacillus Calmette-Guérin; BPA: Bisphenol A; DNA: deoxyribonucleic acid; ECM: extracellular matrix; HIV: Human immunodeficiency virus; HUVEC: human umbilical vein endothelial cell; IBC: intracellular bacteria colony; iPSC: Induced Pluripotent Stem cells; MRI: magnetic resonance imaging; MVEC: microvascular endothelial cell; NMDA: N-methyl-D-aspartate; PAC-A: type A proanthocyanidins; PCL: poly (ϵ -caprolactone); PLCL: (L-lactide-co- ϵ -caprolactone); PET: positron emission tomography; PGA: polyglycolic acid; PLA: polylactic acid; PLGA: copoly (lactic/glycolic) acid; QIR: quiescent intracellular reservoir; SIS: small intestine submucosa; TGF: Transforming Growth Factor; TURBT: transurethral resection of bladder tumour; UPEC: uropathogenic Escherichia coli; UTI: urinary tract infection.

1. Introduction

The lower urinary tract, mainly the bladder and urethra, can be affected by many congenital or acquired pathologies, which require surgical corrections. Currently, therapeutic

Citation: Bolduc S, (2021) *Tissue Engineering: Current Research, Vol. 1, Chapter 1, pp. 1-25.*

strategies can be effective for the less severe cases, but repairing or replacing severe ones remains a challenge due to the paucity of adequate tissues. This book chapter aims to succinctly describe the lower urinary tract and its most common pathologies requiring repair or replacement, which can be modelled using tissue engineering. An emphasis will be made on an innovative technique to produce tissue without the use of exogenous materials or the need for pre-existing scaffolds: the «self-assembly» developed by Dr. François A. Auger in the late 1990s.

2. Bladder

2.1. Anatomy

The bladder is the organ that stores urine produced by the kidneys [1]. From the lumen, the bladder wall is composed of a covering epithelium, a lamina propria, a muscularis, and an adventitia (Figure 1). The specialized pseudostratified epithelium of the bladder is called the urothelium [2]. The urothelium performs several functions, such as controlling patency and providing the first immune defence line to the bladder [3]. The urothelium is composed of apical, intermediate and basal layers [4]. On the apical surface of this urothelium are located umbrella-shaped cells, joined together by tight junctions [2]. These cells, often binucleated, are the most differentiated cells of the urothelium. The latter also shows an asymmetric urothelial membrane consisting of a plaque of uroplakine proteins, mostly extracellular, which seals the bladder, thus protecting it against toxic substances present in the urine [2,5]. The glycocalyx, a layer of polysaccharides and proteins, such as Tamm-Horstfal protein, could also be seen at the luminal surface but is mainly produced by the kidney. The middle layer consists of five to seven layers of cells when the bladder is empty, while the layers are stretch down to two or three when the bladder is full. Due to its ability to adapt to changes in urine volume, the urothelium can also be referred to as a transitional epithelium [2]. The basal layer is attached to the basement membrane [6,7]. Therefore, most of the progenitor cells used for the turnover of the epithelium are located in the basal layer.

In contrast, the progenitors used for fast regeneration following injuries are located in the intermediate layers. Three layers of smooth muscle cells form the Detrusor: an inner and outer layer of longitudinal muscle and a middle layer of circular muscle [1,8]. These different orientations of muscle fibres allow the bladder to contract and expel urine through the urethra. After urination, the detrusor muscle relaxes and allows the bladder to stretch again to accumulate urine without internal pressure increase [8].

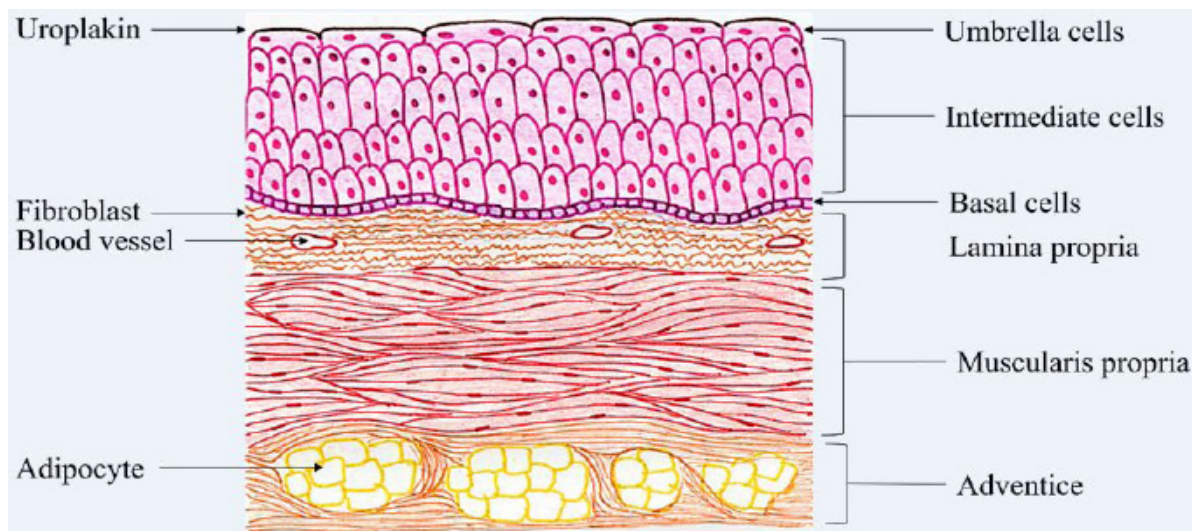


Figure 1: Schema of the anatomy of the bladder wall, including a focus on the urothelium. The bladder wall consists of 4 sections: the urothelium (epithelium), the lamina propria (connective tissue), the Detrusor (muscle layers) and the adventice (fat tissue). The urothelium can be divided into the superficial layer (umbrella cells, the most differentiated), intermediate layer (several layers of partially differentiated cells and containing some progenitors useful to repair injuries) and the basal layer (containing the less differentiated urothelial cells including progenitor/stem cells).

2.2. Pathologies

The most well-known bladder pathologies are bladder exstrophy, neurogenic bladder, painful bladder syndrome, cystitis, and bladder cancer. Bladder exstrophy is a congenital disease that is a malformation of the genitourinary tract exposing the bladder outside the body [9,10]. A neurogenic bladder is caused by neurological disorders such as spinal dysraphism, spinal cord injury, multiple sclerosis, and Parkinson's disease. This damage to the central nervous system causes dysfunction of urination, which usually results in urinary incontinence [11]. Painful bladder syndrome, also called interstitial cystitis, results in pain localized to the bladder, pelvis, and abdomen. Patients also experience pain during urination and a high frequency of urination [12]. Interstitial cystitis is more common in women than in men. The interstitial cystitis pathophysiology is unknown, but several theories have been put forward, such as a decreased glycosaminoglycans (GAG) layer, altered urothelium permeability, and uroinflammation [12]. Bladder exstrophy, neurogenic bladder, and interstitial cystitis are out of the scope of the present chapter that will focus on cystitis and bladder cancer, for which disease models were developed using the self-assembly technique.

2.2.1. Cystitis

2.2.1.1. Urinary tract infection

A urinary tract infection (UTI) can be classified as acute or chronic cystitis [13]. UTI risk in men is lower due to their longer urethra and prostatic fluid, which acts as an antibacterial agent [13]. Indeed, 40% of women will develop cystitis during their lifetime [14]. In addition, a decrease in the amount of estrogen produced during menopause, and an increase

in urine pH, with a physiological value between 4.5 and 8, contribute to the colonization of pathogens [14,15]. Cystitis is characterized by frequent urination accompanied by a burning sensation and tingling [14]. The majority of UTI are caused by uropathogenic *Escherichia coli* (UPEC) bacteria. In the intestine, bacteria migrate along the urethra to reach the bladder or even the kidneys, where they cause a UTI or pyelonephritis. UTIs are more frequent in women mainly because their urethra is shorter, and thus, the bacteria are more likely to reach the bladder before being wiped out or eliminated by a trip to the bathroom [16]. The clinical difficulty encountered during UTI treatment is the recurrence of infections. An estimated 25% of women will experience a relapse of UTI within six months [17]. Moreover, to add to that, 90% of infections are caused by *E.coli*, accounting for about 6-8 million cases in the USA each year [18]. The tendency of relapses suggests the presence of intracellular reservoirs in the bladder. Studies have shown that quiescent intracellular reservoirs (QIR) are present in the lower levels of the urothelium [19]. In these QIR, bacteria are somewhat asleep in an F-actine cocoon where they wait to be woken up and cause UTI recurrence. These relapses are caused every 3 to 6 months when the infected cells are differentiated to replace the superficial cells due to their desquamation [20]. The differentiation of these cells causes a cytoskeleton modification, which breaks down the F-actine around the QIR. The newly freed bacteria can then multiply and cause another infection, starting the cycle again.

2.2.1.2. ketamine-induced cystitis

Ketamine is a drug developed in the 1960s and commonly used as an anesthetic agent and an analgesic from a clinical point of view [21]. Its tendency to cause side effects, such as hallucinations and out-of-body experiences, has led it to be used as a recreational drug often used in parties and raves [22]. Subanesthetic doses of ketamine have been given to patients to remedy suicidal thoughts and have been given as an antidepressant [23]. A little over ten years ago, the connection between ketamine use and urinary tract damage was identified and studied [24]. The use of ketamine to alleviate the patient's pain is usually associated with damage to the bladder and other organs, which leads to a higher quantity of ketamine being used to control that pain. The ever-increasing dose of ketamine only worsens the damage to the urothelium. It leads to a vicious cycle of ketamine use, and the patient ends up with a ketamine addiction. A 2007 study demonstrated that ketamine abuse could induce hematuria, suprapubic pain and bladder inflammation [25]. Another study showed that the prescribed use of ketamine for chronic pain could still induce cystitis [26]. It is believed that ketamine and/or its metabolites could be responsible for urinary tract damages due to its presence in the urine for multiple days after ingestion [27]. Ketamine is a non-competitive N-methyl-D-aspartate (NMDA) receptor antagonist, and the NMDA receptor is responsible for calcium entry. The high concentrations of ketamine would lead to a calcium concentration elevation that would be toxic for the urothelium [28].

2.2.2. Bladder cancer

Bladder cancer is the fifth most common cancer in men and the ninth overall. Ageing and smoking also promote the development of bladder cancer [29]. Indeed, smoking accounts for 50 to 65% of bladder cancers [30]. The diagnosis of bladder cancer is usually made after the age of 70 [29]. Patients with bladder cancer may have symptoms such as hematuria, increased urination and irritation, lower back pain, or a tumour visible on medical imaging [29,31]. Three different presentations of bladder cancer. An adenocarcinoma is a rare form that starts in glandular cells located in the bladder's lining. The second form of cancer is squamous cell carcinoma, which starts in the squamous cells of the bladder lining. This type is often triggered by long-term inflammation or irritation of the bladder. The third type of cancer is urothelial carcinoma, accounting for 90% of diagnosed cancers [31,32]. This type of cancer includes tumours of the renal pelvis, ureters, bladder, and proximal urethra [29]. It can appear in a non-invasive and non-aggressive form that can cause recurrence after treatment [33]. These tumours can also be invasive and aggressive, characterized by a high risk of death. The stage of bladder cancer depends on the level of invasion of the bladder wall. Non-invasive cancers, such as tumours affecting only the urothelium and lamina propria, are treated differently from cancers that invade muscle [29]. Cancer can spread throughout the body through the lymphatic system and blood via metastases that start from the target organ [31]. The prevalence in men is higher than in women [33]. However, cancers diagnosed in women are generally more invasive, suggesting a potential role for hormones.

2.3. Current treatments

2.3.1. cystitis

Treatment for acute cystitis involves preventing the spread of bacterial infection to the kidneys. Although most uncomplicated cystitis is cured without treatment, most patients use treatments, such as antibiotics to reduce the associated symptoms [13,15]. Factors such as allergies and patient tolerance, drug side effects, and drug cost should be considered [13]. First-line antibiotics used include nitrofurantoin, fosfomycin, and pivmecillinam. Some second-line antimicrobial agents are used for patients in whom first-line antibiotics have not worked [13]. Additionally, other treatments considered non-antimicrobial are used to prevent uncomplicated UTIs, such as D-mannose and cranberry extract. D-mannose, excreted in the urine, prevents bacteria from adhering to the urothelium [34]. As for cranberries, several formats exist, such as cranberry juice, whole cranberry or concentrated cranberry extracts, with a high content of type A proanthocyanidins (PAC-A) [35]. These PAC-A can be used to prevent urinary tract infections by inhibiting the adhesion of bacteria to the urothelium [35].

2.3.2. Bladder cancer

Several factors will influence the prognosis, such as the cancer stage, the size of the tumours, the presence of recurrence and the type of cancer cells. Therefore, bladder cancer can be treated in different ways. The first step is to validate the presence of cancer by using cystoscopy, assessing kidney function and assessing the upper urinary tract by imaging [36]. In order to choose the most appropriate treatment to cure cancer, it is necessary to determine the stage of the disease using the staging process. Several exams can be considered, such as CT scan, magnetic resonance imaging (MRI) and positron emission tomography (PET), mainly used to detect malignant tumour cells. The different treatments currently used are surgery, chemotherapy, radiotherapy, immunotherapy and targeted therapy.

Surgery is the first-line treatment for the treatment of bladder cancer [37]. For non-invasive cancers, endoscopic transurethral resection of bladder tumour (TURBT) is the preferred treatment. TURBT can be used to diagnose and remove superficial bladder tumours present through the urethra. With this technique, it is possible to take a sample of the bladder's muscle layer at the base of the tumour to assess the level of invasion [38]. However, due to the high rate of recurrence using this method, patients may have to resort to chemotherapy or intravesical immunotherapy, such as Bacillus Calmette-Guérin (BCG) [37,39]. Partial or radical cystectomy may also be used depending on the degree of invasion [31]. Radical cystectomy consists in completely removing the bladder, while partial cystectomy removes only part of it. For invasive bladder cancers, radical cystectomy followed by chemotherapy is the recommended treatment [36]. When cystectomy is not considered [bladder sparing], i.e. the bladder may be retained in some patients, radiotherapy can be combined with chemotherapy [39]. Targeted therapy involves specifically attacking cancer cells and may cause minor damage to healthy cells, unlike chemotherapy and radiation therapy [31].

Patients may need adjuvant or neoadjuvant therapy such as chemotherapy or immunotherapy. Chemotherapy can be given before surgery to eliminate the risk of metastasis and after surgery to reduce the risk of recurrence [31]. Regarding immunotherapy, BCG is the most widely used treatment [37]. To fight against cancer, immunotherapy uses the patient's immune system [31]. BCG uses a tuberculosis vaccine containing attenuated bacteria that bind to the urothelium [40]. Following the internalization of BCG by urothelial cells, an immune response is triggered, ultimately allowing the destruction of cancer cells. In addition, the use of BCG improves cytotoxicity against tumour cells in the bladder since these cellular components stimulate the differentiation of immune cells [41]. Another treatment is radiation therapy, which involves using x-rays to eradicate or prevent the growth of cancer cells [31] by causing DNA damage that results in the death of cancer cells [42].

2.4. Alternative solutions (including tissue engineering)

Bladder replacement or repair can also be considered in some instances, for example, during a cystectomy. The preferred technique is replacing the bladder wall by using a urinary diversion with an ileal conduit. It is resistant, accessibility and well-vascularized [43, 44]. This method involves using segments of the intestine to increase the bladder's surface area or build a neobladder [45]. However, several complications can be caused by this technique. Indeed, knowing that the primary role of the intestine is to absorb nutrients, patients using this technique may present, among other things, vitamin deficiencies, metabolic acidosis, electrolyte imbalance, drug metabolism and liver problems [43].

In an attempt to circumvent these complications, tissue engineering of the bladder allows repair or replacement of this organ [44]. The reconstructed tissue must be biocompatible, perform the functions of the native tissue, support a vascular network, exhibit appropriate mechanical properties, allow intercellular communications and cell adhesion, and differentiation and migration [46]. To achieve these goals, biomaterials and cells, sometimes stem cells, are used to reconstruct the bladder [44]. Scaffolds are the biomaterials used to direct cell growth and guide tissue development. Biomaterials must be strong enough to withstand the mechanical forces induced by neighbouring structures and those generated by emptying and filling the bladder. In addition, they must be biodegradable to allow full tissue development [43]. These scaffolds can be derived from synthetic or natural components or be decellularized matrices [47].

Regarding synthetic matrices, the most frequently studied are polyglycolic acid (PGA), polylactic acid (PLA), copoly (lactic/glycolic) acid (PLGA) and poly (ϵ -caprolactone) (PCL). These synthetic polymer scaffolds are biodegradable, biocompatible and allow adequate cell growth [48]. However, these synthetic biomaterials have various drawbacks, some of which are shown in **Table 1**. In addition, silk fibroin is also used to fabricate bladder scaffolds due to its biomechanical characteristics [49].

The decellularized matrices mainly come from the organs of pigs since their bladder is similar to humans. Indeed, the matrices often originate from the decellularized bladder [bladder acellular matrix graft, BAMG] or the small intestine submucosa [SIS] [48]. These matrices are obtained from tissues from which all the cells have been eliminated, which allows the desired tissue development. In addition, this type of matrix allows rapid neovascularization and degrades slowly after implantation [43,48].

Table 1: Biomaterials, A non-exhaustive list of biomaterials used for bladder reconstruction with their advantages and drawbacks.

	Matrices	Advantages	Drawbacks
Synthetic	PGA	- Low risk of contamination	- Inadequate environment for epithelial cell differentiation. - Potential for inflammatory reactions
	PLA	- Biodegradable	
	PLGA	- Biocompatible	
	PCL	- Low cost - Highly tunable	
Natural	BAMG	- Retention of most of the biological and mechanical properties of native tissues	- Potential for immune reaction - Not entirely adequate for migration and differentiation - Limited neovascularization
	SIS	- Slow rate of degradation after implantation - Better environment for migration and differentiation than synthetic biomaterials	
	S i l k fibroin	- Biodegradable - Biocompatible	

2.5. Self-assembly protocol

The self-assembly method is a tissue-engineered reconstruction technique that produces tissues similar to native tissues and does not require biomaterials [50]. Indeed, this method involves using the patient's cells to rebuild the tissue [46]. This helps reduce immunological risks and transplant rejection. Dr. François A. Auger introduced this technique in the late 1990s to produce blood vessels then bilayered skin substitutes for severely burned patients. It derived from the discovery of Switzer and Summer in 1972 that human skin fibroblast culture allows collagen synthesis in the presence of ascorbate [vitamin C] [51], and the one of Senoo and Hata in 1989 that L-ascorbic acid 2-phosphate stimulates collagen accumulation, cell proliferation, and formation of a three-dimensional tissue-like substance by skin fibroblasts [52]. Ascorbic acid is a cofactor that allows the enzyme propyl-4-hydroxylase to produce and assemble collagen fibres and thus form an extracellular matrix (ECM) [53]. Indeed, type I and III collagens, along with elastin, glycosaminoglycans and several others, constitute the main components of the ECM through a structural network, allowing the mechanical resistance of the tissues [54]. Without sufficient mechanical strength, the tissue is too fragile and cannot be manipulated or grafted onto the patient. It is possible to seed the top of the scaffold formed by the fibroblasts with keratinocytes to form an epidermis, in the case of the skin, and endothelial seed cells inside the tube formed by rolling the scaffold around a mandrel, in the case of the blood vessels. Due to the composition and organization of the ECM close to the native tissue, and the use of organ-specific cells, the epithelium reaches a high level of differentiation [55,56]. With time and skin and blood vessels, different tissues were derived, such as the cornea, adipose tissues, urological tissues (bladder and urethra, the topic of this chapter), vagina, neural tubes or cardiac valves [57].

In addition to the obvious clinical applications, fundamental study models have been derived from these reconstructed tissues to understand pathologies in a context close to na-

tive human tissue. Indeed, most studies are performed on inadequate models associated with a low potential for clinical translation [58]. For example, monolayers of cells in plastic Petri dishes generally do not make it possible to recreate either the complexity of the organization of the tissue in three dimensions, and therefore, the cell dynamics, polarity in particular, and hence differentiation, or the interactions between cells and the ECM, which a protein coating can very partially represent. Similarly, laboratory animals often show significant differences between species, humans included. The contribution of these models to the advancement of science should not be underestimated. Nevertheless, biological complexity obliges us to recognize that it is necessary to develop more sophisticated models, and perhaps in the mid-term, not only to recreate tissues in the laboratory but also to interconnect them, similarly to organ-on-chip technology, which is exciting but too simplistic given the complexity of realistic biological conditions.

In this context, the self-assembly technique has made it possible to study skin pathologies such as hypertrophic scars [59], systemic sclerosis (scleroderma) [60], melanoma [61,62] and basal carcinoma, psoriasis [63], epidermolysis bullosa [64], neurofibromatosis [65], or skin manifestations of amyotrophic lateral sclerosis (ALS) [66]. Studies have also been carried out to understand better Fuchs' dystrophy, which affects the corneal endothelium [67]. Models have also been developed to infect an immunocompetent vaginal mucosa model by the human immunodeficiency virus (HIV) [68]. These various models could also serve as a solid basis for conducting permeability studies for the pharmaceutical industry as current in vitro models often lack complexity.

2.5.1. Bladder reconstruction using the self-assembly protocol

Using the same protocol designed to reconstruct bilayered skin, bladder substitutes were produced using human dermal fibroblasts and porcine urothelial cells [69,70]. First, the use of porcine dermal fibroblasts was evaluated but did not allow reaching a sufficient mechanical resistance to be grafted in pigs, the reference model for bladder [71]. Next, porcine urothelial cells were also used because obtaining a bladder biopsy from pigs is more accessible than in humans. A completely human-derived tissue was then produced [72], and finally, organ-specific fibroblasts replaced dermal fibroblasts, allowing a better differentiation of the urothelium [55]. Stimulation in the bioreactor was also tested but not significantly impacted the differentiation of the bladder urothelium.

2.5.2. Protocol for reconstruction (Figure 2)

Fibroblasts obtained from a bladder biopsy are cultured in vitro in the presence of 50 µg/ml ascorbate for four weeks to produce a stroma sheet. The use of a paper anchor and weights helps to limit the contraction of the reconstructed tissue [70]. After one month of culture, three sheets of bladder stroma are superimposed to form a thicker and more resistant scaffold.

The urothelial cells, also extracted from a bladder biopsy, are then seeded on the scaffold. After a 1-week horizontal expansion of urothelial cells, the reconstructed tissue is raised at the air/liquid interface, allowing the upper surface to come into contact with air, stimulating the maturation of urothelial cells [70]. The final three-dimensional tissue resulting from this self-assembly protocol can be easily manipulated and potentially grafted. Recently, large surface tissues have been produced for the skin, and larger grafts could be produced for bladder augmentation in a large animal.

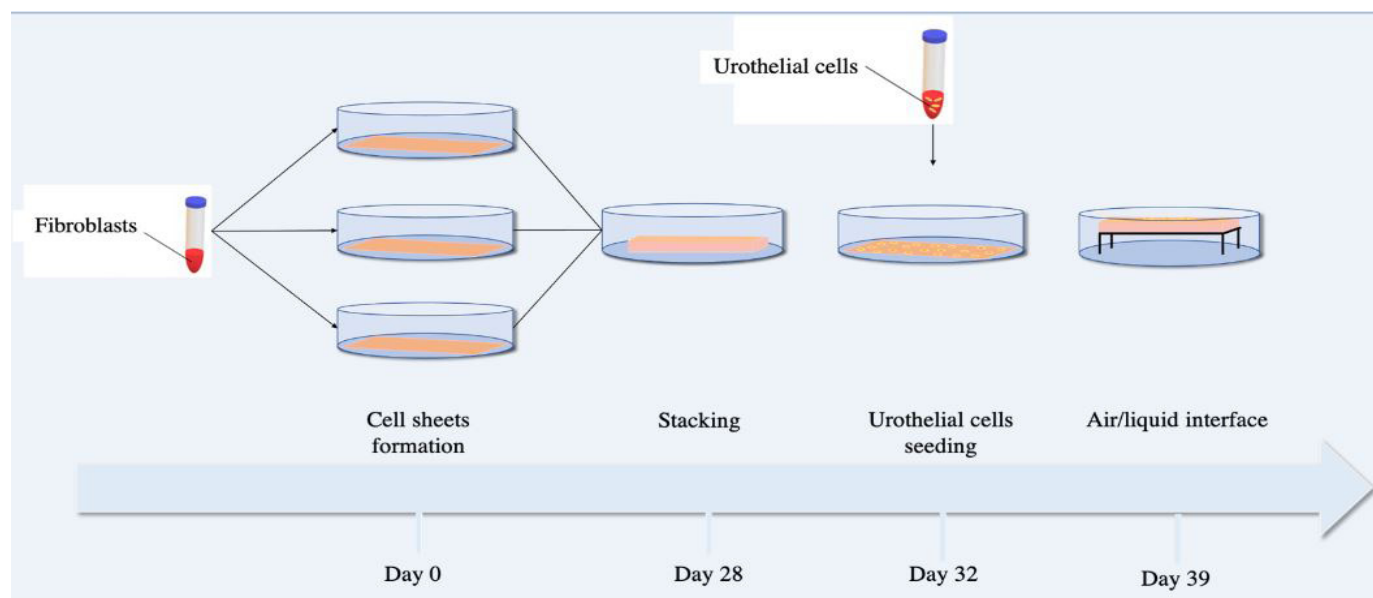


Figure 2: Production of urological flat models using self-assembly technique. The process takes two months, the first month to produce the stroma and the second month to allow epithelial differentiation. The protocol derived from the initial protocol used to produce skin substitutes designed by Dr. François A. Auger at LOEX. By varying the type of fibroblasts and epithelial cells, several kinds of tissues can be produced.

2.5.3. Disease modelling

2.5.3.1. Bladder cancer

Several 3D *in vitro* models of cancer have been produced by the self-assembly method [73], such as basal cell carcinoma, cutaneous neurofibroma [74], cutaneous melanoma and uveal melanoma [75]. The use of 3D models has several advantages as they have properties similar to microarchitecture *in vivo* and mimic cell-cell interactions *in vivo* [76]. These models have helped to understand the importance of the tumour microenvironment better. Using this self-assembly technique, a 3D human model was produced to study bladder cancer by monitoring the growth and invasion of cancer cells [77]. This human 3D model consists of a differentiated urothelium, fibroblasts, and endothelial cells (78). When the tissue is rebuilt, invasive or non-invasive cancer cells are deposited on the surface of the tissue as compact spheroids. As expected, non-invasive bladder cancer cells (here RT4 cell line) remained in the urothelium, whereas invasive bladder cancer cells (here T24 cell line) crossed the basal lamina and invaded the stroma. The use of tissue engineering for the modelling of pathologies makes it possible to understand the associated physiology better and thus to develop better treatments [76]. This model also allowed to test the effect of mitomycin C, a chemotherapeutic agent instilled in the

bladder used to treat superficial bladder cancer. The reduction of cancer cell viability was noted with time. This technique paves the way to personalized medicine using 3D human-derived tissues.

The bladder cancer model developed from the self-assembly technique could serve as a drug testing platform and for carcinogenic study. Bisphenol A (BPA) is a chemical often used in the manufacture of plastics. These bisphenols are endocrine disruptors that can modulate several signaling pathways that can lead to cancer development. Since bisphenols are stored in the bladder, they could lead to the development of bladder cancer [79]. The 3D model of bladder cancer will help to study the impact of BPA on the initiation and progression of bladder cancer [77].

2.5.3.2. Urinary tract infection

Using a 3D bladder model, the different UTI steps were reproduced to understand better the formation of intracellular bacteria colonies (IBC) and QIR. By maintaining the infection of 3D bladder models for a precise amount of time, it is possible to predict either infection is in progress or the bacteria are in QIR. The 3D model also allows us to try different UTI treatments at different stages of the infection, and therefore, the effects of that same treatment can be analyzed. The main goal for treatments against UTI would be to differentiate the QIR prematurely and then treat them with antibiotics to, in a way, empty the reservoirs. The use of chitosan as an exfoliator of the urothelium has been tested on mice and showed promising results. Another technique used has been developing mannosides or pilicides that interfere with bacterial attachment to the urothelium [80,81]. Using the 3D model could be the next best thing to get results, as close as possible, to treatments of actual patients. In the case of UTIs, 3D models pose two crucial factors, which show its promising future, the differentiation and stratification of the urothelium and the fact that the cells used are from human donors. The 3D model would better represent actual organs and does not require ethical approbation to be tested.

2.5.3.3. ketamine-induced cystitis

A 3D human bladder model can better understand the ketamine mechanisms and affect the lower urinary tract. For example, bladder tissue models were conditioned with different ketamine concentrations and then viewed by Masson's trichrome to observe how the tissues would be damaged by ketamine-induced apoptosis of the superficial cells [21]. Although a 3D human bladder model has not been used to find a treatment for ketamine damages to the bladder, such as induced cystitis and apoptosis, the 3D model has allowed a better understanding and visualization of the damages caused by ketamine. The examination of ketamine on the urothelium would be necessary to find a way to reduce the damages caused by ketamine use for either clinical uses or as an antidepressant. In some cases, using a Transforming Growth Factor (TGF)- β 1 receptor inhibitor showed promising results in reducing the damage to the

urothelium due to ketamine use [82]. Although the present study was performed on rat bladders and a monolayer of urothelial cells, the use of the TGF- β 1 receptor inhibitor, in combination with ketamine, reduced the thinning of the urothelium and bladder fibrosis. To better understand ketamine exposition and how it interacts with the urothelium, upgrades to the 3D human model would be optimal, including a vascular network and immune cells [21].

3. Urethra

3.1. Anatomy

Because of its size and position, the male urethra is more likely to contract pathologies than the female urethra (18-20 cm vs 4 cm respectively [83]). For this reason, we will focus on the male anatomy (Figure 3). The male urethra is divided into two major parts from the bladder neck to the urethral meatus: the posterior and the anterior urethra. The posterior urethra is further divided into the prostatic and the membranous urethra. The first one originates at the end of the bladder neck and crossing the prostate, whereas the membranous urethra is surrounded by the external urethral sphincter [83]. The latter allows controlling the urine flow. The anterior urethra comprises the bulbar urethra, the penile/pendulous urethra, and the fossa navicularis. It is covered by a layer of corpus spongiosum, a spongy tissue protecting the urethra, surrounded by a layer of tunica albuginea, a fibrous elastic tissue. The fossa navicularis is located at the tip of the penis and is lined by a stratified squamous epithelium resembling the buccal mucosa [46].

The lumen part of the urethra is lined with transitional epithelium, also called the urothelium. Its star shape is accommodating, depending on the internal pressure. During urine flow, the increase of pressure flattens the tissues and the epithelial cells, leading to a thinner tissue (up to twice its size after 5 hours) [84]. The urothelium is supported by connective tissues, which mainly play a nutritional function. The latter is surrounded by muscular fibers creating a peristaltic movement helping the urine flow. The muscular fibers also play a mechanical role by limiting the deformation of the urethra caused by increased internal pressure (**Figure 4**).

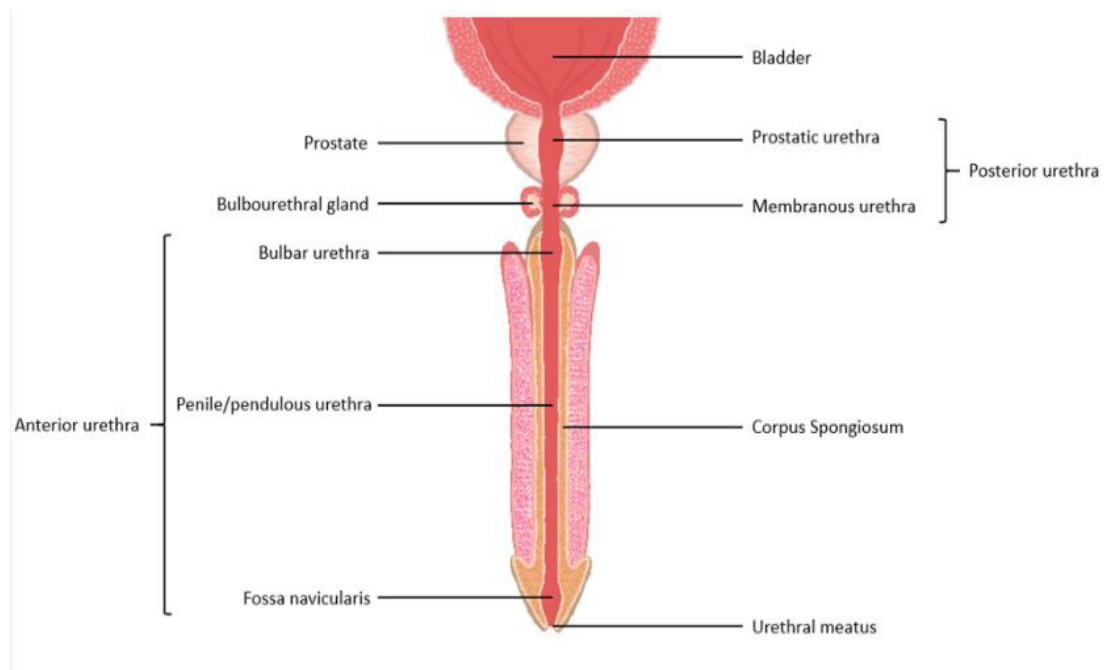


Figure 3: Schema of the anatomy of the male urethra. The male urethra consists of 2 sections, the posterior urethra, prostatic and membranous urethra, and the anterior urethra, including the bulbar urethra, pendulous urethra and fossa navicularis.

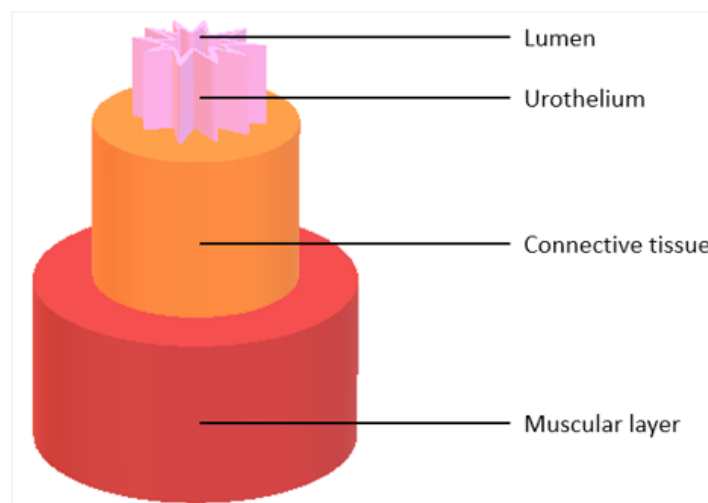


Figure 4: Details of urethral layers. The urethra consists of 3 successive layers. The lumen to the periphery, the urothelium, the lamina propria or connective tissue and finally, the muscular layer. The lumen of the urethra has a star shape at rest. Under the pressure of urine flow, the lumen becomes more circular. This morphological change helps to prevent high-pressure damage.

3.2. Pathologies

The penis can be affected by many pathologies requiring the reconstruction of the urethra. However, in this segment, we will focus only on urethral pathologies. There are two main types of pathologies affecting the male urethra: congenital and acquired pathologies.

3.2.1. Hypospadias

The most common congenital pathology is hypospadias [85], a malformation occurring during the embryologic tubularization of the urethra, leading to its shortening and causing a proximal urethral meatus opening on the ventral side of the penis. This malformation affects 0.4% of male newborns [86]. On the opposite, epispadias is characterized by a meatus

positioned on the dorsal side of the penis. The extreme cases may lead to infertility and incontinence. Even if the latter is less common than hypospadias, the same treatments may be required. Its severity depends on the position of the meatus compared to its normal position at the tip of the glans. If the meatus opening is localized on the scrotum, the urethra reconstruction is longer and more challenging than distal hypospadias.

3.2.2. Urethral strictures (or stenosis)

Strictures are the most common pathologies concerning the acquired anomalies, with 5 million office visits per year in the US [87]. The latter is due to a narrowing of the anterior urethra by scar tissues. It can be caused by surgery, bacterial or nonbacterial inflammation, sexually transmitted disease, and trauma or injury. If the narrowing happens on the posterior urethra, it is called a stenosis.

3.3. Current treatments

Because urethral pathology severity depends on many criteria, no gold standard has been established [88]. Among them, the position and the length of the pathology, the age of the patient, and pre-existing conditions or surgery. If the patient suffers from a short non-severe stricture or stenosis, the most cost-effective treatment is an endoscopic urethrotomy [89]. In this scenario, a small tube containing instruments and a camera are inserted through the urethra. The surgeon then uses a blade or a laser to incise the obstructed area. Considered a minor surgery, the urethrotomy is characterized by a shorter recovery time and a more nominal cost than a urethroplasty [89]. However, it is not suitable for more complex cases and can lead to more recurrences [90]. Also, it has been reported that the success rate is low after the first urethrotomy [91].

If the stenosis or stricture is not severe, a dilatation can be applied. Dilatation consists of introducing a tube in the urethra until it reaches the narrowing. By adding air to the tube, its diameter increases to exert pressure on the wall of the urethra to allow the liquid to pass. Unfortunately, studies showed that the fibrous tissues causing the narrowing continue to grow, leading to recurrences. In the last case scenario, a stent can be placed inside the urethra to maintain the opening.

Urethroplasty represents an alternative to urethrotomy to treat more complex cases [89]. A urethroplasty is characterized by an autologous reconstruction of the urethra using genital or non-genital tissues, such as tunica vaginalis (serous membrane covering the testicles), penile or scrotal skin flaps, or buccal/lingual mucosa graft. The latter can also be used to treat hypospadias and epispadias. However, surgeons are facing many disadvantages. Among them, the quantity of tissues that can be harvested is limited, representing a challenge for long strictures [92]. Furthermore, comorbidities, such as scars and complications, may occur at the donor site

(e.g. difficulty to open the mouth [92], scars on the testicle, etc.).

In last resort, patients who have undergone many failed surgeries and/or have a very complex case can be treated using a catheter to permanently connect the bladder to an external bag, allowing the excretion of urine. However, frequent visits to hospitals and many complications, such as a high risk of infection, significantly reduce the patient's quality of life [93].

3.4. Alternative solutions (including tissue engineering)

To avoid the necessity of harvesting autologous tissues and the associated complications, tissue engineering could represent an alternative. Indeed, the reconstruction of functional urethral tissues using only a tiny biopsy could provide adequate treatment for patients with complex anomalies. However, the engineered tissue must be biocompatible, fulfill the functions of the native tissue, support a vascular network, exhibit proper mechanical proprieties, allow intercellular communications and cell adhesion, and its differentiation and migration. Currently, the use of engineered tissues is limited by the high costs and the duration of production.

In order to reduce the costs, synthetic biomaterials like poly PLA and PLGA have been tested. They provide a solid base onto which cells can be seeded, with modifiable mechanical resistance and limited risk of contamination with xenogenes [94]. Unfortunately, studies have shown that synthetic biomaterials do not offer suitable environments for epithelial cell differentiation, limiting the biologic function of the obtained tissue [95]. Also, hydrolytic products can be released during their biodegradation that can cause inflammatory reactions [95].

To bypass the adverse effects of synthetic biomaterials, scientists have tested natural biomaterials like scaffolds produced with collagen type I or silk. For example, silk fibroins exhibit good biomechanical proprieties, such as elasticity, biodegradability and biocompatibility. Pre-clinical results are encouraging, demonstrating efficient urothelium regeneration and smooth muscle cells [49], but further research is necessary to examine the clinical and long-term effects.

On the other side, decellularized ECM has been tested as a biomaterial. They are animal matrices or cadaveric organs that were decellularized through chemical, physical or enzymatic treatment. Among them, SIS, BAMG, pericardium, and acellular corpus spongiosum matrix have been intensely studied [46,94]. The main advantages are maintaining the architectural, mechanical, and chemical proprieties of the native tissue while eliminating the biological components that can cause immune reactions [94]. However, studies have shown that a small quantity of residual deoxyribonucleic acid (DNA) could remain, causing an immune risk for the patient [96].

Furthermore, this technique has been proven to be effective only on reconstructions smaller than 0.5cm. Indeed, the patient's cells have limited migration capacities on the matrix [97]. This problem could be overcome by seeding patient cells onto the decellularized matrix [98]. Unfortunately, the vascularization of those tissues remains limited, which increases the chances of necrosis or ischemia, ultimately leading to graft failure [99].

In order to gather the advantages of synthetic and natural biomaterials, it is possible to strengthen a collagen type I scaffold with synthetic materials. This combination creates a hybrid biomaterial with synthetic mechanical resistance and natural biocompatibility [100]. Furthermore, this hybrid type shows better results than substitutes using only collagen materials in elastin deposition and cell arrangement [101].

Relatively new technology consists of intelligent biomaterials. These biomaterials are considered "intelligent" because they can react to different stimuli, such as light, pH, ionic strength and temperature [95,102,103]. Of particular interest, biomaterials were designed to expand in the presence of a stimulus and to return to its natural shape when over [104]. This principle can be adapted to the urethra with a graft capable of returning to its shape after erection or urine passage. Even if there is limited research on the subject, the results are promising.

Another alternative consists of bioprinting 3D substitutes, allowing the total control of the microarchitecture of the tissue. Living cells are printed inside a biomaterial adapted to patients. Zhang et al. succeeded in producing a urethral substitute with the same mechanical properties as the native tissue, using primary urothelial cells and smooth muscle cells printed inside a mix of hydrogel and PLCL (L-lactide-co- ϵ -caprolactone) [105]. Even though this technology is promising, its use is limited by the availability and cost of bio-ink [106]. Also, the size and the complexity of the tissue produced are limited, and the process is long [107].

3.5. Self-assembly

As previously discussed in this chapter [Figure 2], the self-assembly method can be used to produce tissues from patients' cells without exogenous scaffolds. The flat tissue model can be used in reconstructions that involve only a section of the circumference of the urethra. For pathologies affecting the whole circumference, tubular structures have been developed [Figure 5]. Previously used to fabricate blood vessels [108], the tubular self-assembly technique has been adapted for urethral reconstructions [109]. First, mesenchymal cells are cultured with ascorbate for four weeks to produce a sufficient ECM sheet. The sheet is then rolled around a mandrel to form a tubular structure and cultured with ascorbate for an additional two to four weeks to allow fusion of the multiple layers. Next, the mandrel is removed, and epithelial cells are seeded into the tube. The tissue is then placed in a bioreactor for two weeks. This flow ensures the maturation of the epithelial layer in dynamic conditions, leading to a ready to graft tissue.

Like the bladder substitutes, a genitourinary tubular tissue has been produced using the self-assembly method using human dermal fibroblasts and porcine urothelial cells. The reconstructed urethra exhibited adequate mechanical resistance and burst pressure [109]. Then, human urothelial cells were used for subsequent reconstructions, and tubes were matured in bioreactors. In contrast to static culture, dynamic culture allowed better differentiation of the urothelium, showing histological proprieties close to the ones of the native tissue, with a significantly improved expression of keratin-20 and uroplakins [110].

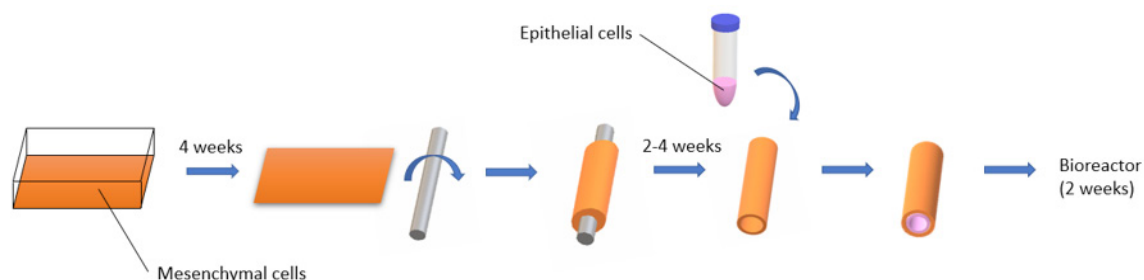


Figure 5: Production of urological tubular models using the self-assembly technique. The production of the tubular model takes longer than the flat model due to the time required to obtain a complete fusion of the rolls. The step of maturation of the urothelial cells is done in dynamic conditions using a bioreactor.

4. Challenges and perspectives

The lower urinary tract, including bladder and urethra, presents pathologies, which may require organ reconstruction. Tissue engineering can be an alternative for the most severe cases, including those presenting complications and recurrences. Indeed, some of the current treatments (e.g. enterocystoplasty) are still used by clinicians because no other alternatives are available, even if the tissues used for these surgeries have functions that differ significantly from those of the urinary tract tissues. In many cases, those grafts could not fulfill the primary function of the organs but also present side effects. To circumvent these inconveniences, reconstructing organ-specific substitutes using the self-assembly technique without adding an exogenous scaffold can represent an alternative for these patients; however, the latter present inconvenient and challenges.

One of the drawbacks of the self-assembly protocol, especially in severely burned patients, is the time required to produce the substitute. The production requires about two months, a longer time than the competitors using exogenous matrices, synthetic, natural or decellularized. However, in the context of the repair or replacement of sections of the lower urinary tract, the cases are rarely life-threatening, especially for the cases of congenital anomalies.

It should also be noted that, as a corollary, the cost of production is higher than the biomaterial produced by the industry. Nevertheless, as substitutes produced using the self-assembly technique show, contrarily to many grafts prepared using biomaterials, a better level of differentiation of the epithelium offers a barrier function as soon as the graft is in place. Thus,

it potentially lowers the rate of recurrence and complication. Consequently, it should reduce the overall cost for the healthcare system.

In the reconstruction of substitutes using organ-specific cells, a biopsy from the patients is needed. Unfortunately, some patients, especially those suffering from congenital anomalies or cancer, may present cells that cannot be used [111]. It is the case for self-assembly but also for all techniques using organ-specific cells. Nevertheless, shortly, the use of induced pluripotent stem cells (IPSC) could allow, from a simple blood sample, to obtain the different cell types needed for the reconstruction.

Finally, even if the ECM architecture and the microenvironment of substitutes produced by the self-assembly protocol using organ-specific cells are very close to native tissues, they remain simple, comprising 2 or 3 types of cells, which is far from the complexity of the native tissues. Nevertheless, this model complexification could lead us soon to produce more complex organs, such as kidneys or prostate.

Among the challenges to be met, the production of thick and then endothelialized tissue is on track to be completed. Indeed, whether the objective is to reconstruct tissues for transplantation or to conceive models as complete as possible, vascular network formation within the 3D tissue is essential. For example, the early stages of metastasis or the diffusion dynamics of various factors within the tissue [112] could be better studied in such models. Creating a 3D network of capillaries inside tissues produced by the self-assembly technique has been done using several approaches, which have given interesting results in the clinic by demonstrating that tissues produced with these approaches were perfused more quickly than non-endothelialized tissues. Initially, the surface of ECM sheets was seeded by human umbilical cord vein endothelial cells (HUVEC) or microvascular endothelial cells (MVEC) just before the stacking step to form an endothelialized stroma [113,114]. Recently, another technique was introduced. The HUVEC / MVEC were seeded with the stromal cells to produce the sheet and formed a capillary network throughout its entire thickness [115]. It was then possible to reseed endothelial cells and stromal cells on the ECM sheet to thicken it and homogenize the distribution of cells. Reseeded sheets can also be stacked to have a network of capillaries harmoniously distributed in relatively thick tissue.

Personalized medicine is the future medicine where each person can receive appropriate treatment for the pathology that affects him or her, adapted to each unique profile [116-119]. In this future, health costs will be reduced by avoiding the use of expensive drugs that may not prove helpful for a specific person, therefore, shortening treatment times and reducing side effects. Still unimaginable a half-century ago, but today within our reach, the development of complex research models from a patient's cells where all aspects could be parameterized and controlled, unlike current cellular or animal models, open new ways to discover better

treatments. Also, people will be able to have access to a range of tissues reconstructed in the laboratory with their cells and therefore perfectly immuno-compatible, having a degree of differentiation, and therefore functionality, as high as possible, allowing a return to a better quality of life. Thus, direct clinical applications and advancement of knowledge originating from tissue engineering now have the potential to change the face of medicine.

5. References

1. Lanzotti NJ, Tariq MA, Bolla SR. Physiology, Bladder. StatPearls. Treasure Island (FL): StatPearls Publishing; 2021.
2. Bolla SR, Odeluga N, Jetti R. Histology, Bladder. StatPearls. Treasure Island (FL): StatPearls Publishing; 2021.
3. Lazzeri M. The physiological function of the urothelium-more than a simple barrier. *Urol Int.* 2006;76(4):289-95.
4. Birder L, Andersson K-E. Urothelial signaling. *Physiol Rev.* 2013;93(2):653-80.
5. Matuszewski MA, Tupikowski K, Dołowy Ł, Szymańska B, Dembowski J, Zdrojowy R. Uroplakins and their potential applications in urology. *Cent European J Urol.* 2016;69(3):252-7.
6. Dalghi MG, Montalbetti N, Carattino MD, Apodaca G. The Urothelium: Life in a Liquid Environment. *Physiol Rev.* 2020;100(4):1621-705.
7. Khandelwal P, Abraham SN, Apodaca G. Cell biology and physiology of the uroepithelium. *Am J Physiol Renal Physiol.* 2009;297(6):F1477-F501.
8. Sam P, Nassereddin A, LaGrange CA. Anatomy, Abdomen and Pelvis, Bladder Detrusor Muscle. StatPearls. Treasure Island (FL): StatPearls Publishing; 2021.
9. Tshimbayi M, Ndua D, Kazadi C, Kwete LS, Bugeme M, Mubinda PK, et al. Bladder exstrophy: about a case diagnosed tardily. *Pan Afr Med J.* 2014;17:172-.
10. Caneparo C, Brownell D, Chabaud S, Bolduc S. Genitourinary Tissue Engineering: Reconstruction and Research Models. 2021;Bioengineering.
11. Ginsberg D. The epidemiology and pathophysiology of neurogenic bladder. *Am J Manag Care.* 2013;19(10 Suppl):s191-6.
12. Daniels AM, Schulte AR, Herndon CM. Interstitial Cystitis: An Update on the Disease Process and Treatment. *J Pain Palliat Care Pharmacother.* 2018;32(1):49-58.
13. Li R, Leslie SW. Cystitis. StatPearls. Treasure Island (FL): StatPearls Publishing; 2021.
14. Lala V, Minter DA. Acute Cystitis. StatPearls. Treasure Island (FL): StatPearls Publishing; 2021.
15. Bono MJ, Reygaert WC. Urinary Tract Infection. StatPearls. Treasure Island (FL): StatPearls Publishing; 2021.
16. Arnold, J.J., L.E. Hehn, and D.A. Klein. 2016. Common Questions About Recurrent Urinary Tract Infections in Women. *Am Fam Physician.* 93:560-569.
17. Foxman, B., B. Gillespie, J. Koopman, L. Zhang, K. Palin, P. Tallman, J.V. Marsh, S. Spear, J.D. Sobel, M.J. Marty, and C.F. Marrs. 2000. Risk factors for second urinary tract infection among college women. *Am J Epidemiol.* 151:1194-1205.
18. Zhang, L., and B. Foxman. 2003. Molecular epidemiology of Escherichia coli mediated urinary tract infections. *Front Biosci.* 8:e235-244.

19. Murray, B.O., C. Flores, C. Williams, D.A. Flusberg, E.E. Marr, K.M. Kwiatkowska, J.L. Charest, B.C. Isenberg, and J.L. Rohn. 2021. Recurrent Urinary Tract Infection: A Mystery in Search of Better Model Systems. *Frontiers in Cellular and Infection Microbiology*. 11.
20. Barber, A.E., J.P. Norton, T.J. Wiles, and M.A. Mulvey. 2016. Strengths and Limitations of Model Systems for the Study of Urinary Tract Infections and Related Pathologies. *Microbiol Mol Biol Rev*. 80:351-367.
21. Bureau, M., J. Pelletier, A. Rousseau, G. Bernard, S. Chabaud, and S. Bolduc. 2015. Demonstration of the direct impact of ketamine on urothelium using a tissue-engineered bladder model. *Can Urol Assoc J*. 9:E613-617.
22. Wood, D., A. Cottrell, S.C. Baker, J. Southgate, M. Harris, S. Fulford, C. Woodhouse, and D. Gillatt. 2011. Recreational ketamine: from pleasure to pain. *BJU Int*. 107:1881-1884.
23. Corriger, A., and G. Pickering. 2019. Ketamine and depression: a narrative review. *Drug Des Devel Ther*. 13:3051-3067.
24. Shahani, R., C. Streutker, B. Dickson, and R.J. Stewart. 2007. Ketamine-associated ulcerative cystitis: a new clinical entity. *Urology*. 69:810-812.
25. Chu, P.S., S.C. Kwok, K.M. Lam, T.Y. Chu, S.W. Chan, C.W. Man, W.K. Ma, K.L. Chui, M.K. Yiu, Y.C. Chan, M.L. Tse, and F.L. Lau. 2007. 'Street ketamine'-associated bladder dysfunction: a report of ten cases. *Hong Kong Med J*. 13:311-313.
26. Storr, T.M., and R. Quibell. 2009. Can ketamine prescribed for pain cause damage to the urinary tract? *Palliat Med*. 23:670-672.
27. Parkin, M.C., S.C. Turfus, N.W. Smith, J.M. Halket, R.A. Braithwaite, S.P. Elliott, M.D. Osselton, D.A. Cowan, and A.T. Kicman. 2008. Detection of ketamine and its metabolites in urine by ultra high pressure liquid chromatography-tandem mass spectrometry. *J Chromatogr B Analyt Technol Biomed Life Sci*. 876:137-142.
28. Baker, S.C., S. Shabir, N.T. Georgopoulos, and J. Southgate. 2016. Ketamine-Induced Apoptosis in Normal Human Urothelial Cells: A Direct, N-Methyl-d-Aspartate Receptor-Independent Pathway Characterized by Mitochondrial Stress. *Am J Pathol*. 186:1267-1277.
29. Lenis AT, Lec PM, Chamie K, Mshs MD. Bladder Cancer: A Review. *Jama*. 2020;324(19):1980-91.
30. Saginala K, Barsouk A, Aluru JS, Rawla P, Padala SA, Barsouk A. Epidemiology of Bladder Cancer. *Med Sci (Basel)*. 2020;8(1).
31. Board PDQATE. Bladder Cancer Treatment (PDQ®): Patient Version. PDQ Cancer Information Summaries. Bethesda (MD): National Cancer Institute (US); 2002.
32. Kaseb H, Aeddula NR. Bladder Cancer. *StatPearls*. Treasure Island (FL): StatPearls Publishing; 2021.
33. Dietrich B, Srinivas S. Urothelial carcinoma: the evolving landscape of immunotherapy for patients with advanced disease. *Res Rep Urol*. 2018;10:7-16.
34. De Nunzio C, Bartoletti R, Tubaro A, Simonato A, Ficarra V. Role of D-Mannose in the Prevention of Recurrent Uncomplicated Cystitis: State of the Art and Future Perspectives. *Antibiotics (Basel)*. 2021;10(4):373.
35. Occhipinti A, Germano A, Maffei ME. Prevention of Urinary Tract Infection with Oximacro, A Cranberry Extract with a High Content of A-Type Proanthocyanidins: A Pre-Clinical Double-Blind Controlled Study. *Urol J*. 2016;13(2):2640-9.
36. DeGeorge KC, Holt HR, Hodges SC. Bladder Cancer: Diagnosis and Treatment. *Am Fam Physician*. 2017;96(8):507-14.
37. Metts MC, Metts JC, Milito SJ, Thomas CR, Jr. Bladder cancer: a review of diagnosis and management. *J Natl Med*

Assoc. 2000;92(6):285-94.

38. Kim LHC, Patel MI. Transurethral resection of bladder tumour (TURBT). *Transl Androl Urol.* 2020;9(6):3056-72.
39. Cheung G, Sahai A, Billia M, Dasgupta P, Khan MS. Recent advances in the diagnosis and treatment of bladder cancer. *BMC Med.* 2013;11:13-.
40. Okafor CN, Rewane A, Momodu, II. *Bacillus Calmette Guerin*. StatPearls. Treasure Island (FL): StatPearls Publishing; 2021.
41. Alhunaidi O, Zlotta AR. The use of intravesical BCG in urothelial carcinoma of the bladder. *Ecancermedalscience.* 2019;13:905-.
42. Jaffray DA, Gospodarowicz MK. Radiation Therapy for Cancer. In: Gelband H, Jha P, Sankaranarayanan R, Horton S, editors. *Cancer: Disease Control Priorities, Third Edition (Volume 3)*. Washington (DC): The International Bank for Reconstruction and Development / The World Bank; 2015.
43. El-Taji OMS, Khattak AQ, Hussain SA. Bladder reconstruction: The past, present and future. *Oncol Lett.* 2015;10(1):3-10.
44. Adamowicz J, Pokrywczynska M, Van Breda SV, Kloskowski T, Drewa T. Concise Review: Tissue Engineering of Urinary Bladder; We Still Have a Long Way to Go? *Stem Cells Transl Med.* 2017;6(11):2033-43.
45. Cody JD, Nabi G, Dublin N, McClinton S, Neal DE, Pickard R, et al. Urinary diversion and bladder reconstruction/ replacement using intestinal segments for intractable incontinence or following cystectomy. *Cochrane Database Syst Rev.* 2012;2012(2):CD003306-CD.
46. Caneparo C, Chabaud S, Bolduc S. Challenges and Perspectives in Male Anterior Urethral Reconstruction Using Tissue Engineering. *Urology : Research And Therapeutics Journal.* 2019; 2(1):127 47. Gill BC, Damaser MS, Cherman-sky CJ. Future Perspectives in Bladder Tissue Engineering. *Curr Bladder Dysfunct Rep.* 2014;10(4):443-8.
48. Serrano-Aroca Á, Vera-Donoso CD, Moreno-Manzano V. Bioengineering Approaches for Bladder Regeneration. *Int J Mol Sci.* 2018;19(6):1796.
49. Sack BS, Mauney JR, Estrada CR, Jr. Silk Fibroin Scaffolds for Urologic Tissue Engineering. *Curr Urol Rep.* 2016;17(2):16.
50. Auxenfans C, Fradette J, Lequeux C, Germain L, Kinikoglu B, Bechetoille N, et al. Evolution of three dimensional skin equivalent models reconstructed in vitro by tissue engineering. *Eur J Dermatol.* 2009;19(2):107-13.
51. Switzer B.R., Summer G.K. Collagen synthesis in human skin fibroblasts: Effects of ascorbate, -ketoglutarate and ferrous ion on proline hydroxylation. *J. Nutr.* 1972;102:721–728.
52. Hata R., Senoo H. L-ascorbic acid 2-phosphate stimulates collagen accumulation, cell proliferation, and formation of a three-dimensional tissuelike substance by skin fibroblasts. *J. Cell Physiol.* 1989;138:8–16.
53. Murad S, Grove D, Lindberg KA, Reynolds G, Sivarajah A, Pinnell SR. Regulation of collagen synthesis by ascorbic acid. *Proc Natl Acad Sci U S A.* 1981;78(5):2879-82.
54. Aitken KJ, Bägli DJ. The bladder extracellular matrix. Part II: regenerative applications. *Nat Rev Urol.* 2009;6(11):612-21.
55. Bouhout S., Chabaud S., Bolduc S. Organ-specific matrix self-assembled by mesenchymal cells improves the normal urothelial differentiation in vitro. *World J. Urol.* 2016;34:121–130.
56. Carrier P, Deschambeault A, Audet C, Talbot M, Gauvin R, Giasson CJ, Auger FA, Guérin SL, Germain L. Impact of cell source on human cornea reconstructed by tissue engineering. *Invest Ophthalmol Vis Sci.* 2009 Jun;50(6):2645-52.

57. Saba I., Jakubowska W., Bolduc S., Chabaud S. Engineering tissues without the use of a synthetic scaffold: A twenty-year history of the self-assembly method. *Biomed. Res. Int.* 2018;2018:5684679.
58. Bédard P, Gauvin S, Ferland K, Caneparo C, Pellerin È, Chabaud S, Bolduc S. Innovative Human Three-Dimensional Tissue-Engineered Models as an Alternative to Animal Testing. *Bioengineering (Basel)*. 2020 Sep 17;7(3):115.
59. Simon F, Bergeron D, Larochelle S, Lopez-Vallé CA, Genest H, Armour A, Moulin VJ. Enhanced secretion of TIMP-1 by human hypertrophic scar keratinocytes could contribute to fibrosis. *Burns*. 2012 May;38(3):421-7.
60. Corriveau MP, Boufaied I, Lessard J, Chabaud S, Sénécal JL, Grodzicky T, Chartier S, Raymond Y, Moulin VJ. The fibrotic phenotype of systemic sclerosis fibroblasts varies with disease duration and severity of skin involvement: reconstruction of skin fibrosis development using a tissue engineering approach. *J Pathol*. 2009 Mar;217(4):534-42.
61. Gibot L, Galbraith T, Huot J, Auger FA. Development of a tridimensional microvascularized human skin substitute to study melanoma biology. *Clin Exp Metastasis*. 2013 Jan;30(1):83-90.
62. Bourland J, Fradette J, Auger FA. Tissue-engineered 3D melanoma model with blood and lymphatic capillaries for drug development. *Sci Rep*. 2018 Sep 4;8(1):13191.
63. Jean J, Lapointe M, Soucy J, Pouliot R. Development of an in vitro psoriatic skin model by tissue engineering. *J Dermatol Sci*. 2009 Jan;53(1):19-25.
64. Dakiw Piaciski A, Larouche D, Ghani K, Bisson F, Cortez Ghio S, Larochelle S, Moulin VJ, Caruso M, Germain L. Translating the combination of gene therapy and tissue engineering for treating recessive dystrophic epidermolysis bullosa. *Eur Cell Mater*. 2018 Feb 14;35:73-86.
65. Roy V, Lamontagne R, Talagas M, Touzel-Deschênes L, Khuong HT, Saikali S, Dupré N, Gros-Louis F. Biofabrication of a three dimensional human-based personalized neurofibroma model. *Biotechnol J*. 2021 Mar 10:e2000250.
66. Paré B, Touzel-Deschênes L, Lamontagne R, Lamarre MS, Scott FD, Khuong HT, Dion PA, Bouchard JP, Gould P, Rouleau GA, Dupré N, Berthod F, Gros-Louis F. Early detection of structural abnormalities and cytoplasmic accumulation of TDP-43 in tissue-engineered skins derived from ALS patients. *Acta Neuropathol Commun*. 2015 Jan 31;3:5.
67. Goyer B, Thériault M, Gendron SP, Brunette I, Rochette PJ, Proulx S. Extracellular Matrix and Integrin Expression Profiles in Fuchs Endothelial Corneal Dystrophy Cells and Tissue Model. *Tissue Eng Part A*. 2018 Apr;24(7-8):607-615.
68. Saba I, Barat C, Chabaud S, Reyjon N, Leclerc M, Jakubowska W, Orabi H, Lachhab A, Pelletier M, Tremblay MJ, Bolduc S. Immunocompetent Human 3D Organ-Specific Hormone-Responding Vaginal Mucosa Model of HIV-1 Infection. *Tissue Eng Part C Methods*. 2021 Mar;27(3):152-166.
69. Magnan M, Berthod F, Champigny MF, Soucy F, Bolduc S. In vitro reconstruction of a tissue-engineered endothelialized bladder from a single porcine biopsy. *J Pediatr Urol*. 2006 Aug;2(4):261-70.
70. Bouhout S, Perron E, Gauvin R, Bernard G, Ouellet G, Cattan V, et al. In vitro reconstruction of an autologous, watertight, and resistant vesical equivalent. *Tissue Eng Part A*. 2010;16(5):1539-48.
71. Ouellet G, Dubé J, Gauvin R, Laterreur V, Bouhout S, Bolduc S. Production of an optimized tissue-engineered pig connective tissue for the reconstruction of the urinary tract. *Tissue Eng Part A*. 2011 Jun;17(11-12):1625-33.
72. Chabaud S, Marcoux TL, Deschênes-Rompré MP, Rousseau A, Morissette A, Bouhout S, Bernard G, Bolduc S. Lyso-phosphatidic acid enhances collagen deposition and matrix thickening in engineered tissue. *J Tissue Eng Regen Med*. 2015 Nov;9(11):E65-75.
73. Roy V, Magne B, Vaillancourt-Audet M, Blais M, Chabaud S, Grammond E, et al. Human Organ-Specific 3D Cancer Models Produced by the Stromal Self-Assembly Method of Tissue Engineering for the Study of Solid Tumors. *Biomed Res Int*. 2020;2020:6051210.

74. Roy V, Touzel-Deschênes L, Marques E, Kannu P, Khuong H, Dupre N, et al. Tissue-engineered skin model derived from neurofibromatosis type 1 (NF1) patients to study tumor genesis and to predict response to therapy (P4.057). *Neurology*. 2017.
75. Djigo AD, Bérubé J, Landreville S, Proulx S. Characterization of a tissue-engineered choroid. *Acta Biomater*. 2019;84:305-16.
76. Vasyutin I, Zerihun L, Ivan C, Atala A. Bladder Organoids and Spheroids: Potential Tools for Normal and Diseased Tissue Modelling. *Anticancer Res*. 2019;39(3):1105-18.
77. Ringuette-Goulet C, Bolduc S, Pouliot F. Modeling human bladder cancer. *World J Urol*. 2018;36(11):1759-66.
78. Ringuette Goulet C, Bernard G, Chabaud S, Couture A, Langlois A, Neveu B, et al. Tissue-engineered human 3D model of bladder cancer for invasion study and drug discovery. *Biomaterials*. 2017;145:233-41.
79. Pellerin E, Caneparo C, Chabaud S, Bolduc S, Pelletier M. Endocrine-disrupting effects of bisphenols on urological cancers. *Environ Res*. 2021;195:110485.
80. Mydock-McGrane, L., Z. Cusumano, Z. Han, J. Binkley, M. Kostakioti, T. Hannan, J.S. Pinkner, R. Klein, V. Kalas, J. Crowley, N.P. Rath, S.J. Hultgren, and J.W. Janetka. 2016. Antivirulence C-Mannosides as Antibiotic-Sparing, Oral Therapeutics for Urinary Tract Infections. *J Med Chem*. 59:9390-9408.
81. Chahales, P., P.S. Hoffman, and D.G. Thanassi. 2016. Nitazoxanide Inhibits Pilus Biogenesis by Interfering with Folding of the Usher Protein in the Outer Membrane. *Antimicrob Agents Chemother*. 60:2028-2038.
82. Wang, J., Y. Chen, D. Gu, G. Zhang, J. Chen, J. Zhao, and P. Wu. 2017. Ketamine-induced bladder fibrosis involves epithelial-to-mesenchymal transition mediated by transforming growth factor- β 1. *Am J Physiol Renal Physiol*. 313:F961-f972.
83. Stranding S. *Gray's Anatomy 41st Edition The Anatomical Basis of Clinical Practice* 2015 p.1261-1264.
84. Truschel ST, Wang E, Ruiz WG, Leung SM, Rojas R, Lavelle J, et al. Stretch-regulated exocytosis/endocytosis in bladder umbrella cells. *Mol Biol Cell*. 2002;13(3):830-46.
85. Nelson CP, Park JM, Wan J, Bloom DA, Dunn RL, Wei JT. The increasing incidence of congenital penile anomalies in the United States. *J Urol*. 2005;174(4 Pt 2):1573-6.
86. Keays MA, Dave S. Current hypospadias management: Diagnosis, surgical management, and long-term patient-centred outcomes. *Can Urol Assoc J*. 2017;11(1-2Suppl1):S48-S53.
87. Mangera A, Osman N, Chapple C. Evaluation and management of anterior urethral stricture disease. *F1000Res*. 2016;5.
88. Barbagli G, Lazzeri M. Surgical treatment of anterior urethral stricture diseases: brief overview. *Int Braz J Urol*. 2007;33(4):461-9.
89. Wright JL, Wessells H, Nathens AB, Hollingworth W. What is the most cost-effective treatment for 1 to 2-cm bulbar urethral strictures: societal approach using decision analysis. *Urology*. 2006;67(5):889-93.
90. Albers P, Fichtner J, Bruhl P, Muller SC. Long-term results of internal urethrotomy. *J Urol*. 1996;156(5):1611-4.
91. Santucci R, Eisenberg L. Urethrotomy has a much lower success rate than previously reported. *J Urol*. 2010;183(5):1859-62.
92. Dublin N, Stewart LH. Oral complications after buccal mucosal graft harvest for urethroplasty. *BJU Int*. 2004;94(6):867-9.
93. Wilson M. Causes and management of indwelling urinary catheter-related pain. *Br J Nurs*. 2008;17(4):232-9.

94. Caneparo C, Chabaud S, Bolduc S. Reconstruction of Vascular and Urologic Tubular Grafts by Tissue Engineering. *Processes*. 2021; 9(3):513
95. Abbas TO, Yalcin HC, Pennisi CP. From Acellular Matrices to Smart Polymers: Degradable Scaffolds that are Transforming the Shape of Urethral Tissue Engineering. *Int J Mol Sci*. 2019;20(7).
96. Feil G, Christ-Adler M, Maurer S, Corvin S, Rennekampff HO, Krug J, et al. Investigations of urothelial cells seeded on commercially available small intestine submucosa. *Eur Urol*. 2006;50(6):1330-7.
97. Dorin RP, Pohl HG, De Filippo RE, Yoo JJ, Atala A. Tubularized urethral replacement with unseeded matrices: what is the maximum distance for normal tissue regeneration? *World J Urol*. 2008;26(4):323-6.
98. De Filippo RE, Yoo JJ, Atala A. Urethral replacement using cell-seeded tubularized collagen matrices. *J Urol*. 2002;168(4 Pt 2):1789-92; discussion 92-3.
99. Zhang Y, Frimberger D, Cheng EY, Lin HK, Kropp BP. Challenges in a larger bladder replacement with cell-seeded and unseeded small intestinal submucosa grafts in a subtotal cystectomy model. *BJU Int*. 2006;98(5):1100-5.
100. de Jonge P, Simaioforidis V, Geutjes P, Oosterwijk E, Feitz W. Ureteral reconstruction with reinforced collagen scaffolds in a porcine model. *J Tissue Eng Regen Med*. 2018;12(1):80-8.
101. Sloff M, Simaioforidis V, Geutjes PJ, Hoogenkamp HR, van Kuppevelt TH, Daamen WF, et al. Novel tubular constructs for urinary diversion: a biocompatibility study in pigs. *J Tissue Eng Regen Med*. 2017;11(8):2241-9.
102. Ribeiro C, Sencadas V, Correia DM, Lanceros-Mendez S. Piezoelectric polymers as biomaterials for tissue engineering applications. *Colloids Surf B Biointerfaces*. 2015;136:46-55.
103. Lv X, Feng C, Liu Y, Peng X, Chen S, Xiao D, et al. A smart bilayered scaffold supporting keratinocytes and muscle cells in micro/nano-scale for urethral reconstruction. *Theranostics*. 2018;8(11):3153-63.
104. Hardy JG, Palma M, Wind SJ, Biggs MJ. Responsive Biomaterials: Advances in Materials Based on Shape-Memory Polymers. *Adv Mater*. 2016;28(27):5717-24.
105. Zhang K, Fu Q, Yoo J, Chen X, Chandra P, Mo X, et al. 3D bioprinting of urethra with PCL/PLCL blend and dual autologous cells in fibrin hydrogel: An in vitro evaluation of biomimetic mechanical property and cell growth environment. *Acta Biomater*. 2017;50:154-64.
106. Gu BK, Choi DJ, Park SJ, Kim MS, Kang CM, Kim CH. 3-dimensional bioprinting for tissue engineering applications. *Biomater Res*. 2016;20:12.
107. Kawecki F, Clafshenkel WP, Auger FA, Bourget JM, Fradette J, Devillard R. Self-assembled human osseous cell sheets as living biopapers for the laser-assisted bioprinting of human endothelial cells. *Biofabrication*. 2018;10(3):035006.
108. L'Heureux N, Paquet S, Labbe R, Germain L, Auger FA. A completely biological tissue-engineered human blood vessel. *FASEB J*. 1998;12(1):47-56.
109. Magnan M, Levesque P, Gauvin R, Dube J, Barrieras D, El-Hakim A, et al. Tissue engineering of a genitourinary tubular tissue graft resistant to suturing and high internal pressures. *Tissue Eng Part A*. 2009;15(1):197-202.
110. Cattani V, Bernard G, Rousseau A, Bouhout S, Chabaud S, Auger FA, et al. Mechanical stimuli-induced urothelial differentiation in a human tissue-engineered tubular genitourinary graft. *Eur Urol*. 2011;60(6):1291-8.
111. Neophytou CM, Panagi M, Stylianopoulos T, Papageorgis P. The Role of Tumor Microenvironment in Cancer Metastasis: Molecular Mechanisms and Therapeutic Opportunities. *Cancers (Basel)*. 2021 Apr 23;13(9):2053.
112. Subramaniam R, Hinley J, Stahlschmidt J, Southgate J. Tissue engineering potential of urothelial cells from diseased bladders. *J Urol*. 2011 Nov;186(5):2014-20.

113. Guillemette MD, Gauvin R, Perron C, Labbé R, Germain L, Auger FA. Tissue-engineered vascular adventitia with vasa vasorum improves graft integration and vascularization through inosculation. *Tissue Eng Part A*. 2010 Aug;16(8):2617-26.
114. Imbeault A, Bernard G, Rousseau A, Morissette A, Chabaud S, Bouhout S, Bolduc S. An endothelialized urothelial cell-seeded tubular graft for urethral replacement. *Can Urol Assoc J*. 2013 Jan-Feb;7(1-2):E4-9.
115. Chabaud S, Rousseau A, Marcoux TL, Bolduc S. Inexpensive production of near-native engineered stromas. *J Tissue Eng Regen Med*. 2017 May;11(5):1377-1389.
116. Bloss CS, Jeste DV, Schork NJ. Genomics for disease treatment and prevention. *Psychiatr Clin North Am*. 2011 Mar;34(1):147-66.
117. Kamran SC, Efstathiou JA. Current State of Personalized Genitourinary Cancer Radiotherapy in the Era of Precision Medicine. *Front Oncol*. 2021 May 7;11:675311.
118. Ma YS, Yang XL, Xin R, Wu TM, Shi Y, Dan Zhang D, Wang HM, Wang PY, Liu JB, Fu D. The power and the promise of organoid models for cancer precision medicine with next-generation functional diagnostics and pharmaceutical exploitation. *Transl Oncol*. 2021 May 18;14(8):101126.
119. Wang Y, Zheng D. The importance of precision medicine in modern molecular oncology. *Clin Genet*. 2021 May 17.