

Advances of Plastic & Reconstructive Surgery

Chapter 6

The Keystone Perforator Island Flap: A 'Workhorse' Reconstructive Tool

Dr Mohammed Rahmaullah MBChB, MSc(BPRS), MSc (Med Ed)^{1,}; Dr Nawras Farhan MBChB, MSc (BPRS)¹*

¹*Division of Surgery and Interventional Science, University College London, Gower Street, London WC1E 6BT, UK.*

**Correspondence to: Mohammed Rahmaullah, Division of Surgery and Interventional Science, University College London, Gower Street, London WC1E 6BT, UK.*

Tel: 07404477149; Email: mohammed.rahmatullah.17@ucl.ac.uk

Abstract

The Keystone Perforator Island Flap is a versatile local flap for wound reconstruction that has emerged in the last 10-15 years. This review paper is dedicated to evaluating the concept of this reconstructive approach along with gathering its surgical applications and also to provide a comprehensive summary of the current modifications of this flap as well as the challenges faced in order to extend the applicability of this technique in clinical practice.

The PubMed Central, Embase, MEDLINE and Cochrane databases were researched from 2003 to December 2018, and consequently, 80 scientific articles were subjected to review.

In summary, the Keystone Perforator Island Flap is a well-vascularized, versatile and cost-effective flap that offers high success and low complication rates when patients are appropriately selected, and wounds are carefully evaluated.

Keywords: Keystone; KPIF; Island flap; Fasciocutaneous; Perforator; Reconstruction.

1. Introduction

Full-thickness skin defects are frequently reconstructed with the use of local/regional flaps, as they are superior to skin grafting and offer durable tissue cover while minimizing

donor-site morbidity. They are also favoured over free flaps in many clinical settings as they negate the need for advanced surgical equipment and expertise as well as being shorter and therefore less costly procedures [1].

The original concept of the Keystone Perforator Island Flap (KPIF) was proposed by Behan in 2003. It represents a “workhorse” reconstructive tool that is based on the principles of the angiosome theory and sympathectomy effect. This curvilinear trapezoidal-shaped flap comprises two conjoined V-Y island advancement flaps (end-to-side) and architecturally resembles the Roman arches’ keystones [2,3].

This versatile flap can be utilized as a main option, jointly with other flaps or as a lifeboat flap for reconstructing secondary defects [4]. Moreover, the perforators’ universal distribution within the body makes it a reliable reconstructive option from head to toe [3].

2. The Concept of the Keystone Perforator Island Flap

The concept of the KPIF is based on the fact that it is a perforator-based, fascia-lined, island advancement flap that combines the principles of the angiosomal territories, “vascularized segments incorporating axial and random pattern flaps” with the dermatomal roadmap guidance [5].

The vascular support of the KPIF is derived from random fasciocutaneous and musculocutaneous perforators that are linked to a subcutaneous vascular network (i.e. dual blood supply) [3]. However, flap vascularity is more dependent on the perforators’ flow than on subdermal plexus [6].

The design follows the dermatomal segments to enable the incorporation of the longitudinal neurovascular structures within the flap (i.e. retaining the perforators to maintain flap perfusion, cutaneous nerves to preserve flap’s sensation, and venous tributaries to avoid venostasis) [7].

3. Road-Mapping

The fact that the tri-laminar structure (i.e. skin, fat and fascia) that is supplied by fasciocutaneous, musculocutaneous and septocutaneous vessels irrespective of the flap pattern, led to the development of the fasciocutaneous island flap concept, which in turn, relies on both the vascular and neural anatomy [8]. A neurovascular guide for vascular perforator support is adopted to ensure the vascular integrity of the KPIF which can be better understood by explaining the angiosome and perforasome concepts [5].

In 1987, Taylor and Palmer conducted studies that elucidated the total blood supply of the skin and underlying deep tissues, and divided the body into angiosomes (i.e. three-

dimensional vascular territories), which are supplied by a source artery and drained by its accompanying vein. These studies also demonstrated the inter-angiosome linking through anastomotic arteries of a similar calibre or a reduced calibre retiform. Hence, the definition of angiosome has emerged as “a safe anatomic boundary of tissue that can be transferred separately or combined together on the underlying source vessels” [9].

On the other hand, the perforasome concept was described by Saint-Cyr et al. and is considered as an upgraded theory of the angiosome. The perforasome is the vascular territory of a single perforator which is also interconnected via direct and indirect linking vessels [10].

Understanding the distinctive distribution of the vascular territories for each individual perforasome has evolved the KPIF design since it accentuates the importance of including adjoining direct and indirect linking vessels while designing the flap to promote vascularity. Furthermore, this concept governs the decision of the flap axis orientation, as it has to match the axially of the dominant linking vessels, and this affects the directional blood flow. It also demonstrates the pivotal role of the direct inter-perforator linking vessels in case of harvesting single dominant perforator flaps [4]. There are 400 perforators distributed over diverse body regions referred to as “hot-spots” (**Figure 1**). Although, ultra-sound assisted identification of the dominant perforators is not mandatory, it is sometimes performed to ensure flap centring over these perforators, besides the inclusion of dominant linking vessels between them [4].

The clinical practice has affirmed that the axial vessels map and perforators distribution mimic the dermatomal zones which are often used as a key guide for flap designing [5], thus, enabling the preservation of the sensation and subcutaneous venous drainage [4, 8, 11].

3. Vascular Dynamics and the Effect of Islanding

The main vascular changes associated with flap islanding, termed the Immediate Vascular Augmentation Concept (IVAC) by Behan et al. [12], include the red dots sign and vascular flare. According to Behan’s observations, the island flap is relatively hyperaemic (vascular flare) and often bleeds where it is pierced by sutures during flap setting (red dots sign). The histological evidence reinforced these findings as it revealed an enlargement in both the arteriole and venule diameters immediately post-islanding compared to those of control specimens. Thereafter, the arteriole diameters were insignificantly decreased as compared with non-island flap specimens. This has the advantage of balancing the blood flow and preventing flap congestion (that may occur as a consequence of venular dilatation), thence, enhancing the flap survival [13, 14].

Our experience with this flap is in agreement with that of the IVAC by Behan et al, [12] where majority of flaps are initially hyperaemic but eventually settle over a number of days. Additionally, island flaps are more reliant on the perforators than on subdermal plexus in

their blood supply and since perforators provide the blood supply through a subfascial route, blood flow is not affected by the adrenergic vasoconstrictive state that is usually noted in local flaps after sympathetic nerves division [15]. The total blood flow in island flap is even more enhanced [6, 15].

In contrast to Behan's observation of temporary denervation of island flaps resulting in a pain-free postoperative period, this has not been our experience. This may be due to the preservation of longitudinal sensory nerves within the flaps when raising the KPIF.

4. Flap Design, Elevation and Defect Closure

The primary lesion is converted into an elliptical defect, which should be parallel to the corresponding angiosome and neurovascular structures. The flap is then sited along the maximal laxity border and contoured at right angles. Flap dimensions are reliant on the defect, as flap length is determined by the size of the ellipse with a flap to defect width of 1:1 ratio [2] (**Figure 2**). It is worth noting that Doppler ultra-sound localization and perforators' skeletonisation are not routinely performed [16].

Gentle blunt dissection around the flap is carried out to conserve the subcutaneous neurovascular structures and facilitate the centripetal mobilization of the adjacent tissues inwards and circumferentially. The avoidance of flap undermining will ensure the preservation of the vascularity, lymphatics and venous drainage (with the exception of type IV KPIF), as well as avoiding flap ballooning or pincushioning [2, 3, 17].

Wound closure is accomplished by direct flap alignment using stay sutures to facilitate wound edge approximation at the tension points. This is followed by a double V-Y advancement and apposition which will produce sufficient flap skin laxity in the central part and tension relaxation of the horizontal axis, hence, narrowing the primary and secondary defects [2,18].

Final wound closure is carried out in a single layer fashion using the Hemming suture (horizontal everting mattress method of suturing), followed by applying steri-strips to ensure appropriate epidermal alignment [2].

5. Modifications of the Flap Design

Since it was first practised, various modifications of the traditional KPIF design have been proposed (**Table 1**). Moncrieff et al. pointed out that there is no universal flap technique or modification to be applied in all different situations [19].

Clinical Applications in Various Anatomical Regions (Table 2)

6. Challenges with the use of the Keystone Perforator Island Flap

The KPIF provides significant advantages over other currently applied approaches. It ensures a safe and quick harvesting, more reconstructive freedom especially in the lower extremities and low donor-site morbidity. It also precludes the need for sophisticated microsurgical techniques or subsequent skin grafting [4,35,61]. Moreover, the augmented vascularity, pain-free postoperative period and benefits for elderly patients reduce the complications and hospital stay which in turn offer economic benefits [11].

The KPIF has excellent results from an aesthetic point of view since it employs loco-regional tissues with better colour and contour match, therefore, accentuating its ability to preserve function and aesthetic subunits while hiding the scars in the natural skin lines [19, 45,63].

The clinical evidence has demonstrated that the KPIF is a relatively simple and versatile approach with reliable healing in various circumstances [33]. However, there is no surgical technique without limitations. Since it is a local flap, the surrounding tissue status has to be considered especially in patients with previous surgeries. The feature of tensional closure should be borne in mind as it may disfigure the regional anatomy. Additionally, flap tip neurosis may necessitate skin grafting which leads to unfavourable aesthetic results [16,70].

The defect size and location are also crucial determinants of the flap design and application. Large defects are challenging especially in the lower extremities when severe paucity of tissue laxity is encountered or when bone support is required [53]. Reconstruction of the oncologic resection defects with the KPIF is tricky as it may be done in a conservative manner to guarantee soft tissue adequacy at the expense of achieving sufficient safe margins resulting in an inevitable recurrence. Radiation, on the other hand, affects skin flexibility making the reconstruction more difficult [70], nevertheless, it is not a contraindication for utilizing the KPIF [16]. In general, a judicious evaluation, careful patient selection and presurgical planning of a backup procedure are paramount to ensure successful KPIF implementation.

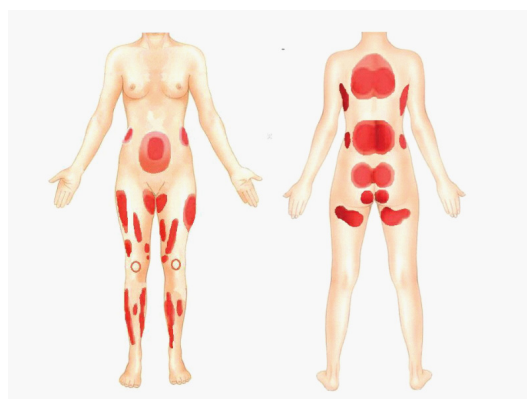


Figure 1: The dominant perforators “hot spots” in the body.

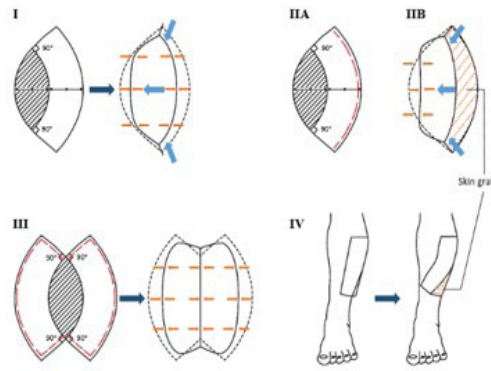


Figure 2: The traditional classification of the KPIF ²

- Type I: *Skin island flap* that involves only skin incision and is suitable for defects $\leq 2\text{cm}$ almost at any site.
- Type IIA: *Deep fascia division* along the outer flap curvature. Suitable for larger defects over muscle compartments.
- Type IIB: *Deep fascia division* along the outer flap curvature with secondary defect closure using *skin graft* (because of the limited adjacent tissue laxity). Suitable for defects of the lower 1/3 of the lower limb and forearm (i.e. areas of anatomical tightness).
- Type III: *Double keystone flaps* are created by opposing two identical KPIFs to obtain maximal adjacent tissue laxity. Suitable for larger defects (5-10cm) of the sacral region and calf.
- Type IV: *Rotational keystone flap* is created by subfascial flap undermining as far as 50%, followed by flap transposition and secondary defect closure using skin graft. Suitable for the reconstruction of joint contractures and bone coverage in open fractures.

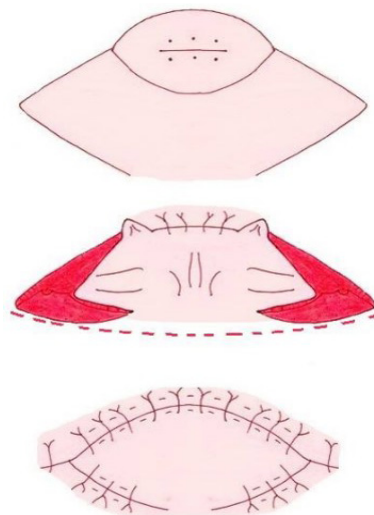


Figure 3: The SMU modification for oncologic cutaneous defect reconstruction. An intact skin bridge with deep fascia division along the outer flap curvature including under the tunneled skin-bridge.

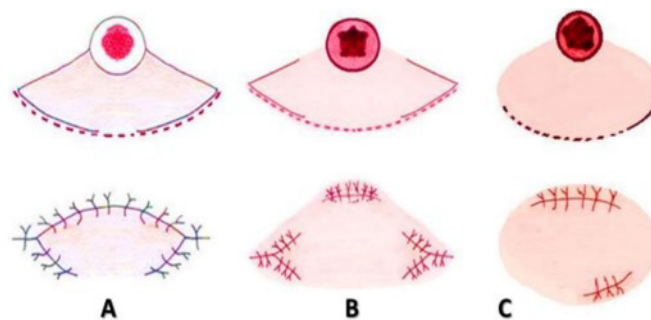


Figure 4: Other skin-bridge modifications proposed by Moncrieff et al. for oncologic cutaneous defect reconstruction. (A) Type I modified KPIF: an intact skin bridge with deep fascia division along the outer flap curvature including under the tunneled skin bridge. (B) Type II modified KPIF: additional skin bridges between the limbs of the V flaps and the elliptical defect. (C) Type III modified KPIF: the lateral V-Y flaps are omitted (in case of sufficient laxity).

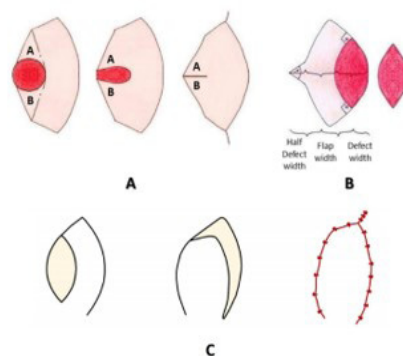


Figure 5: (A) Fish-mouth fashion, (B) Keystone plus flap and (C) Modified KPIF type E variant.

Table 1: Traditional KPIF design modifications.

Modification	Description	Aim(s) and Outcome(s)
1. Sydney Melanoma Unit (SMU) modification	<ul style="list-style-type: none"> It involves incomplete islanding of the KPIF by leaving an intact skin-bridge along the curvilinear line. The flap to defect width is of 1:1 ratio²⁰ (Figure 3). Other skin-bridge modifications are based on the same principles of the SMU modification, however, the flap to defect width is of 1-1.5:1 ratio and the defect is not converted into an ellipse¹⁹ (Figure 4). 	<ul style="list-style-type: none"> The skin-bridge enables exploiting the maximal adjacent tissue laxity and obtaining better tension redistribution. It also provides additional vascularity and secures the subcutaneous lymphatic vessels to avoid pincushioning^{19, 20}. These modifications are^{19, 20}: ✓ Reliable with an excellent aesthetic outcome and enhanced flap robustness. ✓ Applicable to any site of the leg without increasing complications (i.e. venous and lymphatic congestion). ✓ Suitable for various skin types and in cases of local and systemic comorbidities. ✓ Associated with a significant decrease in the major complications. The results of other studies that applied the same modifications confirmed the conclusions drawn by Moncrieff^{21, 22}. Shipkov and Mojallal theoretically pointed out the reliability of the modified flap²³.
	<ul style="list-style-type: none"> Alterations to the SMU modification involve maintaining an intact “subcutaneous bridge” while dividing the deep fascia beneath the subcutaneous pedicle along the whole flap circumference^{24, 25}. 	<ul style="list-style-type: none"> The aim is to preserve the vertical and horizontal vascularity²⁴. This will secure the vascular plexus of the horizontal adipose layer and support flap mobilization with minimal dissection²⁴.
2. Fish-Mouth Fashion ²⁶	<ul style="list-style-type: none"> The defect is circular and not converted to an ellipse to avoid sacrificing the normal tissue. The triangular skin flaps (A and B) are released suprafascially (Figure 5A). 	<ul style="list-style-type: none"> It facilitates primary defect closure in a fish-mouth fashion with significantly reduced tension.
3. Fortune cookie flap ²⁷⁻²⁹	<ul style="list-style-type: none"> The flap design is similar to the fish-mouth fashion modification, however, the flap is entirely elevated while conserving the central perforators (± an intact skin-bridge). 	<ul style="list-style-type: none"> This customized reconstructive option provides an excellent aesthetic outcome with minimal donor-site morbidity (e.g. after complete chest keloid resection).

4. The Omega Ω Variant	<ul style="list-style-type: none"> • Single or double arms of the KPIF are transposed up to 180° creating a horseshoe-shaped design. It comprises two types ³⁰: ✓ Type A: transposition of a single arm ✓ Type B: transposition of double arms 	<ul style="list-style-type: none"> • It enables defect coverage at reduced tension (i.e. pretibial defects) with enhanced flap advancement and normal tissue preservation ³¹.
5. Yin-Yang Flaps	<ul style="list-style-type: none"> • It incorporates a disparate pair of KPIFs, thus, the combined area of this design equals 4 V-Y flaps ³². 	<ul style="list-style-type: none"> • It is employed for reconstructing a single large soft tissue defect³². • It can be applied for perineal and gluteal defects for the sake of tension reduction ³³.
6. Free-Style Technique ³⁴	<ul style="list-style-type: none"> • It combines the free-style perforator flap concept and fish-mouth fashion modification. 	<ul style="list-style-type: none"> • It enables flap orientation irrespective of the dermatomes, enhances flap transposition and mobilization, and allows closure of the primary defect with reduced tension.
7. Modified KPIF Type E Variant ³⁵	<ul style="list-style-type: none"> • It is a modified type IIA flap that avoids the V incision over the skin deficiency region. • It employs only the proximal V-Y flap in either single or double KPIF, hence recruiting tissues from the region of sufficient laxity (Figure 5C). 	<ul style="list-style-type: none"> • It is useful for lower 1/3 defects of the leg, as this region is characterized by a horizontal soft tissue deficiency precluding the application of the distal V-Y design of the traditional KPIF.
8. Modified Type I KPIF for lateral nasal sidewall defects ³⁶	<ul style="list-style-type: none"> • The design of the modified KPIF adheres to the principles of the aesthetic nasal subunits. 	<ul style="list-style-type: none"> • It offers the advantages of reconstruction with a similar tissue and nasal contour restoration. • It can be given the priority in case of unfeasible primary closure.
9. Modified Type III KPIF for a large thoracolumbar MMC ³⁷	<ul style="list-style-type: none"> • It is a partial musculocutaneous flap that involves minimal subfascial flap undermining of the medial side of the middle 1/3 to facilitate flap mobilization and secure the musculocutaneous perforators. This is followed by submuscular latissimus dorsi dissection to secure the fasciocutaneous perforators. • Secondary defects are left to heal by secondary intention. 	<ul style="list-style-type: none"> • The modified KPIFs are robust and based on multiple perforators.
10. Extended design modifications ^{4, 38}	<ul style="list-style-type: none"> • Greater flap dimensions (flap to defect width ratio exceeds 1:1 up to 5:1) for inflamed, undermined or previously irradiated surrounding tissues. 	<ul style="list-style-type: none"> • This exploits the greater laxity areas and recruits tissues with sufficient vascularity and optimal perforator density.
	<ul style="list-style-type: none"> • Broad flap design that is centred over the hot spots and follows the maximal flow axially. 	<ul style="list-style-type: none"> • This will promote flap viability and vascularity by incorporating dominant perforator territories and dominant linking vessels. • This will also allow aggressive flap undermining remote from the dominant perforators, which is combined with almost circumferential or circumferential deep fascial division to enhance flap mobilization and orientation.
	<ul style="list-style-type: none"> • Designing asymmetrical KPIF limbs. 	<ul style="list-style-type: none"> • The aim is to bypass the joint creases and avoid exposing or damaging the underlying vital structures and lymph nodes.

	<ul style="list-style-type: none"> Minimizing deep dissection, undermining and overall flap tension. Besides, utilizing progressive tension sutures and confining scars to the aesthetic units. 	<ul style="list-style-type: none"> The aim is to minimize the more obvious scars that are expected with larger flaps.
11. KPIF Deepithelialization for dead space obliteration	<ul style="list-style-type: none"> For inguinal region defects: this involves deepithelialization of the KPIF excess tissue (\pm muscle flap transposition)^{4,38}. 	<ul style="list-style-type: none"> Deepithelialized KPIF is exploited for obliterating inguinal dead space and avoiding exposure of critical anatomic structures^{4,38}.
	<ul style="list-style-type: none"> Keystone-designed buried deepithelialized flap (KBD): is a modified KPIF with an intact skin bridge along the curvilinear line (flap width to dead space depth equals 1:1)³⁹. The flap is deepithelialized and the lateral ends are released creating a dermofat flap, which is then folded to obliterate the dead space³⁹. 	<ul style="list-style-type: none"> KBD flap efficiently obliterates a small to medium sized dead space³⁹.
12. Keystone Plus Flap ⁴⁰	<ul style="list-style-type: none"> It incorporates an additional V-Y advancement flap in the middle of the outer curvilinear line. The suggested height of the V flap is 50% of the defect width (Figure 5B). 	<ul style="list-style-type: none"> It achieves further flap skin laxity in the central part and tension relaxation of the horizontal axis. The results demonstrated a significant reduction in the delayed wound healing rate when compared to the traditional KPIF.
13. Croissant-like KPIF (CKPIF) ⁴¹	<ul style="list-style-type: none"> The flap edges encircle the defect without being contoured at right angles. Circumferential subdermal dissection of the flap is carried out, followed by submuscular and sub-SMAS dissection freeing them from the nasal periosteum. Consequently, the flap is indirectly transferred to cover the defect through a fibromuscular bridge (i.e. procerus muscle). 	<ul style="list-style-type: none"> This modification expands the KPIF application in the medial canthus neighbouring areas by offering additional flap length and overcomes the inner concavity-related problems.

Abbreviations: CKPIF: Croissant-like KPIF, KBD: Keystone-designed Buried Deepithelialized flap, KPIF: Keystone Perforator Island Flap, MMC: Myelomeningocele, SMAS: Superficial Muscular Aponeurotic System, SMU: Sydney Melanoma Unit

Table 2: The clinical applications of the KPIF in various anatomical regions.

Flap type(s)	No. of cases	Indication(s)	ADS:cm ² AFS:cm ² ADW:cm DSD:cm ³	Complications: No. of cases
Head				
<ul style="list-style-type: none"> Traditional KPIF: Parotid region⁴² 	63	Oncologic resection (previously irradiated tissue: 9 patients and postop adjuvant radiotherapy: 34 patients) Osteoradionecrosis	ADS: 36	Ectropion: 4 PFN: 4 WI: 1 WD: 1 Bleeding: 1
<ul style="list-style-type: none"> Traditional KPIF: Nose⁴³ 	31	Oncologic resection	ADW: 1.14	No complications
<ul style="list-style-type: none"> Traditional KPIF: Nose⁴⁴ 	30	Oncologic resection	ADW: 1.46	WD: 3
<ul style="list-style-type: none"> Modified type I KPIF: Lateral nasal sidewall defects³⁶ 	5	Oncologic resection	ADW: 1.9	No complications
<ul style="list-style-type: none"> Traditional KPIF: Lower eyelid⁴⁵ 	---	Oncologic resection Ectropion reconstruction	---	---
<ul style="list-style-type: none"> Traditional KPIF: Infra-auricular region and cheeks⁷ 	4	Oncologic resection (previously irradiated tissue)	---	No complications
<ul style="list-style-type: none"> Traditional KPIF: Medial canthus³ 	4	Oncologic resection	ADS: 3	---

• Traditional KPIF: Various regions ¹³	8	Oncologic resection	ADS: 45	Epiphora: 1 Odynophagia: 1 WD: 1
• Traditional KPIF: Postauricular region ⁴⁶	1	Oncologic resection	---	---
• Traditional or modified KPIF type A-E: Scalp ³⁵	1	---	---	---
• Traditional KPIF: Postauricular region ⁴⁷	10	Complete keloid resection	ADW: 2.25	Keloid recurrence: 1
• CKPIF: Medial canthus ± neighbour areas ⁴¹	15	Oncologic resection	ADS: 3.3 AFS: 5.4 ADW: 1.5	Transient epiphora: 4
Neck				
• Modified KPIF ³⁹	2	Lipoma resection	ADS: 12 AFS: 10	No complications
• Traditional or modified KPIF type A-E ³⁵	2	---	---	---
• Traditional KPIF ⁷	1	Oncologic resection (previously irradiated tissue)	---	No complications
• Traditional KPIF ⁴⁰ • Modified KPIF ⁴⁰	1 4	Oncologic resection	---	No complications
Head and neck				
Upper Extremities				
• Traditional KPIF ⁴⁸	3	Oncologic resection	---	No complications
• Modified KPIF ⁴⁹	1	Oncologic resection	ADS: 4.5	No complications
• Traditional or modified KPIF type A-E ³⁵	3	---	---	---
• Traditional KPIF ⁵⁰	4	Oncologic resection (mainly)	ADS: 179.2±41.3	Cellulitis: 1
• Traditional KPIF ⁵¹	1	Oncologic resection	---	---
Trunk				
• Traditional KPIF ³	2	---	ADS: 48	---
• Traditional KPIF ⁵²	9	Trauma (military injuries)	AFS: 99	No complications
• Modified KPIF ³⁹	10	Epidermal cyst and lipoma resection	ADS: 12 AFS: 9.3	No complications
• Traditional KPIF ⁵³	3	Closure of lumbosacral MMCs	ADS: 10	No complications
• Modified Type III KPIF ³⁷	1	Closure of large thoracolumbar MMCs	ADS: 76	No complications
• Traditional KPIF ⁵⁴ • Trilateral KPIF (Crock) ⁵⁴ • Omega Ω Variant ⁵⁴	5	Closure of lumbosacral MMCs	ADS: 33	No complications
• Modified Type III KPIF ⁵⁵	6	Closure of MMCs	ADS: 8.2 ADW: 2.4	WI: 2
• Traditional KPIF ⁵⁶	20	Oncologic resection	---	WD: 1
• Modified KPIF ⁵⁷	1	Oncologic resection	ADS: 500	---
• Traditional KPIF ³⁵ • Modified KPIF type A-E ³⁵	8	Either: Trauma Elective excision Inflammatory wounds excision Wound dehiscence	---	WD: 1
• Modified KPIF ³⁹	9	Fat necrosis	ADS: 26.4 AFS: 21.3	No complications
• Traditional KPIF ⁴⁰ • Modified KPIF ⁴⁰	3 2	Oncologic resection	---	• DWH: 3 • No complications

• Traditional KPIF ⁵⁰	9	Oncologic resection	ADS: 389.6±169.5	WD: 2 PFN: 1
• Fortune cookie flap ²⁷	3	Complete resection of chest keloids	ADS: 21 AFS: 43.9 ADW: 4.2	No complications
Lower Extremities				
• Traditional KPIF ⁷	3	Oncologic resection (previously irradiated tissue)	ADS: 188.6	WD: 1
• Traditional KPIF type I, IIA, III, IV ³	---	Oncologic resection Trauma	---	No complications
• Traditional KPIF ²⁰ • SMU modification ²⁰	176	Oncologic resection	ADW: 3	PFN: 1 TFN: 1 WI: 2 DVT: 1
• Traditional KPIF Type IV ⁵⁸	1	Chronic wound with lymphedema	---	No complications
• Fish-Mouth Fashion ²⁶	1	Oncologic resection	ADW: 3	No complications
• Yin-Yang flap ³²	1	Recurrent gluteal pilonidal sinuses	ADS: 150	No complications
• Traditional KPIF ⁵⁰	14	Oncologic resection (mainly)	ADS: 107.3±32.1	TFN: 1 WD: 3 Cellulitis: 2
• Traditional KPIF Type I ⁵⁹	1	Oncologic resection	ADS: 5.6	No complications
• Traditional KPIF ⁶⁰	1	Oncologic resection	ADW: 2.5	---
• QKIF for RIL ⁶¹	20	Oncologic resection (previously irradiated tissue: 14 patients)	ADS: 150	WD: 4 WI: 6 Seromas: 7 Haematomas: 2 Lymphedema: 6
• Traditional KPIF ³⁵ • Modified KPIF type A-E ³⁵	28	Trauma Elective excision Inflammatory wounds excision WD	---	PFN: 1 WD: 1
• Traditional KPIF ⁶² • Modified KPIF ⁶²	22	Oncologic resection	ADW: 3.1	No PFN or TFN
• Traditional KPIF Type I ⁴⁹	4	Trauma (Gustilo II and III open fractures of the leg)	ADS: 36.9	No complications
• Traditional KPIF ²² • Moncrieff's skin-bridge modifications ²²	22	Oncologic resection (mainly)	---	WD: 1 Cellulitis: 2 DWH: 3
• Traditional KPIF ⁶³	14	Trauma Oncologic resection Abscess debridement	ADS: 189	---
• Moncrieff's skin-bridge modifications ²¹	5	Oncologic resection (after Mohs micrographic surgery)	ADS: 2.88	No complications
• Traditional KPIF ⁵²	19	Trauma (military injuries)	AFS: 107.5	PFN: 1 WD: 1
• Traditional KPIF ⁴⁰ • Keystone plus flap ⁴⁰	6	Oncologic resection Trauma	---	DWH: 2
• KBD Flap ³⁹	1	Lipoma resection	DSD: 7.5 AFS: 4.5	No complications
• Traditional KPIF ⁶⁴	2	Oncologic resection	ADS: 12.62	No complications
• Traditional KPIF (Type IIA and IV) ³¹ • Omega Ω Variant (type IIA and IIB) ³¹	9	Trauma Burn (Patients with comorbidities)	ADS: 27 AFS: 107.5	No complications

• Traditional KPIF with minor alterations (Type IIA, III and IV) ¹	25	Oncologic resection Trauma Miscellaneous causes	---	PFN: 1 WD: 3 FS: 6 Numbness: 1 DVT: 1 WI: 5 Hypertrophic scarring: 1 Contour deformity: 1
• Modified Type IIA KPIF ⁶⁵	6	ALT flap donor-site closure	ADS: 96.8 AFS: 167.5 ADW: 7.8	DWH: 1
Perineum				
• Modified Type III KPIF: External genitalia ³³	1	Giant Condyloma Acuminata excision	ADS: 110	No complications
• Traditional KPIF: Vulva ⁶⁶	1	Oncologic resection (previously irradiated tissue)	ADS: 12	---
• Traditional KPIF: Perianal region ⁶⁷	1	Oncologic resection	ADS: 21.76	No complications
• Traditional KPIF • Keystone Plus Flap ⁴⁰	10	Oncologic resection Trauma	---	DWH: 3
• Modified Type III KPIF: Pubic area ⁶⁸	1	Complete keloid resection	ADS: 240	No complications
Miscellaneous regions				
• Traditional KPIF ⁶⁹	59	Oncologic resection	---	FS: 16
• Fortune cookie flap ²⁹	13	Sacral, ischial and trochanteric pressure ulcers reconstruction	ADS: 50.1 AFS: 100.4 ADW: 6.5	Cellulitis: 1 WD: 1

Abbreviations: “---” indicates no given or nonspecific information. ADS: Average defect size; ADW: Average defect width; AFS: Average flap size; CKPIF: Croissant-like KPIF; DSD: Dead space dimensions; DVT: Deep venous thrombosis; DWH: Delayed wound healing; FS: Flap separation; KBD: Keystone-designed buried de-epithelialized flap; KPIF: Keystone perforator island flap; MI: Myocardial infarction; MMCs: Myelomeningoceles; PFN: Partial flap necrosis, Postop: Postoperative; QKIF: Quadriceps keystone island flap; SMU: Sydney melanoma unit; TFN: Total flap necrosis; WD: Wound dehiscence; WI: Wound infection.

7. Discussion

The exceptional design of the KPIF recruits tissue laxity by swapping a primary defect with insufficient adjacent tissue laxity for a secondary defect with adequate nearby tissue laxity [71]. This will redistribute the tension and laxity over the entire flap area [38] and exploit the viscoelastic properties within the flap and around the primary and secondary defects [59].

Furthermore, it enables generating sufficient tissue laxity since it comprises two conjoined V-Y flaps which are parallel to the elliptical defect instead of being perpendicular. Additionally, flap alignment in the longitudinal axis of the limbs and the conservation of the subcutaneous lymphatics minimize the possibility of developing distal lymphedema [19, 20].

This conjoined design has certain features of the bipedicle flap, as flap advancement permits the redistribution of closure tension over two linear closures (which are in a parallel alignment) and the intervening flap [60]. However, it offers many advantages that make it more favourable. The secondary defect is smaller than the primary defect and may be closed without skin grafting [2]. In addition, the released longitudinal tension and homogenous tension redistribution preserve

sufficient vascularity of the central flap portion [2,17]. It also incorporates larger perforator density, therefore, allowing larger defects closure [12]. Moreover, the conservation of the skin paddle's sensation and limited flap dissection, which enables the use of other fasciocutaneous flaps in case of failure, are other crucial advantages [49].

Although the major surgical rule of tension-free closure to avoid ischemic necrosis applies, the lateral tension exerted on the flap is perpendicular to the muscular perforators and does not lead to a significant flow impairment [60]. In addition, significant tension may exist at initial flap suturing, yet it will be diminished by the subsequent flap relaxation over time and the use of progressive tension sutures [50]. Behan further suggested the utilization of central tension sutures which follow the block and tackle basis to distribute tension over four strands instead of two [72].

Moreover, minor contour irregularities are commonly observed postoperatively. These resolve quickly by the effect of tissue creep and stress relaxation [20] and are usually lower than that of the propeller or other perforator flaps [4].

It is worth noting the opposing view endorsed in light of Douglas and Morris' study, which demonstrated that there is no significant reduction in wound tension after KPIF advancement and questioned the rationale behind adopting such a flap technique [73]. Douglas et al. even questioned whether "true" advancement occurs or it is just an effect of increasing transverse stretch as a result of the longitudinal release of the skin [74].

Shayan and Behan responded to those queries by reiterating the main principles of the KPIF in redistributing laxity as well as enhancing mobility and tissue stretch. They highlighted the scientific flaws in the former study, such as the small sample size, neglect of essential patient/defect parameters and lack of statistical analysis [71]. This study was also critiqued by Findlay and Kleid who emphasized the effectiveness of the KPIF for adequate defects closure all over the body and further criticised their inappropriate extrapolation from such a poor sample size (n=1, type I KPIF) and the absence of a control group [75]. A scientific debate was rekindled by Douglas et al. who pointed out the lack of the objective determination of wound closure since stepwise suturing techniques may surprisingly close the defect primarily [76]. With his colleagues, Douglas re-tested the biomechanical merits of the KPIF using a larger sample size, control group and statistical analysis [77]. Nevertheless, an essential question is whether the results from cadaveric specimens reflect what is actually happening in the clinical practice?! Ultimately, deriving a concrete conclusion on surgical approaches is challenging and cannot be based on sporadic uncontrolled case reports without authentic randomized controlled trials because of the high subjectivity and surgeon-related variances as well as the absence of a single definition for the outcome and effectiveness measurement.

The KPIF offers an additional safety in case of local or systemic comorbidities because

complete skin islanding improves its vascularity by a sympathectomy effect, as “island flaps are safer than peninsular flaps”. On the other hand, retaining a skin-bridge suppresses the vascular dynamics and restricts flap mobilization [5, 35, 78, 79].

A systematic review of 282 KPIFs applied for lower limb reconstruction showed that the KPIF was employed for defects which were caused by oncologic resection (88.98%), trauma (9.32%), wound infection (0.85%) and postoperative complications (0.85%). It also revealed that the associated complications were wound dehiscence (5.7%), wound infection (1.8%), partial necrosis (1.1%) and total necrosis (0.7%) [80].

In addition, the KPIF is designed posterior to the defects in the lower leg to utilize the posterior compartment skin laxity for secondary defect closure [2, 59]. Further, in case of extensive groin defects after oncologic resection and previously irradiated tissues (i.e. radical inguinal lymphadenectomy), Behan suggested the use of Quadriceps Keystone Island Flap (QKIF), which is based on L1-L2 dermatomal segment and conserves the femoral nerve’s cutaneous branches to ensure a conjoint vascular supply. The convex margin of the TFL is divided along its whole length to facilitate flap transposition superomedially. Although primary closure of the secondary defect is often feasible, skin grafting can be used when severe tension exists [7, 61].

A recent study has considered traumatic soft tissue loss as a relative contraindication to the KPIF with special care while managing lower extremity wounds [1]. This is attributed to the involvement of the adjacent tissues within the zone of injury and concomitant wound infection. Therefore, preoperative wound bed preparation and optimization are critical in such cases [31].

On the other hand, the KPIF is a valuable reconstructive option in case of military trauma with extensive and deep soft tissue defects (i.e. mine-shrapnel or gunshot defects). It is a single-stage operation that offers the fastest definitive reconstruction with enhanced functional and aesthetic outcomes [52].

Regarding periarticular defects, they represent a real challenge because of joint mobility and regional tension alterations. The surrounding tissues are continuously under stretching, compressive and twisting forces. Besides, the probability of neurovascular exposure in the deep wounds of the elbow and knee joints. The KPIF offers a durable cutaneous coverage with reduced donor-site morbidity while evading contour deformities and joint contracture [64].

8. Conclusion

The KPIF is an effective reconstructive option for wound reconstruction with low complication rates, donor-site morbidity, hospital stay and hence overall economic burden. It

can be considered as a good option for reconstructing full-thickness skin defects as it is simple, durable and obviates the need for more complicated surgical procedures.

The KPIFs enhanced vascularity, sensory preservation and reconstructive freedom, account for the high satisfaction rate among surgeons familiar with the use of the flap. This outweighs some of the reconstructive challenges experienced with its use in different anatomical regions especially in sites of anatomical tightness. As with any surgical technique, the KPIF can occasionally prove challenging to surgeons in some respects such as insufficient surrounding tissue laxity resulting in excessive tension associated with wound closure. Large defects may require the use of design modifications to counteract these obstacles. We believe that with careful preoperative planning and meticulous patient and defect evaluation, wound reconstruction with the KPIF can be considered as a reliable and durable reconstructive option.

9. Acknowledgement

We would like to acknowledge Mrs Haneen Farhan for her kind help in drawing the illustrative figures.

10. Conflict of interest statement: none

11. Funding: none

12. References

1. Lanni MA, Van Kouwenberg E, Yan A, Rezak KM, Patel A. Applying the Keystone Design Perforator Island Flap Concept in a Variety of Anatomic Locations: A Review of 60 Consecutive Cases by a Single Surgeon. *Ann Plast Surg.* 2017;79(1):60-7.
2. Behan FC. The Keystone Design Perforator Island Flap in reconstructive surgery. *ANZ J Surg.* 2003;73(3):112-20.
3. Pelissier P, Gardet H, Pinsolle V, Santoul M, Behan FC. The keystone design perforator island flap. Part II: clinical applications. *J Plast Reconstr Aesthet Surg.* 2007;60(8):888-91.
4. Mohan AT, Rammos CK, Akhavan AA, Martinez J, Wu PS, Moran SL, et al. Evolving Concepts of Keystone Perforator Island Flaps (KPIF): Principles of Perforator Anatomy, Design Modifications, and Extended Clinical Applications. *Plast Reconstr Surg.* 2016;137(6):1909-20.
5. Behan F, Lo C. Principles and misconceptions regarding the keystone island flap. *Ann Surg Oncol.* 2009;16(6):1722-3.
6. Behan FC, Sizeland A. Reiteration of core principles of the Keystone island flap. *ANZ J Surg.* 2006;76(12):1127-9.
7. Behan F, Sizeland A, Porcedu S, Somia N, Wilson J. Keystone island flap: an alternative reconstructive option to free flaps in irradiated tissue. *ANZ J Surg.* 2006;76(5):407-13.
8. Behan FC. The fasciocutaneous island flap: an extension of the angiotome concept. *Aust N Z J Surg.* 1992;62(11):874-86.
9. Taylor GI, Palmer JH. The vascular territories (angiosomes) of the body: experimental study and clinical applications. *Br J Plast Surg.* 1987;40(2):113-41.

10. Saint-Cyr M, Wong C, Schaverien M, Mojallal A, Rohrich RJ. The perforasome theory: vascular anatomy and clinical implications. *Plast Reconstr Surg.* 2009;124(5):1529-44.
11. Behan FC, Lo CH. Vascular dynamics of the keystone island flap: ongoing observations similar to sympathectomy. *ANZ J Surg.* 2009;79(11):861.
12. Behan FC, Rozen WM, Kapila S, Ng SK. Two for the price of one: a keystone design equals two conjoined V-Y flaps. *ANZ J Surg.* 2011;81(6):405-6.
13. Behan F, Sizeland A, Gilmour F, Hui A, Seel M, Lo CH. Use of the keystone island flap for advanced head and neck cancer in the elderly--a principle of amelioration. *J Plast Reconstr Aesthet Surg.* 2010;63(5):739-45.
14. Lo CH, Nottle T, Mills J. Keystone Island Flap: Effects of Islanding on Vascularity. *Plastic and reconstructive surgery Global open.* 2016;4(2):e617.
15. Behan FC, Lo CH, Sizeland A. The interpretation of vascular changes observed in keystone island flaps: a hypothesis. *J Plast Reconstr Aesthet Surg.* 2010;63(2):e215-6.
16. Behan FC, Lo CH, Findlay M. Anatomical basis for the keystone island flap in the upper thigh. *Plast Reconstr Surg.* 2010;125(1):421-3.
17. Jackson IT. The keystone design perforator island flap in reconstructive surgery. *ANZ J Surg.* 2003;73(5):261.
18. Pelissier P, Santoul M, Pinsolle V, Casoli V, Behan F. The keystone design perforator island flap. Part I: anatomic study. *J Plast Reconstr Aesthet Surg.* 2007;60(8):883-7.
19. Moncrieff MD, Thompson JF, Stretch JR. Extended experience and modifications in the design and concepts of the keystone design island flap. *J Plast Reconstr Aesthet Surg.* 2010;63(8):1359-63.
20. Moncrieff MD, Bowen F, Thompson JF, Saw RP, Shannon KF, Spillane AJ, et al. Keystone flap reconstruction of primary melanoma excision defects of the leg-the end of the skin graft? *Ann Surg Oncol.* 2008;15(10):2867-73.
21. Magliano J, Falco S, Agorio C, Bazzano C. Modified keystone flap for extremity defects after Mohs surgery. *Int J Dermatol.* 2016;55(12):1391-5.
22. Stone JP, Webb C, McKinnon JG, Dawes JC, McKenzie CD, Temple-Oberle CF. Avoiding Skin Grafts: The Keystone Flap in Cutaneous Defects. *Plast Reconstr Surg.* 2015;136(2):404-8.
23. Shipkov CD, Mojallal A. The keystone island and pedicle flap: a handy local flap for soft tissue reconstruction. *Ann Surg Oncol.* 2008;15(12):3625.
24. Pikturnaite J, Mashhadi S. Enhanced robustness and mobility of the keystone flap. *Dermatol Surg.* 2014;40(9):1054-6.
25. Syed ZU, Donnelly HB. Novel Fasciotomy Technique for the Keystone Flap. *Dermatol Surg.* 2018;44(10):1345-7.
26. Rao K, Raine C. Re: Keystone design flap: a tension-reducing modification. *ANZ J Surg.* 2010;80(7-8):574.
27. Park TH, Lee JW, Kim CW. The fortune cookie flap for aesthetic reconstruction after chest keloid resection: a small case series. *J Cardiothorac Surg.* 2018;13(1):31.
28. Lee JW, Kim CW, Park TH. Customized reconstruction with modified keystone flaps. *J Dermatol.* 2018;45(7):844-9.
29. Byun IH, Kim CW, Park TH. The Modified Keystone Flap for Pressure Ulcers: A Novel Modification of the Keystone Flap With Rotation and Advancement. *Ann Plast Surg.* 2018.
30. Behan FC, Rozen WM, Lo CH, Findlay M. The omega - Omega - variant designs (types A and B) of the keystone perforator island flap. *ANZ J Surg.* 2011;81(9):650-2.

31. Yoon CS, Kim SI, Kim H, Kim KN. Keystone-Designed Perforator Island Flaps for the Coverage of Traumatic Pretibial Defects in Patients With Comorbidities. *Int J Low Extrem Wounds*. 2017;16(4):302-9.
32. Behan FC, Rozen WM, Tan S. Yin-Yang flaps: the mathematics of two keystone island flaps for reconstructing increasingly large defects. *ANZ J Surg*. 2011;81(7-8):574-5.
33. Eriad Yunir P, Mochtar CA, Hamid AR, Sukasah CL, Umbas R. Surgical Management of Giant Genital Condyloma Acuminata by Using Double Keystone Flaps. *Case reports in urology*. 2016;2016:4347821.
34. Monarca C, Rizzo MI, Sanese G. Keystone flap: freestyle technique to enhance the mobility of the flap [corrected]. *ANZ J Surg*. 2012;82(12):950-1.
35. Bhat SP. Keystone flaps in coloured skin: Flap technology for the masses? *Indian J Plast Surg*. 2013;46(1):36-47.
36. Chaput B, de Bonnecaze G, Lopez R, Benjamin V, Garrido I, Grolleau JL. Modified keystone island flap design for lateral nasal defect: aesthetic subunit consideration. *Plastic and reconstructive surgery Global open*. 2014;2(9):e213.
37. Jamjoom H, Alnoman H, Almadani Y. Closure of a Large Thoracolumbar Myelomeningocele Using a Modified Bilateral Keystone Flap. *Plastic and reconstructive surgery Global open*. 2016;4(12):e1114.
38. Mohan AT, Sur YJ, Zhu L, Morsy M, Wu PS, Moran SL, et al. The Concepts of Propeller, Perforator, Keystone, and Other Local Flaps and Their Role in the Evolution of Reconstruction. *Plast Reconstr Surg*. 2016;138(4):710e-29e.
39. Kim H, Ryu WC, Yoon CS, Kim KN. Keystone-designed buried de-epithelialized flap: A novel technique for obliterating small to moderately sized dead spaces. *Medicine (Baltimore)*. 2017;96(21):e7008.
40. Rubino C, Faenza M, Di Pace B, Campitiello N, Brongo S, Zingone G. A new keystone flap “Plus” design: Case series and analysis of follow-up. *J Plast Reconstr Aesthet Surg*. 2017;70(7):976-9.
41. Kostopoulos E, Agiannidis C, Konofaos P, Kotsakis I, Hatzigianni P, Georgopoulos G, et al. Changing the Paradigm in Medial Canthal Reconstruction: The Bridge Principle and the Croissant-Like Keystone Island Perforator Flap as An Alternative for Medium Size Soft Tissue Defects in Internal Canthus Reconstruction. *J Craniofac Surg*. 2018;29(5):e455-e9.
42. Behan FC, Lo CH, Sizeland A, Pham T, Findlay M. Keystone island flap reconstruction of parotid defects. *Plast Reconstr Surg*. 2012;130(1):36e-41e.
43. Kostopoulos E, Agiannidis C, Konofaos P, Kotsakis I, Champsas G, Frangoulis M, et al. Keystone Perforator Island Flap as an Alternative Reconstructive Option for Partial Thickness Alar Defects Up to 1.5 Centimeters. *J Craniofac Surg*. 2016;27(5):1256-60.
44. Kostopoulos E, Casoli V, Agiannidis C, Konofaos P, Drimouras G, Dounavis A, et al. The Keystone Perforator Island Flap in Nasal Reconstruction: An Alternative Reconstructive Option for Soft Tissue Defects up to 2 cm. *J Craniofac Surg*. 2015;26(4):1374-7.
45. Loh IW, Rozen WM, Behan FC, Crock J. Eyelid reconstruction: expanding the applications of the keystone perforator island flap concept. *ANZ J Surg*. 2012;82(10):763-4.
46. Corrias F, Maruccia M, Monarca C, Sanese G, Scuderi N. Reconstruction of posterior auricular ear surface defects: “Ear Keystone graft”. *J Plast Reconstr Aesthet Surg*. 2013;66(4):581-3.
47. Park TH, Kim CW, Chang CH. Aesthetic reconstruction of retroauricular keloid: Creating a keystone flap from the mastoid-helix area. *J Dermatol*. 2018;45(5):584-6.
48. Albrecht ML, Wetzig T. Keystone flap for covering large soft tissue defects of the dorsum of the hand. *Journal der Deutschen Dermatologischen Gesellschaft = Journal of the German Society of Dermatology : JDDG*. 2017;15(12):1262-4.

49. Chaput B, Herlin C, Espie A, Meresse T, Grolleau JL, Garrido I. The keystone flap alternative in posttraumatic lower-extremity reconstruction. *J Plast Reconstr Aesthet Surg.* 2014;67(1):130-2.
50. Khouri JS, Egeland BM, Daily SD, Harake MS, Kwon S, Neligan PC, et al. The keystone island flap: use in large defects of the trunk and extremities in soft-tissue reconstruction. *Plast Reconstr Surg.* 2011;127(3):1212-21.
51. Hessam S, Sand M, Bechara FG. The keystone flap: expanding the dermatologic surgeon's armamentarium. *Journal der Deutschen Dermatologischen Gesellschaft = Journal of the German Society of Dermatology : JDDG.* 2015;13(1):70-2.
52. Sliesarenko SV, Badiul PO, Sliesarenko KS. Extensive Mine-Shrapnel and Gunshot Wound Closure Using Keystone Island Perforator Flaps. *Plastic and reconstructive surgery Global open.* 2016;4(5):e723.
53. Gutman MJ, Goldschlager T, Fahardieh RD, Ying D, Xenos C, Danks RA. Keystone design perforator island flap for closure of myelomeningocele. *Childs Nerv Syst.* 2011;27(9):1459-63.
54. Park HS, Morrison E, Lo C, Leong J. An Application of Keystone Perforator Island Flap for Closure of Lumbosacral Myelomeningocele Defects. *Ann Plast Surg.* 2016;77(3):332-6.
55. Donaldson C, Murday HKM, Gutman MJ, Maher R, Goldschlager T, Xenos C, et al. Long-term follow-up for keystone design perforator island flap for closure of myelomeningocele. *Childs Nerv Syst.* 2017.
56. Azizeddin A, Choong PFM, Grinsell D. Reconstructive options for large back free flap donor sites. *ANZ J Surg.* 2017.
57. Sinha S, Yip MJ, Gill S, Pohl MJ, Donahoe SR. A giant fungating metastatic basal cell carcinoma of the back and novel reconstruction using two large keystone design island perforator flaps. *J Plast Reconstr Aesthet Surg.* 2013;66(7):1015-8.
58. Behan FC, Lo CH, Shayan R, Findlay M. The keystone technique for resolution of chronic lower limb wound with lymphoedema. *J Plast Reconstr Aesthet Surg.* 2009;62(5):701-2.
59. Hu M, Bordeaux JS. The keystone flap for lower extremity defects. *Dermatol Surg.* 2012;38(3):490-3.
60. Martinez JC, Cook JL, Otley C. The keystone fasciocutaneous flap in the reconstruction of lower extremity wounds. *Dermatol Surg.* 2012;38(3):484-9.
61. Behan FC, Paddle A, Rozen WM, Ye X, Speakman D, Findlay MW, et al. Quadriceps keystone island flap for radical inguinal lymphadenectomy: a reliable locoregional island flap for large groin defects. *ANZ J Surg.* 2013;83(12):942-7.
62. Mohan A, Ramman S, Mandal A. The Keystone Island Flap: Our Experience in Skin Oncological Reconstruction. *Plast Reconstr Surg.* 2014;134(4S-1):50.
63. Rao AL, Janna RK. Keystone flap: versatile flap for reconstruction of limb defects. *Journal of clinical and diagnostic research : JCDR.* 2015;9(3):Pc05-7.
64. Jovic TH, Jessop ZM, Slade R, Dobbs T, Whitaker IS. The Use of Keystone Flaps in Periarticular Wound Closure: A Case Series. *Frontiers in surgery.* 2017;4:68.
65. Turin SY, Spitz JA, Alexander K, Ellis MF. Decreasing ALT donor site morbidity with the keystone flap. *Microsurgery.* 2018;38(6):621-6.
66. Behan FC, Rozen WM, Azer S, Grant P. 'Perineal keystone design perforator island flap' for perineal and vulval reconstruction. *ANZ J Surg.* 2012;82(5):381-2.
67. Lohana P, Creagh T. Reconstruction for basal cell carcinoma in an anatomical region where the sun does not shine: an attractive option! *Ann R Coll Surg Engl.* 2012;94(2):e65-7.

68. Park TH. Aesthetic reconstruction of extensive pubic keloids using bilateral modified keystone flaps. *J Dermatol*. 2018.
69. Taleb M, Choi L, Kim S. Safety and efficacy of the keystone and rhomboid flaps for immediate reconstruction after wide local excision of non-head and neck melanomas. *World J Surg Oncol*. 2016;14(1):269.
70. Chen HC. Precautions in using keystone flap. *J Plast Reconstr Aesthet Surg*. 2010;63(4):720.
71. Shayan R, Behan FC. Re: the “keystone concept”: time for some science. *ANZ J Surg*. 2013;83(7-8):499-500.
72. Behan FC, Lo CH, Wong P, Wong DS. Block and tackle tension sutures in keystone island flaps. *J Plast Reconstr Aesthet Surg*. 2009;62(5):702-4.
73. Douglas C, Morris O. The ‘keystone concept’: time for some science. *ANZ J Surg*. 2013;83(7-8):498-9.
74. Douglas CD, Low NC, Seitz MJ. The keystone flap: not an advance, just a stretch. *Ann Surg Oncol*. 2013;20(3):973-80.
75. Findlay MW, Kleid S. The keystone concept: a time for good science. *ANZ J Surg*. 2014;84(3):194-5.
76. Douglas C, Morris O, Donovan L. The keystone flap: is your ‘unclosable’ wound really unclosable? *ANZ J Surg*. 2014;84(6):496-7.
77. Donovan LC, Douglas CD, Van Helden D. Wound tension and ‘closability’ with keystone flaps, V-Y flaps and primary closure: a study in fresh-frozen cadavers. *ANZ J Surg*. 2017.
78. Behan FC, Lo CH, Shayan R. Perforator territory of the keystone flap--use of the dermatomal roadmap. *J Plast Reconstr Aesthet Surg*. 2009;62(4):551-3.
79. Milton SH. Experimental studies on island flaps. 1. The surviving length. *Plast Reconstr Surg*. 1971;48(6):574-8.
80. Huang J, Yu N, Long X, Wang X. A systematic review of the keystone design perforator island flap in lower extremity defects. *Medicine (Baltimore)*. 2017;96(21):e6842.