

Advances of Plastic & Reconstructive Surgery

Chapter 5

Pressure Injuries Fundamentals

Dr Mohammed Rahmatulla MBChB, MSc(BPRS), MSc (Med Ed)^{1}; Dr Nawras Farhan MBChB, MSc(BPRS)¹*

¹*Division of Surgery and Interventional Science, University College London, Gower Street, London WC1E 6BT, UK.*

**Correspondence to: Mohammed Rahmatulla, Division of Surgery and Interventional Science, University College London, Gower Street, London WC1E 6BT, UK.*

Tel: 07404477149; Email: mohammed.rahmatullah.17@ucl.ac.uk

Abbreviations: AD: Autonomic Dysreflexia; ALT: Anterolateral Thigh; ASA: American Society of Anesthesiologists; BMI: Body Mass Index; COX-2: cyclo-oxygenase 2; DVT: Deep Venous Thrombosis; EPUAP: European Pressure Ulcer Advisory Panel; HbA1c: Haemoglobin A1c; HO: Heterotopic Ossification; IGAP: Inferior Gluteal Artery Perforator; MDT: Multidisciplinary Team; MMP: matrix metalloproteinases; NPUAP: National Pressure Ulcer Advisory Panel; PE: Pulmonary Embolism; PI: Pressure Injury; SCC: Squamous Cell Carcinoma; SCI: Spinal Cord Injury; SGAP: Superior Gluteal Artery Perforator; TFL: Tensor Fascia Lata; TFL-PBIF: Tensor Fascia Lata - Perforator-Based Island Flap.

1. Introduction

A pressure injury (PI) is “a localized damage to the skin and/or underlying soft tissue usually over a bony prominence or related to a medical or other device. The injury can present as intact skin or an open ulcer and may be painful. The injury occurs as a result of intense and/or prolonged pressure or pressure in combination with shear. The tolerance of soft tissue for pressure and shear may also be affected by microclimate, nutrition, perfusion, co-morbidities and condition of the soft tissue” [62].

The most widely accepted PI staging system is the National Pressure Ulcer Advisory Panel (NPUAP) classification. see Table (1). The term “pressure injury” replaces the “Pressure ulcer” term to accurately describe pressure injuries for both intact and ulcerated skin. PI is also known as pressure sore, pressure ulcer, bedsore or decubitus ulcer [1].

Table 1: stages of Pressure Injuries (NPUAP).

Stages	Description
Stage I	Non-blanchable erythema of intact skin, which may appear differently in darkly pigmented skin.
Stage II	Partial-thickness loss of skin with exposed dermis. The wound bed is viable, pink or red, moist, and may also present as an intact or ruptured serum-filled blister.
Stage III	Full-thickness loss of skin, in which adipose (fat) is visible in the ulcer and granulation tissue and epibole (rolled wound edges) are often present. Slough and/or eschar may be visible.
Stage IV	Full-thickness skin and tissue loss with exposed or directly palpable fascia, muscle, tendon, ligament, cartilage or bone in the ulcer. Slough and/or eschar may be visible.
Unstageable pressure injury	Obscured full-thickness skin and tissue loss. The extent of tissue damage within the ulcer cannot be confirmed because it is obscured by slough and eschar.
Deep Tissue Pressure Injury	Intact or non-intact skin with localized area of persistent non-blanchable deep red, maroon, purple discoloration or epidermal separation revealing a dark wound bed or blood filled blister.

Epidemiology

The epidemiology of PI is influenced by many factors like study design, population characteristics and the applied classification whether milder forms are included or not. The overall reported prevalence is 3.6 -17.8 for acute and elderly care settings, while that for acute surgical, medical and emergency departments is 0.38%-20%*. Records from the National Health Service (NHS) in the UK revealed that from April 2014 to March 2015, approximately 25,000 patients were registered to have a new PI with an average of 2,000 new cases per month within England [52]. The estimated costs incurred from treating PI vary from £1,214 to £14,108. Expenses are more in severe cases attributed to a longer period of healing and higher complication rates [2]. Impairment in mobility, activity and perfusion-related variables are the major risk factors for developing PI, see **Box (1)**. The probability of developing stage II PI is also increased by 2-3 folds in patients with stage1 patients [3]. 75% of PIs are located around the pelvic girdle which follow the pressure distribution in normal individuals. **Figure (1)** illustrates the pressure distribution in normal man [1,4].

<p>Box (1): Risk factors for developing PI</p> <ul style="list-style-type: none"> • History of pressure sores • Immobility (spinal cord injury, post- surgery/injury, critical illness) • Past Neuropathy (spinal cord injury, diabetic neuropathy, other Neurological causes) • Abnormal posture (musculoskeletal abnormalities, spastic contractures) • Anemia • Poor nutrition • Obesity • Poor skin quality (age, endocrine disorders) • Perfusion related variables: Diabetes <p>Peripheral vascular diseases Smoking</p> <p><i>PI: Pressure Injury , reference: Farhadieh et al.,2015</i></p>
--

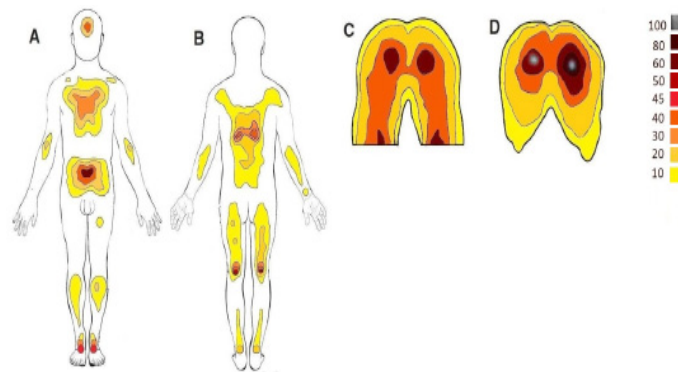


Figure 1: Distribution of pressures in a normal man.

(A) Supine position (B) Prone position (C) sitting, feet unsupported (D) sitting, feet supported.

Pathophysiology

As the name suggests, pressure is considered as a key element in PI development, aggravated by the presence of shear forces and/or moisture. This leads to cellular distortion and ischemia that will eventually result in necrosis and death. A rapid deterioration is catalysed by inflammation, infection and edema [1].

1.1. Pressure

PIs arise typically in tissues adjacent to bony prominences. When pressure exceeds the threshold of 32 mmHg, referring to the capillary bed pressure, ischemia will supervene as a result of capillary occlusion and perfusion impairment [5]. The degree of damage is directly proportional to the duration and the magnitude of the applied force. Repetitive stress is also attributed to the damage especially when it is repeated in short intervals before allowing tissue salvage, hence, generating a vicious ischemic – reperfusion cycle which aggravates tissue necrosis [6]. Studies on animal models showed that irreversible ischemia is ensued from applying as twice as pressure of the capillary bed for two hours duration [4].

Tissue response to the applied pressure is variant depending on the tissue structure and its mechanical nature. This phenomenon contributes to a different pressure distribution resulting in a cone-shaped pressure gradient, described by McClemon in 1984 **Figure (2)**. The Pressure inside the cone, also referred to as McClemon cone, is 3-5 times higher than that in the areas over the bony surfaces [7]. Furthermore, muscles are more susceptible to ischemia and the closer the muscle to the bone, the faster it dies. Contiguous tissues are also prone to death due to ischemia and reperfusion which if not halted, the necrosis will proceed toward the skin and eventually lead to cutaneous lesion that only represents the tip of the iceberg [8].

On the other hand, the huge pressure gradient will create a mechanical stress, called the shear force. The shear force will run parallel to the pressure plane and superimpose the damage via lowering the tissue tolerance threshold toward the perpendicular forces, hence, causing a sustained cellular deformation. This effect is escalated when it is accompanied by moisture which leads to skin maceration [9].

1.2. Inflammation

Once the tissue is injured, a cascade of coordinated events will be initiated. Starting from the inflammatory process which involves activation of neutrophils, macrophages, growth factors and a variety of cytokines. With time, the evolution of granulation, angiogenesis, epithelization and tissue remodeling occur in a normal wound healing process. However, in chronic wounds these series are often blocked rendering a sustained inflammatory state. Blood, fluid analysis and biopsies from non-healing wounds reveal elevated levels of inflammatory cytokines and matrix metalloproteinases (MMP) with minimal growth factors as compared with acute healing wounds. MMPs, particularly MMP-9, play a critical role during wound repair as it regulates immune cells migration and extracellular matrix remodeling. But a constant elevation of MMP-9 is manifested in patients with PI along with an imbalance between pro-oxidant and antioxidant systems, which is believed to impede the wound healing process. [10].

1.3. Edema

As a response to inflammation, Cyclo-Oxygenase 2 (COX-2), which is not normally expressed by the cells, will be induced resulting in increasing prostaglandin E secretion [11]. This, in turn, increases cellular membrane permeability and interstitial fluid collection. At a vascular level, Soft tissue compression will increase plasma extravasation and hinder lymphatic drainage. The neurological involvement, on the other hand, will result in impairment of the vascular wall tone resulting in vasodilation and vascular congestion. All those factors will eventually contribute to edema formation [1].

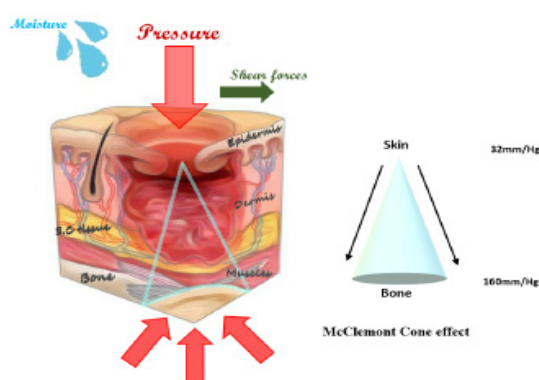


Figure 2: Pathophysiology of PI, McClellent cone effect.

Assessment

The patient and wound assessment is imperative to determine the severity, the treatment approaches, complications and prognosis.

1.4. General assessment

Braden, Norton and Waterlow scales are the most commonly used risk assessment tools, see **Table (2)**. They are designated to identify the patients at higher risk for more intensive

workup. However, in their review [12], highlighted the weakness of those instruments in predicting the patients who are more susceptible to develop PIs. Basically, a full history and careful examination are paramount to evaluate the risk factors and the associated comorbidities. Glucose level control should be evaluated via measuring HaemoglobinA1c (HbA1c). Previous management outcomes should be considered in patient with past history of PI. Additionally, it is crucial to assess the patients' functional and cognitive capacity to estimate their ability to move and to alter their lifestyle, as needed [6]. A full nutritional assessment should be performed. Albumin concentration is usually measured but it does not provide an actual impression of the nutritional condition since it has a long half-life. Alternative parameters can be used instead like, pre-albumin and transferrin [13]. See **Box (2)**.

1.5. Wound assessment

According to ([64]) (rapid inspection of the entire skin within the first 8 hours of admission, then on a daily basis, is recommended especially for early signs of stage1. Enough attention should be paid for the skin and soft tissue over bony prominences and near medical devices. When noting a darkly pigmented skin lesion, examination of changes in temperature, tone or tissue consistency in comparison with surroundings is a rule. Staging and assessment of wound bed /dimensions, palpable bones, and exudate characteristics are essential. A suspicion of osteomyelitis necessitates MRI or scintigraphy [6].

Table 2: Commonly used scales for risk assessment of pressure injuries.

Assessment parameter	Braden scale	Waterlow scale	Norton scale
Age	X	√	X
Weight	X	√	X
Mobility	√	√	√
Activity	√	X	√
Cognitive /mental status	√	X	√
nutritional status	√	√	X
Past PI History	X	X	X
Comorbidities	X	√	X
smoking	X	X	X
Medication	X	√	X
Physical status	X	√	√
Skin quality	X	√	X
Moisture	√	√	√
Shear forces	√	X	X
Sustained pressure	X	√	X

H&E history and examination, PI: Pressure Injury.

<p>Box (2): Laboratory investigations and imaging for PI</p> <ul style="list-style-type: none"> • Complete Blood Count(CBC) with differentials. • Glucose/haemoglobin A1c. • Albumin/pre-albumin. • Erythrocyte Sedimentation Rate (ESR) • C-Reactive Protein (CRP) • Magnetic Resonance Imaging (MRI). <p>Reference: [9]</p>

Prevention

To reverse the pathogenesis and to enhance the wound healing process, many preventive tools should be implemented. Those are summarized as SKINCARE bundle, see (Figure 3).

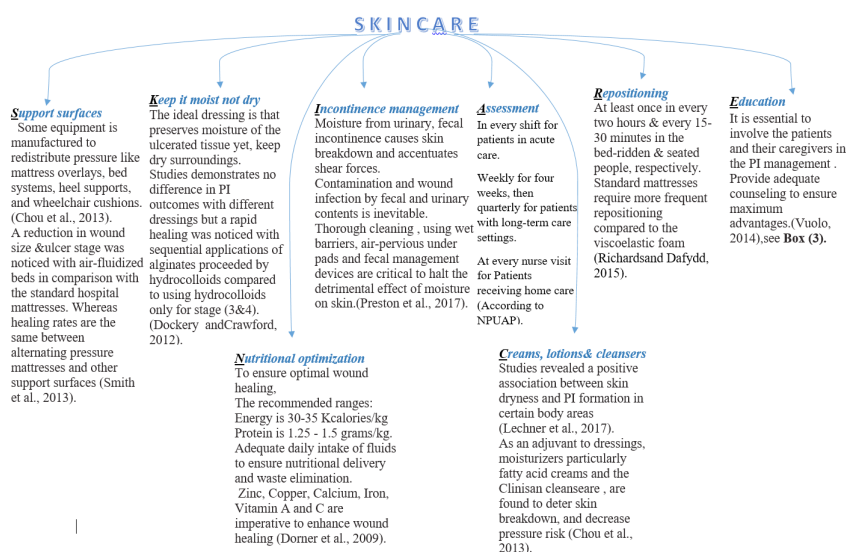


Figure 3: SKINCARE bundle for preventing Pressure Injury [65].

Management

Staging is the mainstay step in managing PI. Despite the fact that non-surgical modalities could be applied, surgery is the definitive option for management of deep injuries while non-surgical options are designated for superficial ones [14].

1.6. Non- surgical approaches

Local skin applications and adjunctive therapies are summarized in the management flowchart, see Figure(4).

1.7. Pre-operative care

Along with preventive measures explained, further actions are required to enhance patient situation prior to surgery.

1.7.1. Infection control

Infections should be strictly controlled in PI patients to prevent complications. *Proteus mirabilis*, *Corynebacterium*, group D *Streptococci*, *Escherichia coli*, *Staphylococcus* and *Pseudomonas* species are the most commonly isolated organisms from PIs [15]. Specimens from debrided tissues should be undergone microbiological testing to identify the inflicted microorganisms, their antimicrobial susceptibility and the quantitative load. Detecting more than 10^5 organisms/gram is an amenable sign of aggressive infection presaging failure of surgical closure. Many options are available for infected wounds, Dakin's solution (0.025% hypochlorite) is one of them. It is of a low cost and it is readily prepared. Other medications like Silvadene and Sulfamylon are usually used in ulcers with eschar [16].

On a systemic level, signs of infection like fever, leukocytosis, tachycardia, hypotension and altered mental status should be carefully monitored especially in extensive ulcers and in immunocompromised cases. Systemic antibiotics can be given. However, a prodigious balance between infection control and adverse effects which is directly correlated to patient morbidity and antibiotic resistance is the key [15].

Because of the wide diversity of microorganisms implicated in PIs, empirical therapy is preposterous. Occasionally, third-generation cephalosporins and glycopeptides may be used blindly but no longer than 3–5 days to be corroborated with a sensitivity test then. Specific antibiotics should be continued for 3 weeks unless general signs and symptoms (fever, osteomyelitis, arthritis, and bacteremia) evolve when the treatment should be maintained for 6 weeks. [17].

1.7.2. Spasticity and contracture control

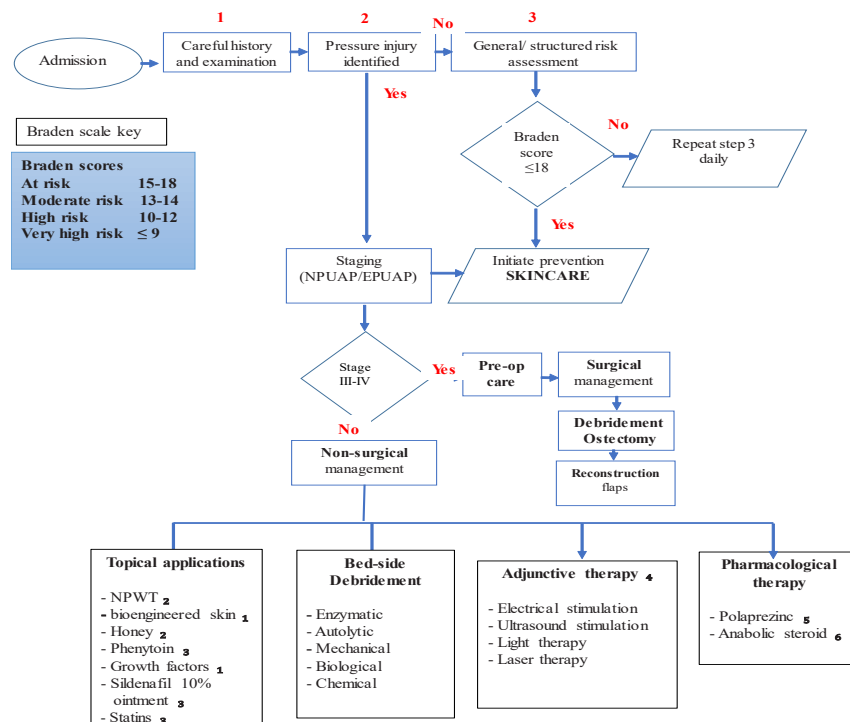
Patients with Spinal Cord Injury (SCI) or a permanent bed-binding status are prone to spasticity and contracture which have to be resolved before surgery. Pharmacological treatments for spasm include: baclofen, diazepam, and dantrolene are used. A significant effect of Botulinum toxin in improving upper and lower limbs spasticity is also noticed. It lasts for 3 months on average and usually shows a dramatic relief of pain as well as an improvement in function and movement of the upper limbs. Second line surgical therapy would be endorsed whenever non-invasive techniques fail [5]. Those include peripheral nerve blocks, epidural stimulators, baclofen pumps, and rhizotomy. The latter can be done even medically through performing subarachnoid blocks with phenol (phenol rhizotomy) [1].

Treating contracture before surgery will prevent PI recurrence especially in Hip and knee joints, the most common sites of contracture, due to their attribution to trochanteric, knee, and ankle ulcers development. Physiotherapy is devoted to solve this issue, which is if failed, tenotomies will be indicated. However, flail extremities may be resulted from hip joint release

detering patient transmission. [1].

1.7.3. Comorbidities

Comorbid conditions should to be controlled before proceeding to surgery. A tight control of diabetes is essential. Smoking cessation is also crucial and should be warranted for several weeks prior to the surgery. This can be proved by performing a urine cotinine test [16]. Assessing and treating anemia should be considered in every patient with PI. Patients with SCI require fecal control by controlling the bowel habits or utilizing diverting colostomy [1].



1. [13], Bioengineered skin is used in non-exudative PI. It enhances tissue growth. Local growth factors are effective in promoting wound healing.

2. [34], NPWT: Negative Pressure Wound Therapy, the Mechanism Of Action(MOA) is to reduce edema and wound size and increase vascularization. However, evidence demonstrates uncertainty regarding its effect in treating PIs. Honey: (MOA): antimicrobial, immunological enhancing activity, effective in Pressure ulcer healing.

3. [35], phenytoin: is an anti-epileptic drug. Several studies show that topical phenytoin promote wound healing, the effect in PIs is inconclusive, however. Statins:, have anti-inflammatory and anti-oxidants effect. sildenafil is an inhibitor of cyclic Guanosine Monophosphate (cGMP)-specific phosphodiesterase type 5 (PDE-5), increase Nitric oxide level to cause vasodilation, hence, enhancing blood supply. Both of them may potentially encourage PIs healing.

4. [36], electrical stimulation: “Direct electric current delivered through the wound bed using surface electrodes” found to improve the healing in PIs. Therapeutic ultrasound: “Transmission of low-frequency sound waves through the soft tissue” and laser therapy show no differences in wound healing. Light therapy may improve wound healing in PIs.

5. [37], Polaprezinc (zinc L-carnosine complex) is primarily used for gastric ulcers, may be effective in PIs wound healing.

6. [38], anabolic steroids : considered because of their action in enhancing skeletal muscles growth and protein synthesis. Their role in PIs healing is not highly evident.

Figure 4: A flow chart summary for managing patients with PI.

EPUAP: European Pressure Ulcer Advisory Panel, NPUAP: National Pressure Ulcer Advisory Panel , pre-op: preoperative.

1.8. Perioperative Care

While planning for surgery, critical perioperative physiological responses should be considered especially in SCI patients that may result in increased morbidity and mortality, such as vascular disturbances (autonomic dysreflexia “AD” and orthostatic hypotension), thromboembolic events, spasticity and perioperative pain control [53].

AD is a massive sympathetic discharge that is caused by a stimulus (i.e. PI debridement or reconstruction) below the SCI level. This leads to a peripheral vasoconstriction below the injury level, persistent hypertension and reflex bradycardia. Eventually, this will result in haematoma formation, poor tissue perfusion, flap necrosis and death (if not treated). Furthermore, deep venous thrombosis (DVT) and pulmonary embolism (PE) prophylaxis approach for the SCI non-ambulatory patients should be the same as for ambulatory patients [53].

1.9. Planning for Surgical Reconstruction

Management of PI consists of two paradigms. The conservative “wound-care” approach involves optimising patient’s general health state through correcting nutritional deficiencies, relieving pressure and extrinsic factors, controlling infection, bed-side debridement, managing comorbidities and eliminating any other factors associated with wound healing impairment. While the surgical approach comprises radical debridement, ostectomy and flap reconstruction [18]. According to the latest NPUAP clinical practice guidelines, Stage I and II superficial ulcers can be managed conservatively, while Stage III and IV deeper ulcers have to be surgically treated [14].

Since PI is described as “absolute tissue deficiency”, the reconstructive ladder does not necessarily imply that the simplest option (i.e. secondary intention, primary closure or skin graft) is the most suitable because these reconstructive modalities do not provide soft tissue bulk and subsequently recurrence will ensue [6,20]. Primary closure should not be attempted because pulling tissues over a bony prominence will result in tension and wound dehiscence. Skin grafts have a limited success because of lacking tissue bulk and inability to withstand pressure and shearing forces [19, 20].

The surgical guidelines of PI reconstruction include sufficient wound debridement, dead space obliteration, durable cutaneous coverage, large flap design with suture lines away from the pressure points, and securing adjacent flap territories for possible future use [22].

1.9.1. Musculocutaneous and Muscle Flaps

These flaps offer a reliable blood supply, superior infection control and a bulky padding for better pressure distribution and dead space obliteration [22]. However, the major drawback is the sacrifice of muscle with a possible functional deficit in ambulatory patients, besides

muscle atrophy in the long-term [23].

1.9.2. Fasciocutaneous and Perforator Flaps

Fasciocutaneous flaps provide adequate vascularity with durable coverage as well as the preservation of muscle integrity and function, thus minimizing functional deficit and donor site morbidity. Disadvantages involve limited flap bulk in deep and large ulcers, the need for a large rotation arc and lower infection control [23]. Similarly, perforator flaps have the same benefits of fasciocutaneous flaps with the feasibility of a better aesthetic outcome. As described by the perforasome theory, a flap can be based on a free or pedicled perforator [22].

1.9.3. Tissue Expansion

It is considered as a valuable option for PI reconstruction, particularly in SCI patients. It offers the advantage of sensate flap advancement for the reconstruction of insensate shallow ulcer that does not require dead space obliteration. This will ultimately enhance pressure perception to avoid future recurrence. Additionally, it provides a suitable solution for unstable wound coverage, which was previously resurfaced by a skin graft or healed by secondary intention [24].

1.9.4. Microvascular Reconstruction

Free flaps can be considered when loco-regional flaps are not applicable or have failed, and in case of large and deep ulcers on weight bearing areas (i.e. sole or amputation stumps) to adequately restore volume [25].

The results of a systematic review comparing the complications and recurrence in musculocutaneous, fasciocutaneous and perforator flaps, suggested no statistically significant variation [15].

1.10. Debridement

Debridement aims to excise the necrotic, infected and fibrous scar tissue [20] to convert the ulcer from chronic to acute state in order to progress through the normal wound healing stages [25].

Surgical debridement is characterised by being fast with more precise identification of the cavity extension, especially with the use of methylene blue dye for marking. Additionally, it enables deep tissue sampling for microbiological culture and quantification. This is very critical, as surgical closure is abandoned in the presence of any level of β -haemolytic streptococci or bacterial counts $>10^5$ CFU/gram. It may comprise bursectomy and infected bone removal for eventual wound closure. However, it may be associated with bone or tendon exposure and significant blood loss [26]. Other types of debridement are enlisted in **(Table 3)**.

Table 3: Types of bed-side debridement.

Debridement method	Type
1. Biologic debridement	Sterile larvae or maggots
2. Enzymatic debridement	Collagenase, Papain or Urea
3. Autolytic debridement	Natural wound fluid and endogenous enzymes
4. Chemical debridement	Sodium hypochlorite (Dakin's Solution)
5. Mechanical debridement	Wet to dry dressings, wound cleansing and pressure irrigation (water jets or pulsed lavage)

References: [28,34]

1.11. Ostectomy

Bone debridement is an integral part of PI reconstruction since osteomyelitis is caused by penetration of the ulcer into the bony prominence [27]. On the other hand, pressure necrosis is the ultimate result of excessive soft tissue compression between the bony prominences and the supporting surface [28].

Ostectomy is carried out until reaching a healthy and bleeding bone followed by deep bone culture and bone biopsy to guide the proper antibiotic therapy postoperatively [29]. However, bone excision must be as little as possible, particularly at the ischial area to prevent vital structures exposure (i.e. urethra) and pressure points redistribution to the adjacent areas [28].

1.12. Surgical Reconstruction of Pressure Injury

1.12.1. Ischial Pressure Injury

Ischial PI usually develops in wheelchair mobilised paraplegic patients who usually forget to regularly change their position, leading to unrelieved persistent pressure over the ischial tuberosity. The site of ischial ulcer is the most important anatomical factor contributing to recurrence [30]. It is the main weight bearing site in those patients and continuously liable to mobility because of muscular spasms [31]. Reconstruction is usually carried out by musculocutaneous, fasciocutaneous and perforator flaps or in some cases free flaps [31], See **(Figure 5)**. Current reconstructive options are enlisted in **(Table 4)**.

Table 4: Current reconstructive options for Ischial Pressure Injury

Flap	Type / Blood Supply	Description
Gluteus Maximus Flap -rotation -advancement -island -muscle splitting	-Musculocutaneous -Superior and inferior gluteal arteries	<ul style="list-style-type: none"> It is an excellent first option for coverage and dead space obliteration in non-ambulatory patients because it has a large skin paddle and large muscle and soft tissue bulk. In case of local recurrence, it can be revised, re-elevated, re-advanced or re-rotated. According to the patient's ambulatory state, entire or segmental muscle flap can be chosen because it leads to muscle function compromise and atrophy. [4,5, 39]

<p>Inferior Gluteal Island Flap</p>	<p>-Musculocutaneous -Inferior gluteal artery</p>	<ul style="list-style-type: none"> • This rotation flap is a reliable option for ambulatory patients because it conserves muscle function by using only the lower half of the gluteus maximus. • It doesn't prevent future use of the posterior thigh flap. • Modifications for ambulatory patients to be less debilitating: Split inferior gluteal muscle flap Inferior gluteal artery perforator flap <p>[5, 1, 5, 24 ,68]</p>
<p>V-Y Hamstring Advancement Flap</p>	<p>-Musculocutaneous -Perforators of the profunda femoris artery</p>	<ul style="list-style-type: none"> • For SCI patients, it is based on biceps femoris, semitendinosus and semimembranosus muscles. While for ambulatory patients, it includes only biceps femoris to preserve function. • It is effective and can be re-advanced in case of recurrence. • Disadvantages: tension closure, scar lies over the maximal pressure points and hip flexion predisposes to wound dehiscence. <p>[24,21]</p>

SCI: Spinal Cord Injury, L3: third lumbar vertebra.

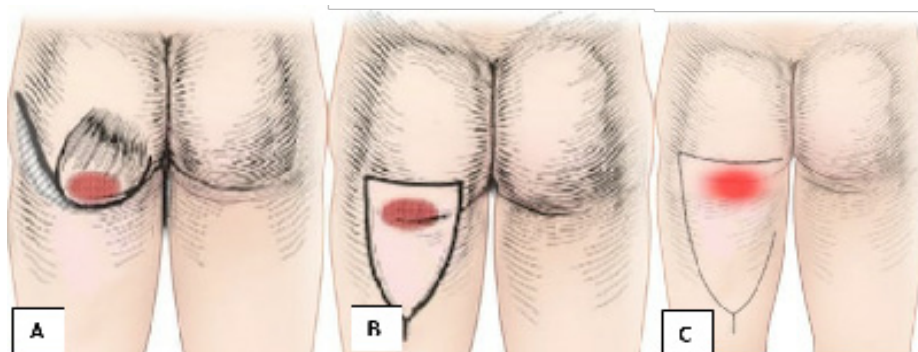


Figure 5: Ischial pressure injury.

(A) Gluteus Maximus Musculocutaneous Rotation Flap (B) V-Y Hamstring Advancement Flap (C) Posterior Thigh Flap - medially based V-Y advancement flap

1.12.2. Sacral Pressure Injury

Sacral PI occurs in bedridden paraplegic patients who are prone to unrelieved sustained pressure over the sacral bone. Various surgical techniques have been used for ulcer reconstruction like skin grafts, musculocutaneous and fasciocutaneous flaps. In addition to the rapid advancement in the promising fields of perforator flaps and free flaps [32], See Figure (6). Current reconstructive options are enlisted in (**Table 5**).

Table 5: Current reconstructive options for Sacral Pressure Injury.

Flap	Type / Blood supply	Description
Skin Graft	Split thickness	<ul style="list-style-type: none"> It can be used for small superficial ulcer that is not profusely discharging with no vital structures exposure and the ulcer is attributed to acute transitory illness [25].
Gluteus Maximus Flap -rotation -V-Y advancement -transposition -island -sliding -muscle splitting -turn over	-Musculocutaneous, muscle or fasciocutaneous flap -Superior and inferior gluteal arteries	<ul style="list-style-type: none"> It is a versatile first option flap for coverage that can be based superiorly or inferiorly. Fasciocutaneous flaps are universally favoured because they conserve muscle integrity and function, particularly in ambulatory patients and have a better outcome. Rotation flap and V-Y advancement flap: <ul style="list-style-type: none"> ✓ These design modifications can be unilateral or bilateral, musculocutaneous or fasciocutaneous flaps. ✓ They can be re-advanced / re-rotated if recurrence occurs. ✓ For preservation of muscle function in ambulatory patients, the superior muscle portions are solely advanced / rotated and used as segmental flaps. For small defects, the sliding flap can be used, while for larger defects, the transposition flap is more suitable. [1, 4, 29, 51]
Superior Gluteal Artery Island Flap	-Musculocutaneous -Superior gluteal artery	<ul style="list-style-type: none"> It is a good option for ambulatory patients because it conserves muscle function by using only the upper half of the gluteus maximus, besides offering a suitable padding and protection. If the sacral defect < 6 cm then unilateral flap is sufficient for coverage, while bilateral flaps are reserved for larger defects. [67]
Superior Gluteal Artery Perforator Flap (SGAP)	- Fasciocutaneous - Superior gluteal artery	<ul style="list-style-type: none"> SGAP flap is reliable and provides bulky soft tissue padding with minimal complications. Flap design is associated with less blood loss, better defect match and enhanced rotation arc. However, it requires meticulous preoperative perforator mapping. Disadvantages: It is a lengthy procedure, requires experience in flap harvesting and perforator identification, and not suitable for deep defects. [32]

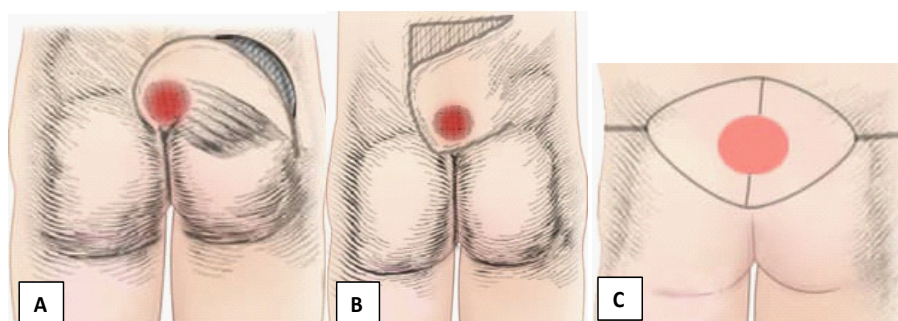


Figure 6: Figure (6): Sacral pressure injury
 (A) Gluteus Maximus Musculocutaneous Rotation Flap
 (B) Transverse LumboSacral Back Flap
 (C) Gluteus Maximus Musculocutaneous Bilateral V-Y Advancement Flap

1.12.3 Trochanteric Pressure Injury

Trochanteric PI commonly develops in bed-bound paraplegic elderly patients in lateral decubitus position due to excessive direct pressure over the trochanteric area for a prolonged period [33], See (Figure 7). Current reconstructive options are enlisted in (Table 6).

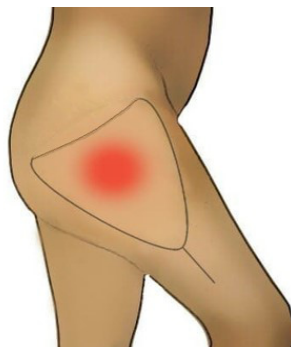


Figure 7: Trochanteric pressure injury Tensor Fascia Lata (TFL) V-Y Advancement Flap.

Table 6: Current reconstructive options for Trochanteric Pressure Injury.

Flap	Type / Blood supply	Description
Tensor Fascia Lata Flap (TFL) -V-Y: advancement Island retroposition -rotation -transposition -bilobed -hatchet flap	-Musculocutaneous or muscle flap -lateral femoral circumflex artery	<ul style="list-style-type: none"> It is a versatile flap and mainly indicated in case of large soft tissue defect and refractory osteomyelitis. It is bulky, robust and adds suitable padding. It can be re-elevated and re-advanced in case of recurrence. Disadvantages of traditional TFL flap: bulky appearance, dog-ear deformity, donor site closure often requires skin grafting and unreliable distal portion vascularity. [5, 27, 54]
Tensor Fascia Lata Flap (TFL) Perforator Flap	-Fasciocutaneous -Perforators from the TFL muscle	<ul style="list-style-type: none"> It allows harvesting large flaps with design freedom. Its lumbar innervation (L1, L2, L3) makes it a sensate flap in SCI patients below L3. It can be reused in case of recurrence. Disadvantages: it requires meticulous transmuscular dissection and the risk of pedicle twisting. TFL perforator-based island flap (TFL-PBIF): The concept is based on the presence of constant perforators around the TFL muscle and the numerous microperforators in the proximal undissected part of the flap. <ul style="list-style-type: none"> ✓ Flap elevation does not require proximal vessel identification or meticulous transmuscular dissection for perforator skeletonization. ✓ Other advantages: primary closure of the donor site, minimizing dog-ear deformity and tension-free closure at the T junction. [1,54]
Anterolateral Thigh Flap (ALT)	-Fasciocutaneous -Perforators of the descending branch of the lateral circumflex femoral artery	<ul style="list-style-type: none"> Pedicled ALT flap offers excellent flap design flexibility and tremendous potential for skin replacement. It has a large vascular territory and a long vascular pedicle with similar perfusion pre and postoperatively. It could be used as a sensate flap by including the anterior or lateral branches of the lateral cutaneous nerve of the thigh. Disadvantages: donor site closure may require skin grafting. ALT musculocutaneous flap: This modification offers a reliable blood supply with a bulky padding especially for infected ulcers. [27,41]
Chimeric Flap	-Musculocutaneous, muscle and fasciocutaneous flaps	<ul style="list-style-type: none"> Combination of ALT flap, vastus lateralis flap, rectus femoris muscle flap and gluteus maximus flap. [28]

Table 7: Current reconstructive options for complicated Pressure Injury

Condition	Operative technique	Description
Septic Arthritis of the hip joint	-Modified Girdlestone procedure	<ul style="list-style-type: none"> • It usually develops secondary to trochanteric or ischial PI especially in SCI patients [56]. • The diagnosis is based on the clinical, radiological and bacteriological evaluation (the usual microorganism is Staphylococcus aureus and to a lesser extent Gram-negative species) [56]. • Modified Girdlestone procedure is a 3 stages operation (1 week in between) involving proximal femoral resection and formation of granulation tissue, dead space obliteration by vastus lateralis muscle flap and split-thickness skin graft [65]. • Recent modification is a single stage operation: Girdlestone procedure with immediate dead space obliteration by vastus lateralis [55] or rectus femoris muscle flaps [65].
Heterotopic Ossification (HO) of the hip joint in SCI patients	-Joint sparing excision -Modified Girdlestone procedure	<ul style="list-style-type: none"> • HO in SCI patients has two patterns: [70] <ul style="list-style-type: none"> ✓ Neurogenic pattern: occurs early after SCI and usually bilateral with worse outcome. ✓ Infection-driven pattern: associated with pressure injury or septic hip arthritis and commonly unilateral. • Surgical management: [70] <ul style="list-style-type: none"> ✓ Joint sparing excision (wedge resection): for limited HO with absent infection. ✓ Modified Girdlestone procedure: for extensive HO with or without PI.

PI: Pressure Injury, SCI: Spinal Cord Injury

Table 7: Current reconstructive options for complicated Pressure Injury

Complication	Description
Short-term complications	
Hematoma	<ul style="list-style-type: none"> • Fluid collections are mainly caused by inadequate dead space obliteration [29]. Once occurred then should be evacuated [6].
Seroma	<ul style="list-style-type: none"> • Minor wound dehiscence is treated conservatively with local wound care while larger dehiscence necessitates debridement and flap re-advancement [9].
Wound dehiscence	<ul style="list-style-type: none"> • Prevention: tension-free closure and leaving the drains and sutures for 2-3 weeks [6].
Wound infection	<ul style="list-style-type: none"> • It can be prevented by administering perioperative broad-spectrum antibiotics that are usually continued for 6 weeks [6]. • Superficial infection is treated with local wound care and antibiotics while deeper infection requires debridement [9].
Partial / Total flap necrosis	<ul style="list-style-type: none"> • Flap viability is compromised due to flap hypoperfusion (insufficient blood supply or hypotension), infection, flap compression by underlying fluid collections, and vasoconstricting agents [29].
DVT / PE	<ul style="list-style-type: none"> • Prophylactic measures include compression stockings or devices with prophylactic doses of anticoagulation [53]. • Physiotherapy and mobilization should be commenced as soon as clinically applicable [53].
Long-term complications	

Recurrence	<ul style="list-style-type: none"> • The recurrence rate of PI was reported to be as high as 80% with wide variation. • Ulcer recurrence is the interplay of multiple factors: <ul style="list-style-type: none"> ✓ Younger age <45 years ✓ Anatomical location: ischial PI ✓ Race: Afro-Americans ✓ BMI < 18.5 ✓ Smoking ✓ Thigh V-Y flaps: because closure is usually under tension ✓ Perioperative blood transfusion • Other non-independent risk factors: <ul style="list-style-type: none"> ✓ Longer operative duration and larger size wounds are associated with increased risk of infection and wound dehiscence. ✓ Underlying acute osteomyelitis and low levels of prealbumin and albumin are associated with increased risk of wound dehiscence. ✓ Diabetes and ASA class 3 or higher are associated with increased risk of infection. <p>[42]</p>
-------------------	--

Table 8: Short-term & Long-term complications of Pressure Injury.

Complication	Description
Short-term complications	
Hematoma	<ul style="list-style-type: none"> • Fluid collections are mainly caused by inadequate dead space obliteration [29]. Once occurred then should be evacuated [6].
Seroma	<ul style="list-style-type: none"> • Minor wound dehiscence is treated conservatively with local wound care while larger dehiscence necessitates debridement and flap re-advancement [9].
Wound dehiscence	<ul style="list-style-type: none"> • Prevention: tension-free closure and leaving the drains and sutures for 2-3 weeks [6].
Wound infection	<ul style="list-style-type: none"> • It can be prevented by administering perioperative broad-spectrum antibiotics that are usually continued for 6 weeks [6]. • Superficial infection is treated with local wound care and antibiotics while deeper infection requires debridement [9].
Partial / Total flap necrosis	<ul style="list-style-type: none"> • Flap viability is compromised due to flap hypoperfusion (insufficient blood supply or hypotension), infection, flap compression by underlying fluid collections, and vasoconstricting agents [29].
DVT / PE	<ul style="list-style-type: none"> • Prophylactic measures include compression stockings or devices with prophylactic doses of anticoagulation [53]. • Physiotherapy and mobilization should be commenced as soon as clinically applicable [53].
Long-term complications	
Recurrence	<ul style="list-style-type: none"> • The recurrence rate of PI was reported to be as high as 80% with wide variation. • Ulcer recurrence is the interplay of multiple factors: <ul style="list-style-type: none"> ✓ Younger age <45 years ✓ Anatomical location: ischial PI ✓ Race: Afro-Americans ✓ BMI < 18.5 ✓ Smoking ✓ Thigh V-Y flaps: because closure is usually under tension ✓ Perioperative blood transfusion • Other non-independent risk factors: <ul style="list-style-type: none"> ✓ Longer operative duration and larger size wounds are associated with increased risk of infection and wound dehiscence. ✓ Underlying acute osteomyelitis and low levels of prealbumin and albumin are associated with increased risk of wound dehiscence. ✓ Diabetes and ASA class 3 or higher are associated with increased risk of infection. <p>[42]</p>

Malignant transformation	<ul style="list-style-type: none"> • Marjolin's ulcer is a locally infiltrative lesion with lymphatic metastasis potential and commonly involves the sacral and iliac pressure sores. • The most frequent histological type is squamous cell carcinoma (SCC) but locally and systemically more aggressive than SCC of different aetiology. • Incisional biopsies should be performed in case of suspicious verrucous wound that is ulcerating for 3-6 months without response to local treatment. • Management: wide local excision with (2–5) cm safety margin, en-block excision of the involved local lymph nodes and primary or delayed skin grafting. • Chemotherapy and radiotherapy are used for unrespectable tumour with distant metastasis. <p>(Bazaliński et al., 2017)</p>
---------------------------------	---

Postoperative Care

Many of the preoperative care measures should be continued postoperatively. This involves optimization of the nutritional supplementation, bowel and bladder regimen, muscle spasticity control and culture guided antibiotic therapy. Besides, Pressure free positioning to achieve flap offloading for 3-4 weeks accompanied by the use of pressure dispersing surfaces (low air loss mattress) and patient repositioning every 2 hours. The reseating protocol should be gradual and start after the period of flap offloading. It usually begins with intervals of 15-30 minutes and progresses to achieve 2 hours' duration at 6 weeks [16].

Conclusion

Pressure injury represents a formidable challenge particularly in patients with functional and sensory deficits. It has a major impact on the duration of patient hospitalization and subsequently the healthcare resources. Since the aetiology of PI is multifaceted, then the ideal management paradigm should be based on a holistic multidisciplinary team (MDT) approach in order to optimise the patient's general health status and treat the modifiable comorbidities. Moreover, careful patient's selection, appropriate risk factors identification and stratification, thorough evaluation and adherence to the surgical guidelines of PI reconstruction are the key steps for a successful outcome that will ultimately lead to a fruitful balance between the benefit of surgical intervention and the risk of postoperative complications. As PI is associated with high recurrence rate, therefore a proper and extensive patient's follow up along with applying all prevention measures, comprehensive educational programs, social support and motivation are mandatory in the postoperative period.

References

1. THORNE C H. Grabb and Smith's plastic surgery, Wolters Kluwer Health/Lippincott Williams & Wilkins. 2014.
2. Dealey C, Posnett J, Walker A. The cost of pressure ulcers in the United Kingdom. *Journal of wound care*. 2012; 21: 261-266.
3. Coleman S, Gorecki C, Nelson EA, Closs SJ, Defloor T, Halfens R, et al. Patient risk factors for pressure ulcer development: systematic review. *International journal of nursing studies*. 2013; 50: 974-1003.
4. JANIS J E. *Essentials Of Plastic Surgery*, CRC Press/Taylor & Francis Group. 2014.

5. Serletti J M, Taub P J, Wu L C, Slutsky D J. *Current Reconstructive Surgery*, The McGraw-Hill Companies. 2013.
6. ARHADIEH R D. *Plastic and Reconstructive Surgery: Approaches and Techniques*, WILEY Blackwell/John Wiley & Sons. 2015.
7. DUNK AM, GARDNER A. The contribution of pressure gradients to advancing understanding of deep tissue injury to sacral regions. *Wound Practice & Research: Journal of the Australian Wound Management Association*. 2015; 23: 116.
8. Preston A, Rao A, Strauss R, Stamm R, Zalman D. Deep Tissue Pressure Injury: A Clinical Review. *AJN, American Journal of Nursing*. 2017; 117: 50-57.
9. BROWN D L, BORSCHEL G H, LEVI B. *Michigan Manual of Plastic Surgery*, Wolters Kluwer Health/Lippincott Williams & Wilkins. 2014.
10. Latifa K, Sondess S, Hajer G, Manel B, Souhir K, Nadia B, et al. Evaluation of physiological risk factors, oxidant-antioxidant imbalance, proteolytic and genetic variations of matrix metalloproteinase-9 in patients with pressure ulcer. *Scientific Reports*. 2016; 6.
11. Romana-Souza B, Santos JSD, Bandeira LG, Monte-Alto-Costa A. Selective inhibition of COX-2 improves cutaneous wound healing of pressure ulcers in mice through reduction of iNOS expression. *Life sciences*. 2016; 153: 82-92.
12. Chou R, Dana T, Bougatsos C, Blazina I, Starmer AJ, Reitel K, et al. Pressure Ulcer Risk Assessment and Prevention. *Annals of Internal Medicine*. 2013; 159: 28.
13. GREY JE, HARDING KG, ENOCH S. ABC of wound healing: pressure ulcers. *BMJ: British Medical Journal*. 2006; 332: 472.
14. Marchi M, Battaglia S, Marchese S, Intagliata E, Spataro C, Vecchio R. Surgical reconstructive procedures for treatment of ischial, sacral and trochanteric pressure ulcers. *Il Giornale di chirurgia*. 2015; 36: 112-6.
15. Kruger EA, Pires M, Ngann Y, Sterling M, Rubayi S. Comprehensive management of pressure ulcers in spinal cord injury: Current concepts and future trends. *The Journal of Spinal Cord Medicine*. 2013; 36: 572-585.
16. Cushing CA, Phillips LG. Evidence-Based Medicine: Pressure Sores. *Plastic and Reconstructive Surgery*. 2013; 132: 1720-1732.
17. Heym B, Rimareix F, Lortat-Jacob A, Nicolas-Chanoine M. Bacteriological investigation of infected pressure ulcers in spinal cord-injured patients and impact on antibiotic therapy. *Spinal Cord*. 2004; 42: 230-234.
18. Diamond S, Moghaddas HS, Kaminski SS, Grotts J, Ferrigno L, Schooler W. National Outcomes after Pressure Ulcer Closure: Inspiring Surgery. *The American Surgeon*. 2016; 82: 903-906.
19. DI GIUSEPPE A, SHIFFMAN M A. *New Frontiers in Plastic and Cosmetic Surgery*, The Health Sciences Publisher/Jaypee Brothers Medical Publishers (P) Ltd. 2015.
20. Therattil PJ, Pastor C, Granick MS. Sacral Pressure Ulcer. *Eplasty*. 2013; 13.
21. RICHARDS A, DAFYDD H. *Key Notes on Plastic Surgery*, WILEY Blackwell/John Wiley & Sons. 2015.
22. Kim CM, Yun IS, Lee DW, Lew DH, Rah DK, Lee WJ. Treatment of Ischial Pressure Sores with Both Profunda Femoris Artery Perforator Flaps and Muscle Flaps. *Archives of Plastic Surgery*. 2014; 41: 387.
23. Kuo P, Chew K, Kuo Y, Lin P. Comparison of outcomes of pressure sore reconstructions among perforator flaps, perforator-based rotation fasciocutaneous flaps, and musculocutaneous flaps. *Microsurgery*. 2014; 34: 547-553.
24. NELIGAN P C, SONG D H. *Plastic Surgery*, ELSEVIER. 2018.

25. Bhattacharya S, Mishra RK. Pressure ulcers: Current understanding and newer modalities of treatment. *Indian Journal of Plastic Surgery : Official Publication of the Association of Plastic Surgeons of India*. 2015; 48: 004-016.
26. HUNTER I A, DAVIES J. Managing pressure sores. *Surgery (Oxford)*. 2014; 32: 472-476.
27. DIAZ S, LI X, RODRÍGUEZ L, SALGADO C. Update in the Surgical Management of Decubitus Ulcers. *Anaplastology*, 02. 2013.
28. Gould L, Stuntz M, Giovannelli M, Ahmad A, Aslam R, Mullen-Fortino M, et al. Wound healing society 2015 update on guidelines for pressure ulcers. *Wound Repair and Regeneration*. 2016; 24: 145-162.
29. NELIGAN P C, SONG D H. *Plastic Surgery*, ELSEVIER SAUNDERS. 2013.
30. Chiu Y, Liao W, Wang T, Shih Y, Ma H, Lin C, et al. A retrospective study: Multivariate logistic regression analysis of the outcomes after pressure sores reconstruction with fasciocutaneous, myocutaneous, and perforator flaps. *Journal of plastic, reconstructive & aesthetic surgery: JPRAS*. 2017; 70: 1038-1043.
31. Djedovic G, Morandi EM, Metzler J, Wirthmann A, Matiasek J, Bauer T, et al. The posterior thigh flap for defect coverage of ischial pressure sores – a critical single-centre analysis. *International Wound Journal*. 2017; 14: 1154-1159.
32. Khurram MF, Khan AH, Ahmad I, Nanda M, Masoodi Z. Superior gluteal artery perforator flap: a reliable method for sacral pressure ulcer reconstruction. *Journal of wound care*. 2013; 22: 699-703.
33. Li C, Chang S, Fu J, Tzeng Y, Wang C, Chen T, et al. Comparison of Hatchet-Shaped Tensor Fascia Lata Flap and Pedicle Anterior Lateral Thigh Flap for Treatment of Trochanteric Sores: A Retrospective Analysis of 48 Patients. *Annals of Plastic Surgery*. 2013; 71: 659-663.
34. Levine SM, Sinno S, Levine JP, Saadeh PB. Current Thoughts for the Prevention and Treatment of Pressure Ulcers: Using the Evidence to Determine Fact or Fiction. *Annals of Surgery*. 2013; 257: 603-608.
35. Home KU, Rafia R, Funk RS, Backes J, Bates J, et al. Topical pharmacological treatment for pressure ulcers.
36. Smith ME, Totten A, Hickam DH, Fu R, Wasson N, et al. Pressure ulcer treatment strategies: a systematic comparative effectiveness review. *Ann Intern Med*. 2013; 159: 39-50.
37. Sakae K, Yanagisawa H. Oral Treatment of Pressure Ulcers with Polaprezinc (Zinc L-carnosine Complex): 8-Week Open-Label Trial. *Biological Trace Element Research*. 2014; 158: 280-288.
38. Naing C, Whittaker MA. Anabolic steroids for treating pressure ulcers. *The Cochrane database of systematic reviews*. 2017; 6: CD011375.
39. Diaz S, Li X, Rodriguez L, Salgado C. Update in the Surgical Management of Decubitus Ulcers. *Anaplastology*. 2013: 02.
40. Amir Y, Tan F E, Halfens R, Lohrmann C, Schols J. Pressure Ulcer Prevalence and Care In Indonesian Hospitals: A Multicenter, Cross-Sectional Evaluation Using An Extended Donabedian Model. *Ostomy Wound Manage*. 2017; 63: 8-23.
41. BAHK, S., RHEE, S. C., CHO, S. H. & EO, S. R. 2015. Pedicled Anterolateral Thigh Flaps for Reconstruction of Recurrent Trochanteric Pressure Ulcer. *Archives of Reconstructive Microsurgery*, 24, 32-36.
42. Bamba R, Madden JJ, Hoffman AN, Kim JS, Thayer WP, Nanney LB, et al. Flap Reconstruction for Pressure Ulcers: An Outcomes Analysis. *Plastic and Reconstructive Surgery Global Open*. 2017; 5: e1187.
43. Barrois B, Colin D, Allaert F. Prevalence, characteristics and risk factors of pressure ulcers in public and private hospitals care units and nursing homes in France. *Hospital Practice*. 2018; 46: 30-36.
44. Bazaliński D, Przybek-Mita J, Barańska B, Więch P. Marjolin's ulcer in chronic wounds – review of available

literature. *Contemporary Oncology*. 2017; 21: 197-202.

45. Carryer J, Weststrate J, Yeung P, Rodgers V, Towers A, Jones M. Prevalence of key care indicators of pressure injuries, incontinence, malnutrition, and falls among older adults living in nursing homes in New Zealand. *Research in Nursing & Health*. 2017; 40: 555-563.

46. CHRISTIAN D, LELAND H, RUBAYI S. Major Repair for End Stage Pressure Ulcer in a Spinal Cord Injury Patient by Disarticulation and Total Thigh Flap a Case Report. *J Dermatol Plast Surg*. 2016; 1: 1005.

47. DOCKERY G D, CRAWFORD ME. *Lower Extremity Soft Tissue & Cutaneous Plastic Surgery* Saunders Ltd. 2012.

48. Dorner B, Posthauer ME, Thomas D. The role of nutrition in pressure ulcer prevention and treatment: National Pressure Ulcer Advisory Panel white paper. *Advances in skin & wound care*. 2009; 22: 212-221.

49. Fujioka M, Hayashida K, Morooka S, Saijo H. A retrospective comparison of perforator and rotation flaps for the closure of extensive Stage IV sacral pressure ulcers. *Ostomy/wound management*. 2014; 60: 42-8.

50. Gupta S, Chattopadhyay D, Agarwal AK, Guha G, Bhattacharya N, Chumbale PK, et al. Paraspinal Transposition Flap for Reconstruction of Sacral Soft Tissue Defects: A Series of 53 Cases from a Single Institute. *Asian Spine Journal*. 2014; 8: 309.

51. Heym B, Rimareix F, Lortat-Jacob A, Nicolas-Chanoine M. Bacteriological investigation of infected pressure ulcers in spinal cord-injured patients and impact on antibiotic therapy. *Spinal Cord*. 2004; 42: 230-234.

52. HSCIC, Health & Social Care Information Center. NHS Safety Thermometer: Patient Harms & Harm Free Care, April 2014–April 2015, official statistics. HSCIC, 2015. Available from <http://digital.nhs.uk/catalogue/PUB17488> [Accessed 27 December 2017].

53. Israel JS, Carlson AR, Bonneau LA, Kempton SJ, King TW, Bentz ML, et al. Reconstructive surgery and patients with spinal cord injury: Perioperative considerations for the plastic surgeon. *Journal of Plastic Surgery and Hand Surgery*. 2016; 50: 44-49.

54. Kim YH, Kim SW, Kim JT, Kim CY. Tensor Fascia Lata Flap Versus Tensor Fascia Lata Perforator-Based Island Flap for the Coverage of Extensive Trochanteric Pressure Sores. *Annals of Plastic Surgery*. 2013; 70: 684-690.

55. Larson DL, Machol JA, King DM. Vastus Lateralis Flap Reconstruction After Girdlestone Arthroplasty: Thirteen Consecutive Cases and Outcomes. *Annals of Plastic Surgery*. 2013; 71: 398-401.

56. Fort ML, Rome-Saulnier J, Lejeune F, Bellier-Waast F, Touchais S, Kiény P, et al. Sepsis of the hip due to pressure sore in spinal cord injured patients: advocacy for a one-stage surgical procedure. *Spinal Cord*. 2015; 53: 226-231.

57. Lechner A, Lahmann N, Neumann K, Blume-Peytavi U, Kottner J. Dry skin and pressure ulcer risk: A multi-center cross-sectional prevalence study in German hospitals and nursing homes. *International journal of nursing studies*. 2017; 73: 63-69.

58. Levine SM, Sinno S, Levine JP, Saadeh PB. Current Thoughts for the Prevention and Treatment of Pressure Ulcers: Using the Evidence to Determine Fact or Fiction. *Annals of Surgery*. 2013; 257: 603-608.

59. Lin CT, Ou KW, Chiao HY, Wang CY, Chou CY, et al. Inferior Gluteal Artery Perforator Flap for Sacral Pressure Ulcer Reconstruction: A Retrospective Case Study of 11 Patients. *Ostomy/wound management*. 2016; 62: 34-39.

60. Liu P, Shen W Q, Chen H L. The Incidence of Pressure Ulcers In The Emergency Department: A Metaanalysis. *Wounds*. 2017; 29: 14-19.

61. McCarthy JE, Rao VK. Systematic Review and Operative Technique of Recalcitrant Pressure Ulcers Using a Fillet Flap Technique. *Plastic and Reconstructive Surgery Global Open*. 2016; 4: e1001.

62. National Pressure Ulcer Advisory Panel, European Pressure Ulcer Advisory Panel And Pan Pacific Pressureinjury

Alliance. Prevention And Treatment Of Pressure Ulcers: Clinical Practice Guideline. Emily Haesler (Ed.). Cambridge Media: Osborne Park, Western Australia. 2014.

63. National Pressure Ulcer Advisory Panel press; 2016. Available from <https://www.npuap.org/national-pressure-ulcer-advisory-panel-npuap-announces-a-change-in-terminology-from-pressure-ulcer-to-pressure-injury-and-updates-the-stages-of-pressure-injury/> [Accessed at 28Dec.2017].

64. National Pressure Ulcer Advisory Panel. Pressure injury prevention points; 2016. Available from <http://www.npuap.org/wp-content/uploads/2016/04/Pressure-Injury-Prevention-Points-2016.pdf> [Accessed at 28Dec.2017].

65. Rubayi S, Gabbay J, Kruger E, Ruhge K. The Modified Girdlestone Procedure With Muscle Flap for Management of Pressure Ulcers and Heterotopic Ossification of the Hip Region in Spinal Injury Patients: A 15-Year Review With Long-term Follow-up. *Annals of Plastic Surgery*. 2016; 77: 645-652.

66. Sardo P M, Simoes C S, Alvarelhao J J, Simoes J F, Machado P A, et al. Analyses of Pressure Ulcer Incidence In Inpatient Setting In A Portuguese Hospital. *J Tissue Viability*. 2016; 25: 209-215.

67. Strauch B, Herman C K, Lee B T, Vasconez L O. *Grabb's Encyclopedia of Flaps: Upper Extremities, Torso, Pelvis And Lower Extremities*, Wolters Kluwer/Lippincott Williams & Wilkins. 2016.

68. Vincent P L, Pinatel B, Viard R, Comparin J P, Gir P, et al. Le lambeau de faisceau inférieur de muscle gluteus maximus dans la couverture des escarres ischiatiques : étude d'une série de 61 cas. *Annales de Chirurgie Plastique Esthétique*. 2016; 61: 845-852.

69. VUOLO, J. Improving patient education on pressure ulcers. *Wounds UK*. 2014; 10: 35-37.

70. Yang K, Graf A, Sanger J. Pressure ulcer reconstruction in patients with heterotopic ossification after spinal cord injury: A case series and review of literature. *Journal of plastic, reconstructive & aesthetic surgery: JPRAS*. 2017; 70: 518-528.

71. Yao C, Perrault D, Rubayi S. Complex Reconstructive Plastic Surgery for End Stage Pressure Ulcers in Spinal Cord Injury Patients. 2017.