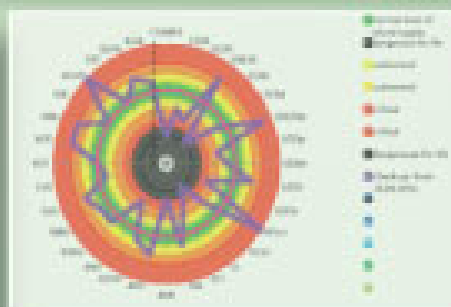
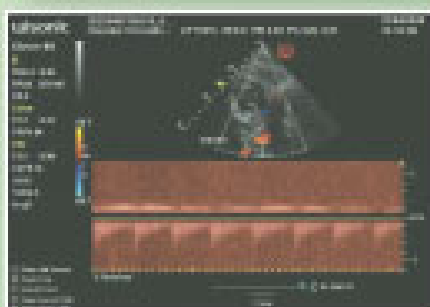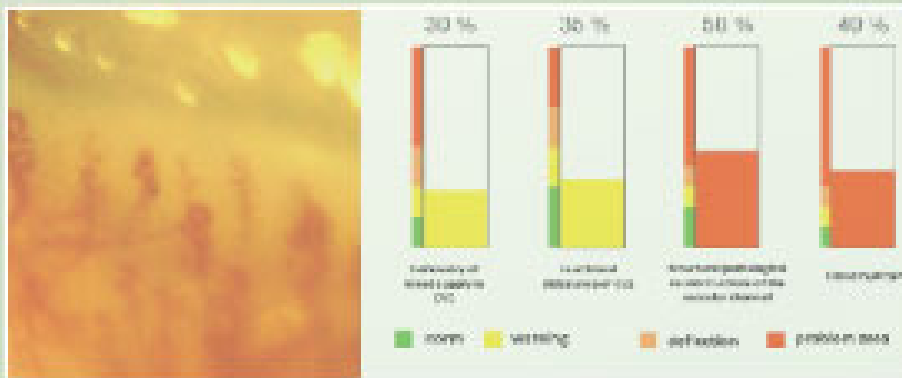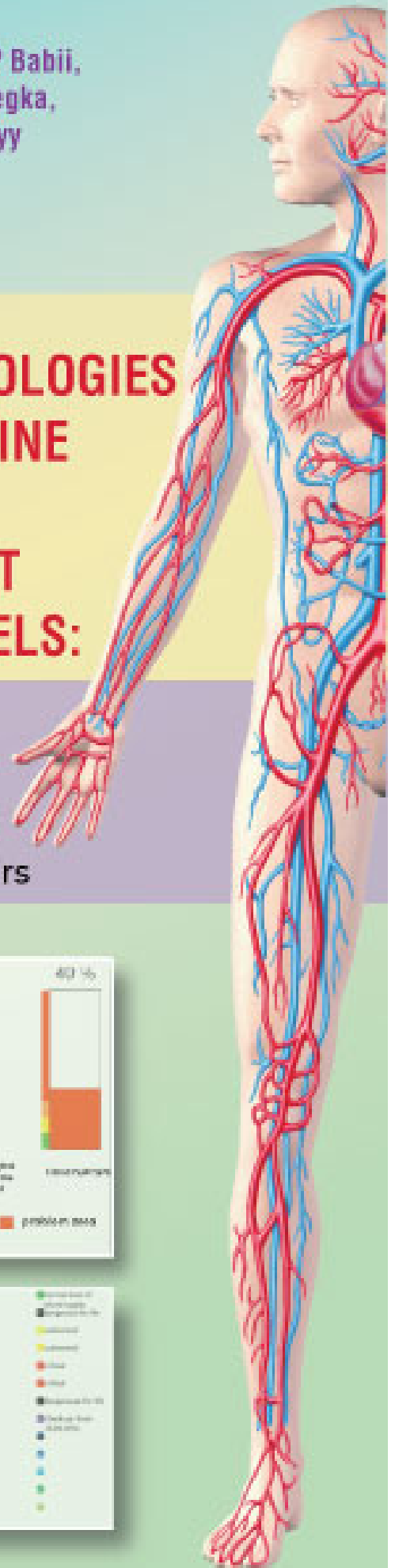




UB Lushchuk, VV Novytskyy, IP Babii,
 NG Lushchuk, LS Riabets, II Legka,
 OP Kolomytchuk, ViVi Novytskyy

UP-TO-DATE VIEW ON TECHNOLOGIES FOR EVIDENCE-BASED MEDICINE IN THE DIAGNOSIS OF THE CARDIOVASCULAR SYSTEM AT THE MACRO- AND MICROLEVELS:

the pros and cons in the diagnosis of arteries and veins, dysfunction and arteriovenous imbalance in the whole vascular system and in various regional vascular reservoirs



Up-To-Date View on Technologies for Evidence-Based Medicine in The Diagnosis of The Cardiovascular System At The Macro- And Microlevels: The Pros and Cons in The Diagnosis of Arteries and Veins, Dysfunction and Arteriovenous Imbalance In the Whole Vascular System and in Various Regional Vascular Reservoirs

Part 1

Ulyana B Lushchyk^{1,3,}; Viktor V Novytskyy¹; Ivanna I Legka¹; Liudmyla Riabets¹; Oleg P Kolomytchuk²; Igor P Babii³; Nadiya G Lushchyk⁴*

¹*VeritasResearch Center, Kyiv, Ukraine*

²*Institute of Mathematics of NAS of Ukraine, Kyiv, Ukraine*

³*Clinic of Vascular Innovations, Kyiv, Ukraine*

⁴*Medical center “Ukrainian medical innovations”, Ternopil, Ukraine*

**Correspondence to: Ulyana B Lushchyk, Veritas Research Center, Kyiv, Ukraine*

Email: u.lushchyk@gmail.com

Keywords: Hemodynamics; Neoangiogenesis; Vascular Technology; Angiomarkers; Capillaroscopy; Microcirculation; Evidence Medicine in Angiology; Arteriovenous Vascular Screening; Angiotherapy; Angiocorrection.

1. Introduction

It was the 20th year of the 21st century. CVD and oncopathology epidemics consistently maintained leadership in mortality and disability in the Earth's population. The emergence of Covid-19 has become a challenge for all civilization, complicating the course of chronic pathology, exacerbating the question of survival with additional provoking factors of systemic microangiopathopathy in lung tissue and vital organs. Therefore, in vivo visualization of pathological vascular processes and understanding their role in the formation of blood supply disorders in the entire cardiovascular system is becoming increasingly relevant and vital for the survival of world civilization in the 2020 pandemic [1].

who first drew attention to the vascular system, many centuries has passed. Technological progress of the 21st century - the Internet, digital technologies have made incredible - the information flow per capita has grown tenfold, the natural need for mobility has been replaced by the deep hypodynamia of the planet's population - practically constant sitting with a computer, notebook, I-pad, Smartphone etc. And only realization of the need to fight with hypodynamia and spend time for motor activity moved conscious people into fitness clubs.

In the age-related aspect cardiovascular disease has undergone a certain historical stage: they first debuted in older people and in the elderly - in the 60s-70s of the last century, in the 80s the CVD segment spread in 50-year-olds, in the early 90s - isolated cases of stroke in aged 30-40 and children, beginning of the 21st century - strokes in infants, children of preschool and early school. During the Covid-19 pandemic, another formidable factor arose - vascular coagulopathy with the risk of thrombosis and a high risk of death from thromboembolism in Covid-19 and in the early post-Covid-19 period.

The CVD statistics more often reflects 2 factors:

- 1) Sudden critical vascular states and lack of current prophylactic diagnostics of cardiovascular pathology at the preclinical stage of CVD development;
- 2) Effective treatment before the clinical picture of vascular decompensation - from sudden death to thromboembolism, heart attack, stroke, thrombosis, haemorrhage.

All these critical conditions are menacing for a person, whose clinical picture develops suddenly. However, such vascular disorders are formed for a long time, for some years. This is a golden period when it is necessary to detect CVD at the level of pre-disease and to actively eliminate pathological hemodynamic blocks and to carry out prophylactic treatment aimed at correcting altered hemodynamic parameters in arterial, venous and capillary streams in the integral cardiovascular system.

In this study we try to reveal the essence of cardiovascular and cerebrovascular disorders based on knowledge of macro-micro-angiology, applied hemodynamics and many hemodynamic indicators, which doctors usually pay no attention to.

Angiology as a science is relatively young; its age is about 35-40 years. However, thanks to the advanced visualizing technical potential for blood flow and digital vascular innovative technologies, the cardiovascular system has become available for research *in vivo* and non-invasive. Since the cardiovascular system is a dynamic system with rapidly changing blood flow parameters, the appearance of non-invasive dynamic diagnostic methods like ultrasound, capillaroscopy has enabled to *in vivo* underlying live intimate life processes and vascular functioning at the macro, peripheral, and at micro levels, to take a new look at the state of

CVS, its structure and variants of branching.

Current technical and technological level of the CVS research has allowed the medicine, biology and blood-related systems of the medical sciences, newly establish laws of blood circulation, fluids in the living organism, pathological or sanogeneous rearrangements in the arterial and venous channels on the macro- and microvascular levels, mathematically and experimentally to simulate various situations of angio-transformations in various diseases.

However, angiology as a science about the structure and function of the cardiovascular system as a complex system of vascular tubes, where flows the non-Newtonian fluid, or rather the suspension of the formed blood elements, in the majority of them puts doctors in a dead end, because it is another world that is difficult to understand. This requires profound knowledge of biophysics, rheology, angioarchitectonics, modelling of complex systems, etc.

But for a doctor it's important to get comprehensive and clear information to make the right decisions. As CVS is the most dynamic in the human body, static diagnostic methods are no longer sufficient to reflect dynamic changes. Therefore, *in vivo* imaging methods become the most informative for practical medicine, as they enable to see all segments of CVS live, observe and analyse dynamic changes in vascular reconstructions, structure transformations and dysfunction of individual segments of arteries and / or veins, regional reservoirs, assess the adequacy of drug effects on sanogenic or pathological reorganizations of CVS in the entire closed tube system - vascular blood supply [3].

Therefore, technology and methodology for obtaining information on the state of the cardiovascular system plays an extremely important role. In this study we decided to describe modern diagnostic methodologies in order to cover each method of diagnosis, its advantages and disadvantages and modern aspects of its application in diagnostic medicine and medical practice.

Ideally, today a medical practitioner requires:

1. *In-vivo* diagnostics of cardiovascular changes with analytical interpretation as a variant of applied angiology and clinical interpretation as an option for a correct understanding of the possible clinical signs of those or other dyshemias.

2. The maximum possible avoidance of subjectivity in the interpretation of the obtained images and confidence in the reliability. Specificity and the informativeness of the clinical findings obtained in response to a request for a CVS study.

3. Reliable and clear support during the CVD treatment process as a reliable instrumental monitoring of changes in CVS, to be sure of the correct treatment approach and the effectiveness of treatment for adequate sanogenic changes in CVS.

In process-management such approaches are called as combination of control instrumental studies of CVS at certain intervals during treatment, depending on the severity of the disbalance in CVS as a hemodynamically complex system.

Only the use of current control in the treatment process can allow predicting the outcome of treatment, and mathematical modelling of various possible hemodynamic alterations allows choosing the optimal route for vascular treatment - individual angiocorrection , angiotherapy and / or angioplasty [3].

Over the last 25 years we have been practicing such approach to CVD treatment, gradually developing applied angiology as a science of the possibility of sanogenic transformation in vessels' structure (angio-transformations) in the process of reversal reconstruction of vascular blood flow from pathology to norm.

The study deals with macro- and micro processes in the vascular system, which are deeply and inextricably connected with each other and are important for visualization and objectivation by means of medical technology and methodologies for obtaining images and information from the human body in static (image) and dynamic (video) modes.

Macro-Angiology studies macro processes in vascular system - a section of knowledge in applied angiology, which is associated with the structure of the main and peripheral vessels of the arterial and venous channels, their angio architectonics, arteriovenous interaction in the integral cardiovascular system as a model of the vascular blood flow, as well as changes in hemodynamic parameters at different CVD at different stages - from pre-disease (preclinical form of the disease signs, which is most often manifested in transformations at the level of the vascular system and is preceded a disease in 5-7 years) to critical vascular conditions. With the timely correction of vascular disorders at the stage of pre-disease and the restoration of the structural and functional status of the vascular system, the development of pathological angio-transformations can be stopped, thereby avoiding the possibility of the disease development [3].

2. Terminology

2.1. The logic of the approach to terminology in angiology to describe the processes of angiogenesis and vascularization

For easy perception of various terms in applied angiology, we propose physiological processes named with simple terms.

Physiological vascular processes, but stimulated by the organism in response to the problem (skin damage, bone fracture, etc.), angiogenesis and vascularization processes aimed at temporarily localizing the vascular network in the projection of wounds, ulcers, and

inflammation are presented with a prefix **neo + term**.

All **pathological processes** of angiogenesis, vascularization and pathological alterations in the vascular channel are presented with a prefix **patho + term**.

2.2. The most commonly used terms in angiology

Angiology is a science that studies the vascular bed in living organisms, its structure, functions, and associated changes in the vascular blood flow and in the rheological properties of the blood as suspensions of formed elements.

Macro-Micro-Angiology is a collection of generalized knowledge from various fields of science (anatomy and physiology, topographic anatomy of the vascular bed, theoretical and applied angiology, hemodynamics, fluid physics and suspensions, fluid mechanics and suspensions, blood rheology, etc.), structured and analytically synchronized in a model of vascular blood flow (hemoduct).

The term was proposed by Lushchyk U.B. and Novytsky V.V. in 2005 [3].




Figure 1: Schematic image of the vascular system as a bloodduct in the human body.

Macro-Micro-Angiology as a scientific concept is created to form doctors and medical staff, rehabilitation specialists with modern knowledge about features of the structure and function of the integral cardiovascular system as the basic model of the vascular blood flow for optimally convenient understanding of those complicated processes that occur in cardiovascular diseases in general and in regional vascular diseases in particular.

Macro-Micro-Angiology is closely connected with the applied application of the laws of hydro- and hemodynamics, blood rheology, clinical interpretation of the vascular visualization results, and the adaptation of life-time dynamic vascular visualization technologies *in vivo* for the reliable objectification of available vascular transformations, differentiation of pathology and norm in vascular disorders on expert-level, mathematical modeling of possible variants of

vascular reconstructions both of pathological, and compensatory, sanogenic nature.

Such approach to the application of knowledge on Macro-Micro-Angiology helps doctors better to understand the processes that occur in the vascular system and with the help of modern vascular innovative technologies as evidence-based tools, to find optimal solutions for diagnosis, mathematical and experimental modeling, monitoring and successful treatment of cardiovascular pathology.

For easy presentation of the material, we distinguish two sections of applied Macro-Micro-Angiology, which are fundamentally different in nature: *Macro-Angiology* and *Micro-Angiology*.

Micro-Angiology is a section of knowledge in applied angiology, which is associated with the structure of the microcirculatory channel - arterioles, capillaries, venules and their function at the microcirculatory level. The microcirculatory level is regarded as the microvascular level of functioning of the integral cardiovascular system as a model of vascular blood flow.

Macro-Angiology is a section of knowledge in applied angiology, which is related to the structure of the main and peripheral vessels of the arterial and venous channels, their angioarchitectonics, arteriovenous interaction in the integral cardiovascular system as a model of vascular blood flow, as well as changes in hemodynamic parameters with different CVDs in different stages - from a predisease to critical vascular conditions.

A theory of vascular blood flow (vascular hemoduct) - a theoretical model of the cardiovascular system with a prototype of the water pipeline, which allows to understand the integral nature of the cardiovascular system. Proposed by Lushchyk U.B. and Novytsky V.V. in 2005 [3].

Angio architectonics is a structure of the vascular tree and various types of its branches that are inherited and affect the change in the hemodynamic parameters of blood flow in the regional reservoirs and can be as risk factors for the development of vascular pathology at certain pathological calibers, branching types and branching angles of arteries and veins [4].

Angio-transformation is a change in the structure of the vascular bed at the micro- and macrolevels as a result of hemodynamic alterations, which leads to the formation of a pathological type of Angioarchitectonics with the inclusion of structurally modified capillaries by an “oncocapillary” pattern in the structurally and functionally distorted hemodynamics of the microcirculatory bed, the formation of intranatal immature capillary networks, and on macro level - tortuosity, loop formation at the peripheral and major level of arteries, venous phlebectasy, venular hyperemia and stasis [3].

Physiological and pathological angiogenesis

Angiogenesis (neoangiogenesis) is a physiological process of development of the vascular network, which is regarded as a variant of the norm in the process of formation of the vascular network in the foetus and as a physiological process controlled by the body for the development of new vessels and timely apoptosis of the old blood vessels in the process of vital activity [5,6,7,8].

Physiological angiogenesis is a process of formation of new blood vessels in an organ or tissue. Normally, the processes of angiogenesis occur in the body with moderate intensity and are activated only in the regeneration of damaged tissues, sewerage of blood clots, the elimination of foci of inflammation, the appearance of scar and similar processes of recovery, as well as in the growth and development of the organism [9,10,11,12].

Judah Folkman is a pioneer in the study of angiogenesis, who in 1970 published the theory of onco-angiogenesis [7,8].

Pathoneoangiogenesis is a pathological process of formation of new vessels and vascular networks uncontrolled by the organism and the impossibility of controlled destruction (apoptosis) of old vessels [9,13,14].

2.3. Physiological and Pathological Neovascularization

Physiological neovascularization is a physiological, controlled by the organism, process of development of vessels and the formation of the vascular bed locally at the injured area, or globally in the development of an embryo, growth of an infant.

Ophthalmology distinguishes corneal neovascularization and choroidal neovascularization [11,12].

Pathological neovascularization (pathoneovascularization) is a pathological vasodilatation in places where they should not normally occur, or the emergence of new vascular networks locally and their uncontrolled progressive growth [10,12,15,16,17].

2.4. Angiooncogenesis and pathoneoangio-oncogenesis

Onconeogenesis is a pathogenetic mechanism that triggers the formation of tumors with possible malignancy. Today ethiopathogenesis has not been studied enough [7,8,18,19].

Pathoangio-oncogenesis (neoangio-oncogenesis) is a pathological uncontrolled angio-transformation and neovascularization, which begins at the level of change in the regular loop-shaped structure of the capillaries into the abnormal – oncocapillary [19,20], forms arteriolar vascular networks that are not characteristic for patients in adolescence and

adulthood, and promotes the development of a tumor at the micro level [7,8]. Such networks develop progressively and uncontrollably, grow in volume, do not differentiate into peripheral and major vessels, but only arterioles and venules expand in volume, arteriolar-venular shunts for the formation of a vascular lace of a tumor and its growth with collateral type of blood supply [18,21,22,23]. The term “pathoneoangio-oncogenesis” is proposed by U. B. Lushchyk in 2017.

We intentionally use a term **pathoneoangio-oncogenesis**, but not oncoangiogenesis, because we are convinced that the vascular channel and the uncontrolled process of vascularization is a basis for tumor development and the background for the risk of tumor developing.

Pathoneoangio-oncogenesis as a manifestation of pathological uncontrolled angiogenesis with the formation of the vascular network for tumor growth. In tumor tissues, especially in tissues of malignant tumors, angiogenesis proceeds constantly and very intensively. This is probably one of the causes for the rapid growth of malignant tumors, since they are very well supplied with blood and receive far more nutrients per unit mass of tumor than normal tissue, thus robbing healthy tissues of the body. In addition, enhanced tumor angiogenesis is one of the mechanisms of its rapid metastasis, since tumor cells have the ability to create metastasis along the blood vessels (along the walls) or spread around the body with blood flow [7].

On the other hand, the anaerobic type of the metabolism [7,8,24] in the tumor and the extremely rapid division of atypical cells receive additional “favourable” conditions for the progression of the pathology under conditions of hypoxic-ischemic background for pathoneoangio-oncogenesis in the stage of predisease. Recently there were publications on the affinity of vascular and oncopathology [25], diabetes and oncopathology [26]. Therefore, in our study, we also tried to make certain correlations between cardiovascular disorders and pathoneo-angiogenesis.

In patients with breast cancer, we observed the presence of a modified structure of the capillaries in the nail bed of fingers homolaterally irrelevant lesion of the mammary gland.

2.5. Vascular innovations and vascular innovative technologies

Vascular innovations are up-to-date innovative approaches to diagnosis, modeling, process and risk management in the treatment of CVD. Vascular innovations enable the creation of unique diagnostic and monitoring tools for medical practice assistance, since they combine technological complexes for obtaining images and information, as well as analytical IT technologies for image processing, clinical interpretation of received images, with the formation of an expert-level automated conclusion for minimization time for a clinician to obtain detailed, reliable information and avoiding subjective inferences with minimal

knowledge of the field of applied hydrohemodynamics, Macro-Micro-Angiology, rheology and clinical angiology [27].

Vascular innovative technologies is a set of modern vascular technologies that are complex technological sets and combine technical, programmatic, analytical, archival and methodical blocks for the purpose of obtaining images of the vascular bed at different levels of the vascular blood flow, their calculations, analytical processing and the formation of expert-level with a clinical interpretation of possible manifestations of vascular dyschemia. Vascular innovative technologies minimize the work of a physician during the processing of primary data to obtain an automated conclusion and a clinical interpretation of the existing pathology in an understandable format [27].

2.6. New terms in the treatment of vascular disorders –angiocorrection and angiotherapy

With the advent of vascular innovative technologies - analytical technologies to assess the change of many hemodynamic parameters (at least 35-50 parameters of blood flow evaluation in arterial and venous vascular beds at macro- and microlevels), in contrast to the estimation of generally accepted parameters of blood flow - volume and linear velocities of blood flow, vascular diameter, there is a need for correction of these parameters by medicinal means [3,28,29].

Therefore, new terms like angioplasty and angiotherapy have been gradually introduced into the life as a basis for restoring the permeability of the bloodstream and the possibility of adequate blood supply to the organ [29].

Angiotherapy and angiocorrection are proposed by Lushchyk U.B. in 2004 and 2010 [29,30].

In turn, over time, there was a need to differentiate the medicinal process of restoring only hemodynamic parameters of the blood flow in the vascular bed - angiocorrection and restoring the level of adequate blood supply for optimal organ function - angiotherapy.

Angiocorrection [3,29,31] is a process of correcting hemodynamic parameters at the level of the main, peripheral and microcirculatory beds to restore adequate, physiological blood supply for an organ or system that is responsible for the structure and hemodynamic parameters of the age pattern of the arteriovenous balance and the corresponding structure of the regional angioarchitectonics in one or another local vascular reservoir by drug or operational means.

Angiotherapy [3,19,29,31] is a process of restoring a deficient blood supply for an organ and / or organism in certain regional vascular reservoirs to the level of the age-old physiological norm by applying a medicinal sanogenic effect on the logical redistribution of blood volume in the vascular system in the organism, formation of blood supply adequate

to the needs of the organism and the elimination of ischemic-hypoxic states at the level of microcirculation locally in a separate organ and in the organism as a whole, avoiding formation and use of the effect of the stealing syndrome at the interregional vascular level.

3. Diagnostic methods of the vascular system in applied Macro-Micro-Angiology

3.1. Historical viewpoint of the diagnostic methods of the human vascular system *in vitro* and *in vivo*

For a long time, mankind has been searching for ways for objectivating of structures and functions of the organism's vascular system. Claudio Galen [1] established it and he was actually the first who assigned the presence of net of tubes for blood flow in the human organism and started the pathomorphological investigations of the blood circulation system. Further the pathomorphological diagnostics was supplemented by pathohistological investigations in order to study structures of small vessels and structure of the vascular walls [32,33].

Despite of the high reliability of pathomorphological investigations the scientific search is gradually displaced towards the intravital objectivating of vascular problems. Different biophysical diagnostic effects are used in Macro-Micro-Angiology for this purpose such as electrophysiological, laser, optical, radionuclide, x-ray and ultrasound.

In total, methods of the intravital investigation of the vascular system can be arranged in the following directions of the Macro-Micro-Angiology:

- Assessment of the structure of the heart and vessels in whole closed cardiovascular system as a model of vascular blood ductus (hemoductus);
- Assessment of the functional activity of the heart as a pump for the moving of blood in whole vascular blood ductus;
- Assessment of vessels' functions as channels for the blood moving and blood supply;
- Assessment of the perfusion in organs and tissues in the norm and at the pathologies conditions;
- Assessment of different types of the intravascular pressure in the vascular system;
- Assessment of the hemorheology of the blood, which are different from liquid rheology.

Today many instrumental research methods are used for differentiation of the vascular

pathology. They are divided into non-invasive (not changing the integrity of a dermal integument of a patient) and invasive (provides piercing of the skin with further necessary manipulations).

Modern trend in development of non-invasive diagnosing methods is in the gradual reducing of application of the Roentgen generating and radiological methods (as a static images of vascular system) comparing with the increasing of number of methods based on the ultrasound and biophysical approaches (as a dynamical images of vascular system).

The essential advantage of diagnostic non-invasive methods is in possibility of their harmless secondary application in order to receive structural and functional changes in dynamics in the area of injury and adjacent sections. And it becomes possible to apply functional loads and performance of pharmacological tests that is extremely important for selection of the treating tactics.

Nowadays there is positive dynamics of reducing the number of invasive methods in comparison with application of non-invasive one under condition of increasing of their self-descriptiveness.

On the other hand, diagnostic methods of the vascular system can be grouped in the following way concerning the nature of obtaining the information for Macro-Micro-Angiology:

- Direct methods of visualization – represent the visual information about structural changes connected with the pathological process;
- Indirect – represent information in the form of digital values of certain coefficients (parameters) known for researcher or in the form of graphs;
- Combined – objectivates structural and functional changes, combine static and dynamical images from the vascular system's conditions [3,28].

Problems related with adequate assessment of the brain vascular system conditions are closely indissolubly connected with assessment of the functional condition of the whole hemodynamic system both in the systemic and in the regional levels.

Global research of the vascular pathology has been going on by means on the application of the various modern diagnostic methods and analytical processing of the results obtained from the research for the last time despite of the possibility of the local examination of the pathology in a certain vessel.

An arsenal of the modern diagnostic equipment is rather manifold and is presented by such methods of objectivating the vascular pathology, which were tested on the practice, as

follows:

- Rheography (REG);
- Sphygmography;
- EchoCG;
- Optical and smart capillaroscopy;
- Radionuclide diagnostics;
- Angiography;
- Ultrasound diagnosing methods (colored angioscanning and dopplerography);
- Laser dopplerography;
- CT;
- MRI in the vascular mode (MRA);
- Perfusion MRI;
- Color-coding of the grey-scaled scanned MRA and USD- images etc.

Let's describe in brief different methods of diagnostics, paying attention to their advantages and disadvantages in the applied Macro-Micro-Angiology.

We believe that these information will be useful both for all doctors and medical specialist for the better understanding of applied Macro-Micro-Angiologie's technical potential.

3.2. Rheography

(from Greek rheo – flow, grapheo – describe)

Indirect non-invasive dynamic method.

The method is based on the biophysical principle of changes' registration from the electric resistance of tissues when the electric current of high frequency (20-40 kHz) and weak force (20 mA) through the examined area with the graphic registration of the pulsate oscillations of the complex electric resistance.

Living tissue is considered as an electric conductor that has the ionic conductance. Fluctuations of the electric resistance indirectly reflect changes of the velocity and volume of blood that flows in vessels. Pulsate fluctuations of blood flow are registered in the form of

curves of the synchronous fluctuations of the electric resistance [34,35].

The investigating object – disorder of the electric conductivity of an organ on the background of changes in its blood filling.

Level of examination of the vascular system – measuring the value of the regional hemodynamics and peripheric circulation due to the analysis of rheograms by means of assessment of the pulsate blood filling of various vascular reservoirs, arterial and venous tonus.

With the help of REG method it is possible to:

- assess the level of the regional hemodynamics and examine the peripheric circulation;
- differentiate the complete and partial occlusion of arteries;
- determine the stroke and minute volume of the heart (rheocardiography);
- study the condition of the small circle of the blood circulation with different injuries of the valve apparatus of the heart;
- study circulation in the brain;
- examine the internal hepatic hemodynamics and quantitatively assess the rheograms of the liver using number of indexes (rheohepatography).

Data processing – quantitative – qualitative (graphical).

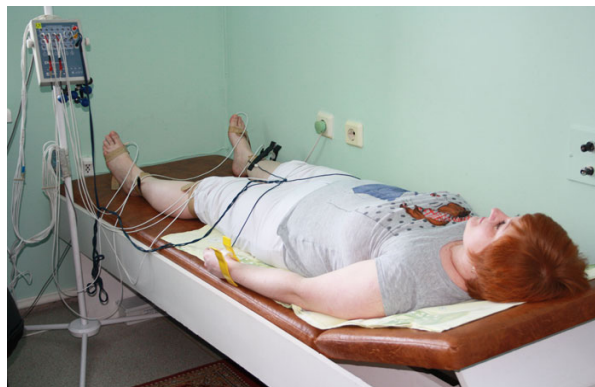

Figure 2: Rheograph (<http://www.mederbis.com.ua/node/107>).

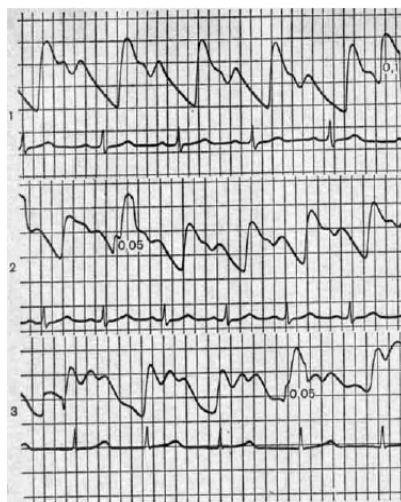


Figure 3: Rheovasogram. (<https://prof-med.info/funktsionalnye-issledovaniya/59-reovazografiya>)

Rheographic curve reflects hemodynamic fluctuations that arise in organs and tissues during the heart contractions and named as a rheovasogram.

The rheovasogram is an integral volumetric curve of all arteries and veins from the examined area of the body or the whole organ (for example – liver, brain, lungs, heart, limbs).

Advantages of the method.

1. Long and continuous registration even of the slightest changes of circulation without disturbances of the physiological conditions of the examined area.
2. Non-invasive, long hemodynamic observations.
3. Usage of the functional tests (with hyperventilation, with hypercapnia, with Nitro-glycerine, with nicotine acid) enables to detect disorders in circulation, differentiate functional vascular changes from organic injuries of brain vessels.
4. Wide potential for hemodynamic investigation of vitally important organs and systems, modern diagnostics of circulation disorders and prescription of the rational therapy.
5. The rheovasography is able to reflect condition of whole regional vascular reservoir (for example – cerebral regional reservoir - rheoencephalography, liver regional reservoir–rheohepatothography, heart regional reservoir – rheocardiography, lung regional reservoir – rheopulmography).
6. General conclusions about the arterial and venous links of the vascular system, which circulation function is reflected in one curve.

Disadvantages of the method.

1. Unspecific features for different diseases.

2. Circulation function is reflected in one curve: it's impossible to differentiate arterial and venous problems separately.
3. Thus, rheovasography is unable to observe etiopathogenesis of vascular disorders, search domination pathological segment in vascular dysshemia - like arterial or venous.
4. Resolving power of the method is limited by the level of diagnostics of decreasing of blood filling in the vascular reservoir but not of the segment of a certain vessel.
5. This method might belong to the screening vascular methods and need clinical interpretation database for medical practice.

Rheovasogram's hemodynamic parameters:

Different amplitude and time characteristics are used for analysis of the rheographic curves. They pay attention to the curve's form because rheographic curves are deformed under the pathology of the vascular system.

In more details we describe peculiar features of the interpretation of the graphic image because the rheogram is extremely representative for assessment of many hemodynamic parameters and further realization of processes of the vascular system's functioning.

On the volumetric rheograms, which characterize changes of blood filling in the examined organ or site of the tissue, the major, or systolic, curve is allocated (it corresponds to the anacrotic phase of the pulsating wave) that rhythmically arises after every systole and reflects the inflow of the arterial blood to the examined organ or tissue. The point **a** of the curve corresponds to the start of the fast blood inflow into the examined organ, the point **x** – to the maximum pick of the differentiated curve and characterizes the maximum velocity of the fast filling (V_{\max} , Ohm/s).

At the absence of the differentiated rheogram the end of the period of the fast blood filling and period of the slow blood filling are determined by the graphical method.

The size of the period, which includes the interval from the end point of the fast blood filling up to the end of the systole, can be determined by the method [7] that enables to state graphically the end of the systole. It is required to draw a straight line from the lower end. The place of separation of the inflection line by the rheographic curve corresponds to the end of the systole; the indexes of the time relations are the following: duration of the anacrotic phase of the rheographic curve that is determined from the beginning of the curve to the moment of stating of the maximum amplitude; duration of the catacrotic phase of the rheographic curve that is measured by the time interval from the top of the rheogram up to its end.

Generally, this method of Rheovasography is useful for rapid screening of some regional

reservoir of the vascular system.

In case of pathological rheovasogram it is strongly recommend more deeply check-up of whole vascular system at the all levels: heart, main and peripheral arteries and veins, microcirculation level with the aim of searching all pathological features and pathologically changed segments.

Only in such way it is possible to understand whole vascular disorders as a cause of vascular dyschemia and manage it.

3.3. Sphygmography

(from Greek sfigmo – pulse, grapheo – describe)

Sphygmography is a mechanocardiographic method of the dynamic recording in the form of graphs and analysis of the arterial pulse that is caused by the pulsation of the arterial wall during moving of the volumetric stroke of blood along the arterial link [36].

With every systole the pressure in arteries is increasing and there is an increase of the transversal section of the vessel, then the vessel returns into the initial position. Whole this cycle is called as the arterial pulse and its recording in dynamics – sphygogram.



Figure 4: Sphygmograph(<http://www.tryphonov.ru/tryphonov2/terms2/spgrap.htm>)

The method is based on the application of the piezoelectric sensors.

The investigation object – graphical representation of characteristics of the arterial pulse in dynamics, determination of the time and velocity of the pulsating wave, which is spreading from heart along the main and peripheral limb's arteries of the elastic and muscular types.

Level of the vascular system investigation – there are distinguished sphygmograms of the central pulse (major arteries) and peripheric pulse (smaller arterial vessels).

Data processing – quantitative – qualitative (graphical).

Advantages of the method.

1. Long and continuous registration of the slightest changes in the velocity of the pulsating wave spreading along arteries.
2. Non-invasiveness, possibility of observations in dynamics.
3. Easy investigating method.
4. Based on comparison between right and left side limbs' parameters. Asymmetry more than 30% is evidential.

Disadvantages of the method.

1. Less application in practical medicine because requires the profound knowledge about peculiar features of the pulsating wave spreading..
2. It is more analytic than diagnostic method.
3. This method also might belong to the screening vascular methods and need clinical interpretation database for medical practice.

Sphygmogram's hemodynamic parameters:

The synchronous registration with ECG and PCG the sphygmogram enables to analyse phases of the heart cycle separately for the right and left ventricles. In most cases simultaneously they put two and more piezosensors or make the synchronous recording from the electro- and phonocardiograms. Graphics of curves, which are registered from the major and peripheric vessels, is not similar.

Sphygmogram is similar to rheovasogram and contains anacrote, incisure, dicroticrise and catacrote.

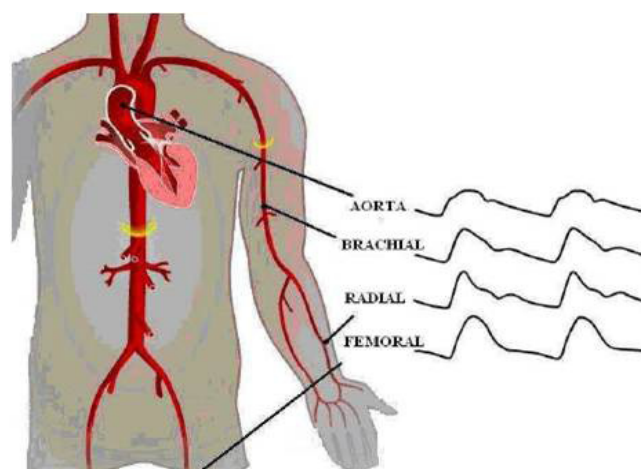
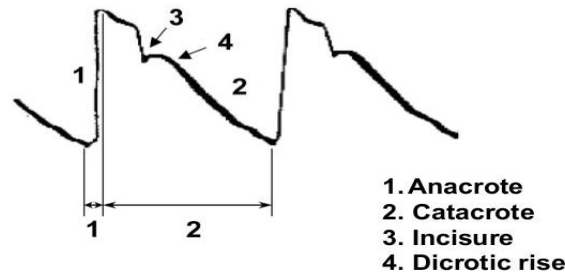


Figure 5: Arterial pulse wave propagation. (https://www.researchgate.net/publication/224370836_Automatic_Brachial_Ankle_Pulse_Wave_Velocity_Measurements_for_Vascular_Damage_Assessments/figures?lo=1)



Sphygmogram

Figure 6: Sphygmogram (https://www.slideshare.net/E_neutron/external-manifestations-of-cardiac-activity-regulation-of-heart-work)

3.4. Photoplethysmography in assessment of elastic features and reactivity of peripheric arteries

For the last decade the role of endothelium has been paid more attention regarding increasing of cardiovascular diseases and methods are developing for detecting its dysfunction.

The endothelium secretes substances (vasodilatating and vasopressor), the balance between them regulates the vascular tonus. In the concept of the cardiovascular continuum the endothelium dysfunction is an initiating factor of the hypertonic and ischemic heart disease. Its essence is in the fact that under the long influence of the number of factors (risk CVD factors) on the endothelium its reaction to the stimuli, which caused dilatation, appears to be insufficient or even vasopressed. The test with reactive hyperaemia is used as the endothelium-dependable stimulus. The post-occlusive acceleration of the blood flow causes the increasing of the strain of the shift on the endothelium of the artery in the brachium and forearm. This strain of the shift is a stimulus for the endothelium to the production of the vasodilatating factors that is followed by increasing of the diameter of the examined arteries. Assessment of the blood flow and diameter of the brachial artery is made with the help of the ultrasound dopplerography by the method proposed by Celermajer D., with the location of arteries above or below the area of occlusion. Laser doppler flowmetry is another method of determination of the vasomotor function of the endothelium that enables to assess the degree of increasing of the microcirculation during the test with the reactive hyperaemia [37].

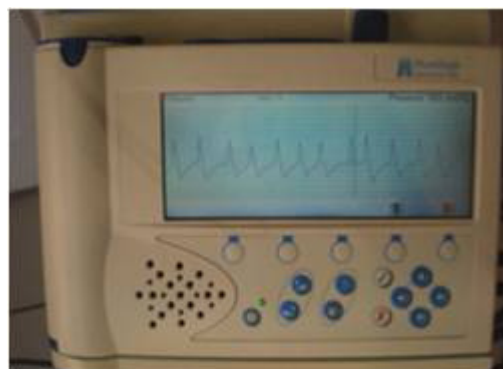

Figure 7: Photoplethysmography. (<http://www.footache.co.uk/specialised-treatment/photoplethysmography>)

Besides the endothelium dysfunction the stiffness of large elastic arteries is paid more attention as the prognostic factor of development of the cardiovascular complications and independent factor of the mortality from the cardiovascular diseases. The elasticity of arteries is assessed by the increasing of the velocity of spreading of the pulsating wave.

A planimetric analysis of the peripheric pulsating wave can be another method for analysis of the transfer function of arteries with the help of the digital photoplethysmography (PPG) [38,39,40]. The aim of the investigation is to assess potential of PPG for determination of the vasomotor function of the endothelium and elastic characteristics of arteries. For this purpose, their changes are studied during the test with the reactive hyperaemia.

For this purpose the initial PPG is registered then the blood pressure cuff, where the pressure is made above the systolic one on 30 mm/Hg, is put on the same extremity, where the registration of PPG is performed (ipsilateral). The pressure is kept for 5 minutes and then sharply reduced. The recording of PPG is made continuously during 3 minutes. Parameters are estimated in the first 30 seconds on the first and second seconds after ischemia. The frequency of the cardiac contractions (FCC), arterial pressure is estimated: systolic (APs), diastolic (APd), pulsate (AP). Besides the test with the reactive hyperaemia (endothelium-dependable stimulus), the test with Nitroglycerine is made (NTG). NTG is a donator of the oxide of the nitrogen and is the endothelium-independent stimulus. Parameters of PPG (FCC, A1, A2, T etc.) are compared with the background and after application of NTG on the third minute when its influence is the maximum.

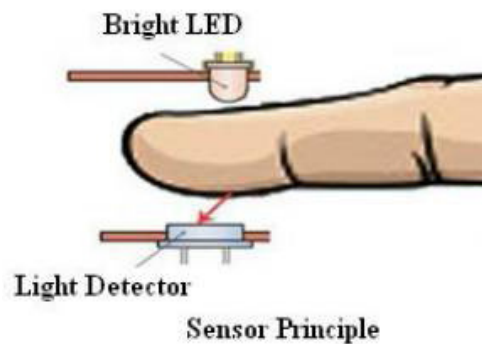


Figure 8: Principle of Photoplethysmography(https://www.researchgate.net/publication/263122223_Continues_Blood_Pressure_Measurement_and_Data_Logging_Device_with_SMS_Alert/figures?lo=1)

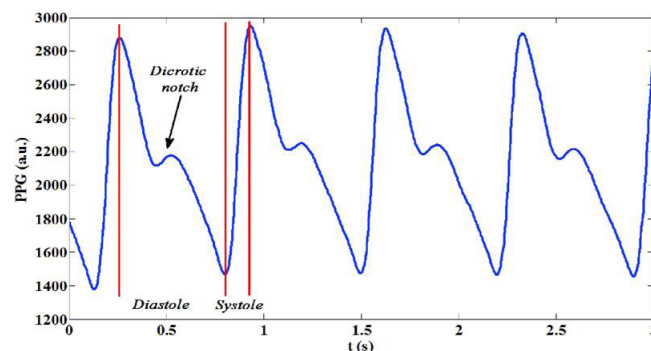


Figure 9: Components of PPG signal waveform. (https://www.researchgate.net/publication/277027133_Human_photoplethysmogram_New_insight_into_chaotic_characteristics/figures?lo=1&utm_source=google&utm_medium=organic).

3.5. Echoencephalography (EchoEG)

Indirect non-invasive dynamic method.

The method is based on the application of the one-dimensional ultrasound radiation [41].

The investigating object – ventricular brain system.

Level of the vascular system examination – shift of the median structures of the brain (B-echo), condition of the ventricular system, presence of the hydrocephalus.

Data processing – quantitative – qualitative (graphical).

Advantages of the method.

1. Screening non-invasive method for the urgent diagnostic of disorders in the liquor dynamic balance.
2. This method can detect the abnormal pulsation in brain arteries. Nowadays this is not actual due to other methods with better options.

Disadvantages of the method.

1. Less informative on the background of the up-to-date neurovisualizing methods.

Echoencephalography (EchoEG) is an ultrasound method for intracranial structures.

The basis for the existence of the method is the ability of brain tissues to absorb and reflect ultrasound vibrations.

The method may be useful in the diagnosis of brain tumors, craniocerebral traumas, vascular and inflammatory diseases of the brain, as well as hydrocephalus as screening and can be used in emergency medicine and in the practice of primary care at the pre-hospital stage.

Further we describe in brief some positive moments of application of certain technologies that were tested by time and remain up-to-date and progressive.

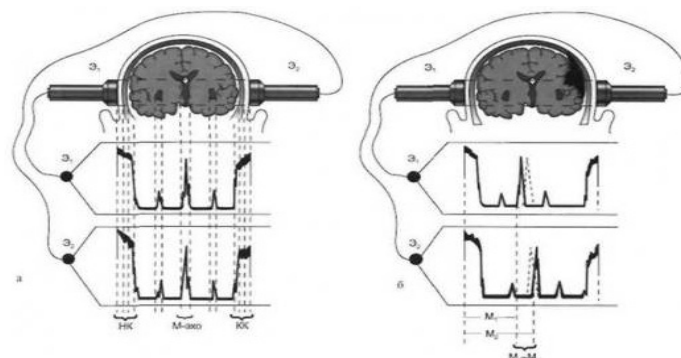


Figure 10: Echoencephalography. (<http://moydiagnos.ru/issledovaniya/ehoentsefalografiya.html>).

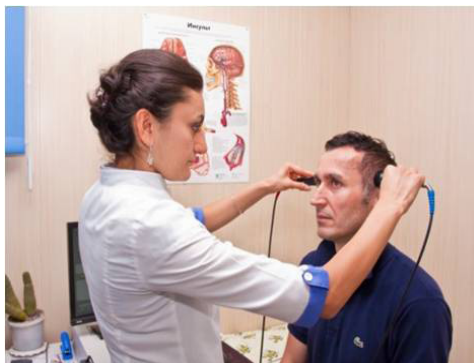

Figure 11: Echoencephalography. (<https://astana.all.biz/eho-eg-s42420>).

3.6. Capillaroscopy

Historically, capillaroscopy as a non-invasive visualization of the microcirculation in the nail bed of fingers was proposed to practical medicine in the 1960's. However, it was used in isolated medical institutions that managed to find certain algorithms for interpreting these images [3,42,43,44].

With digital technology in the 90s of the 20th century, capillaroscopy as an optical method of visualizing capillaries is undergoing a renaissance and is transformed into a technically updated digital capillaroscopy with the ability to group image visualization on the monitor and its archiving in static (image) and dynamic (video) modes [3,28,44,45,46].

Capillaroscopy has the important place in the continuous chain of investigations of the pathohemodynamic link in the vascular system: heart- arteries – capillaries – veins- heart. The incompleteness of the cycle of research of the vascular blood supply for the brain became the determinative factor both in renascence and modernization of the unmerited forgotten method and in the development of new approaches to interpretation of images.



Figure 12: A model of an old capillary scanner (the 60's of the 20th century) with the first attempt to take video, which became a prototype for digital optical capillaroscopy.



Figure 13: Capillaroscope. (<http://angio-veritas.com/technologies/tehnolohiya-sudynnoho-skryninhu/?lang=en>).

Direct non-invasive dynamic method.

The method is based on application of the optic visualization method with usage of modern computer technologies for reflection of the obtained image on a monitor's screen.

The investigating object – stream of erythrocytes in the volume of the tissue.

Level of the vascular system examination – visualization of the blood perfusion on the microcirculatory level.

Dataprocessing – direct visualization with quantitative – qualitative analysis.

We have constructed a smart capillaroscope on the basis of our own clinic for the microcirculation investigations. It enables to enlarge the obtained images in 100, 150, 200 times in order to diagnose adequately the condition of the microcirculation in the organism, to prognosticate the course of a disease, quantitative and qualitative characteristics of efficiency of the vasoactive therapy, possibility of observation of unique microcirculative changes for predicting the sub- and decompensatory conditions of patients.

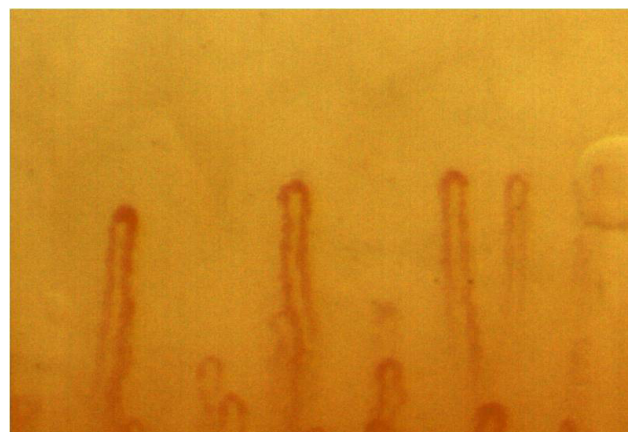


Figure 14: Capillaroscopic image in a healthy human. Classical loop.

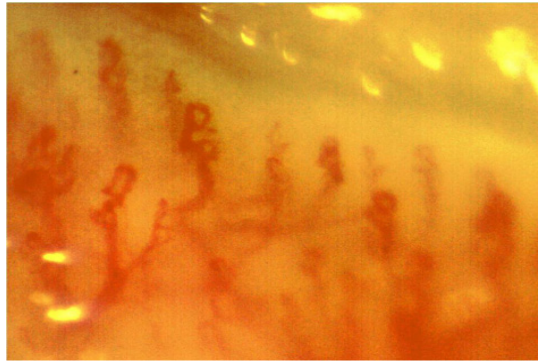

Figure 15: Capillaroscopic image. Atypical form of the capillaries.

Advantages of the method.

1. Easy in work, non-invasive, high quality of visualization both of capillaries and the velocity of the circulating blood, possibility of archiving both of separate static images and video files for processing images in order to increasing the contrasts and receiving of the maximally useful information.
2. Enables to increase significantly the resolution of the capillaroscopic picture.
3. The image on the monitor enables to perform the consultation of some doctors with different professions avoiding subjectivization in interpretation of the obtained images.
4. Enables to perform the archiving images, compare them in the dynamics of treatment and the disease's course.
5. Microcirculation visualization on a screen appears to be the factor of the increased trust to a doctor by a patient, realizing necessity of treatment for elimination of the detected disorders.
6. Unlike digital parameters of assessment of the level of microcirculation in the volume unit, the qualitative picture of visualization of disorders in blood circulation is the most informative and reliable.
7. Development of the method of the computed analysis of the obtained capillaroscopic images enables to formulate the algorithm for the quantitative – qualitative analysis of the microcirculation level that further will improve quality of objectivation of the detected disorders.
8. The information about the capillary structure (structure, caliber, form and tortuosity of a certain capillary, presence of the capillary net, angioarchitectonics of the microcirculatory bed) and functions of the microcirculatory link of the blood supply (circulation rate, character of circulation, presence of the sludge – phenomenon).
9. Theoretical possibility of obtaining the digital processing of the volumetric perfusion. The formula is used where the velocity of the blood flow in a capillary is multiplied on the volume

of the capillary and on the density of the capillaries in the unit area. This enables to receive much more all-round information than usage of the indirect method of the laser doppler flowmetry.

10 .Possibility of performance of functional loads, comparison in dynamics.

Disadvantages of the method, which promotes creation of a new technology for vascular screening.

Without computer monitoring the optic capillaroscopy used to be significantly limited in possibility of the clinical interpretation (only one researcher can see one and the same picture in the real time in the radiographic cone of the capillaroscope and interpret subjectively it).

Therefore, capillaroscopy was not widely recognized in the 20th century, and only a few physicians understood its essence and independently found algorithms for its application [41].

Renaissance of capillaroscopy: from smart optic capillaroscopy into vascular screening technology (VST) for 1997-2017 period

The greatest breakthrough in the development of digital optical capillaroscopy was made by Ukrainian scientists U.B. Lushchyk and V.V. Novytsky [3,44,46,47], which since 1997 became interested in this method and began to study it clinically and technically improve it.

For 20 years, this technical device has undergone a number of modifications and modernization with the use of modern lenses and the creation of fundamentally new lighting schemes and optical image focusing, enhancement of optical and digital enhancement, image resolution enhancement [44, 45, 46, 47].

The technology ideologist – An Academician of the Academy of Technological Sciences of Ukraine, Ulyana Lushchyk, Prof., MD [45, 46, 47].

The main idea of the renaissance project of capillary method was to develop the method from visualization of the capillary to a technology for assessment of a vascular pathology and the risk prevention.

Each new version provides improved resolution and image quality, methodology improvement for application in diagnostic and treatment process.

1st version of the device and the example of capillary images, 1999.
Disadvantages: old optics, poor visualization, low increase, a lot of artifacts.

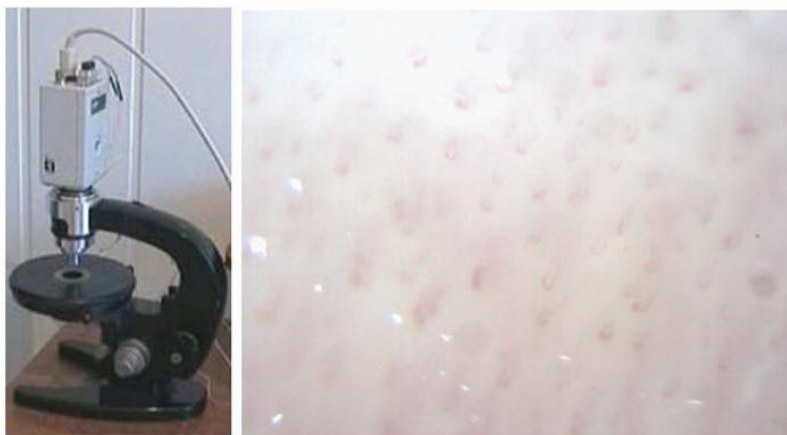

Figure 16: 1st version of the device and the example of capillary images, 1999.

2nd version of the capillaroscope, 2003.

Improved contrast, the quality of visualization, the ability to increase up to 100 times, the ability to observe the speed of blood flow.

Disadvantages: unclear and unstable images do not allow counting capillary parameters.

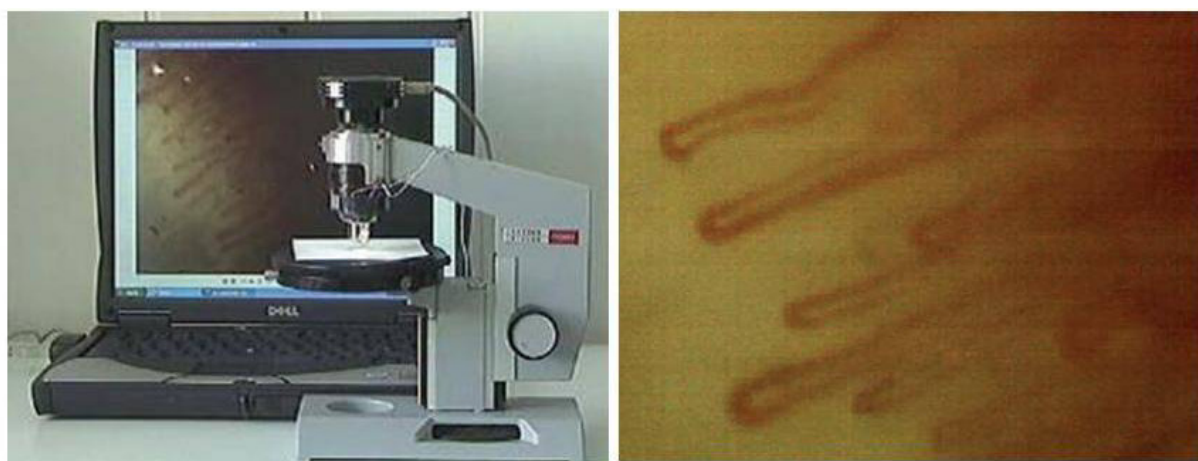

Figure 17: 2nd version of the capillaroscope, 2003.

3rd version of the device, 2006.

Improved clarity of visualization of capillaroscopic images, the ability to increase has risen to 300. The obtained images enabled to calculate large number of microcirculation parameters in the semi-automatic mode and managed to gain experience to create a vascular screening technology.

Disadvantages: currently this version is obsolete.



Figure 18: 3rd version of the device, 2006.




Figure 19: 4th version (2013).

4th version (2013) of smart optic capillaroscopy enabled to:

- significantly improve the quality and clarity at different magnifications;
- increase the dynamic range of the optical zoom from 50 to 400 times;
- apply the automatic processing of static images;
- create a series of instruments and subtechnologies for different specialists – angio- and cardiologists, oncologists, psychoneurologists, cardiologists, neonatologists and pediatricians, intensive care and rehabilitation specialists, endocrinologists;
- apply this technology due to non-contact technique in dentistry (periodontics), neurosurgery and gynecology;
- predict vascular risk in insurance medicine, health resorts, pharmaceutical business.

5-th version (2015) of smart optic capillaroscopy has received modern new design.




Figure 20: Screening of capillaries with vascular screening technology (<http://angio-veritas.com/technologies/tehnolohiya-sudynnoho-skryninhu/video-rolyk-pro-tss/?lang=en>)

Also, the optical system and the system of a uniform illumination have been improved. Improved image quality and the ability to smoothly change the optical zoom from 50 to 300 with out displacement of the studied area.

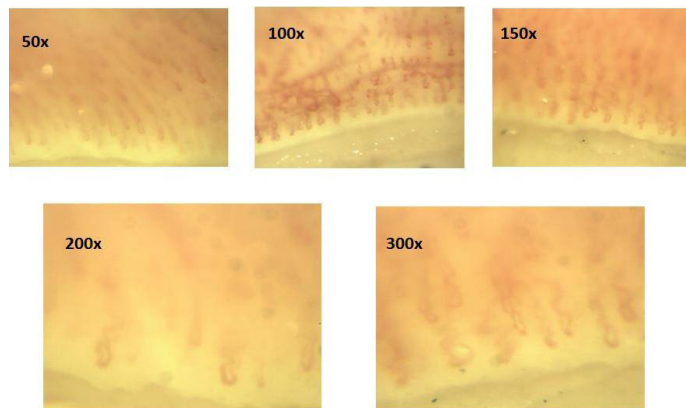


Figure 21: Capillary image enlargement.

Archiving capillaroscopic images and video, and ability to image processing resulted for software developing for database and the ability to assess the necessary parameters for clinical interpretation.

Examples of program decoding

Process-management in vascular screening: 4 steps for 10 minutes

1. Obtaining pictures and saving in database.

2. Initial data processing




Figure 22: Data processing

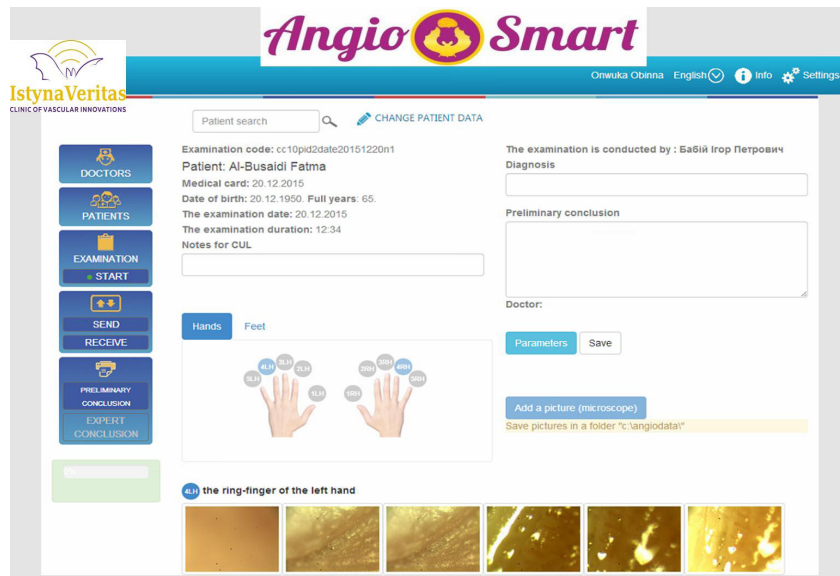

Figure 23: Data processing

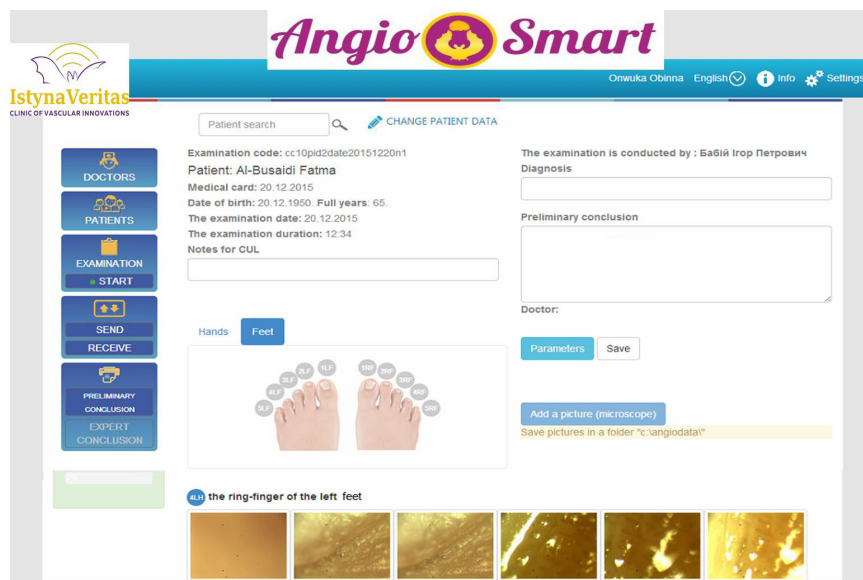

Figure 24: Data processing

The interface of the Vascular screening technology shows the easy use of the technology for the understanding for a doctor or a patient during examination and image results. This technology can work in English, Ukrainian, Russian and Arabic languages

3. Program decoding: analytical processing with automatic clinical interpretation

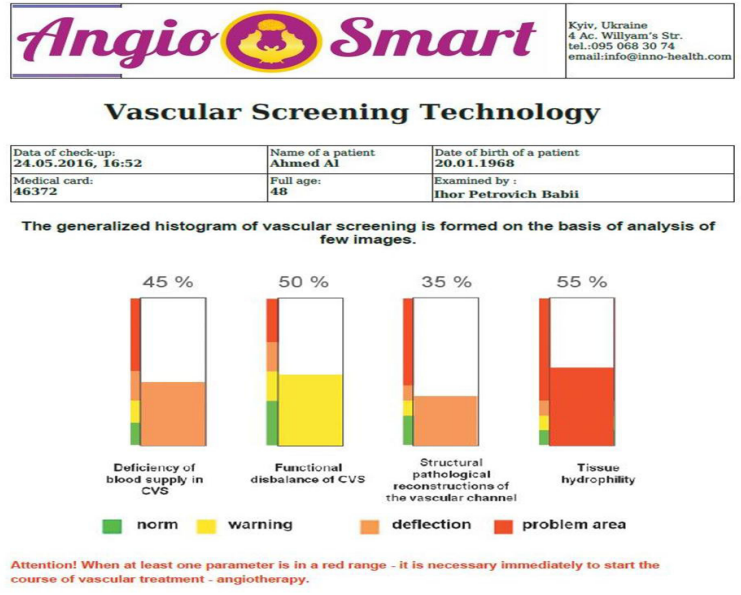


Figure 25: Program decoding.

4. Clinical conclusion

The program is able to generate clinical output in 4 languages: Ukrainian, Russian, English, German

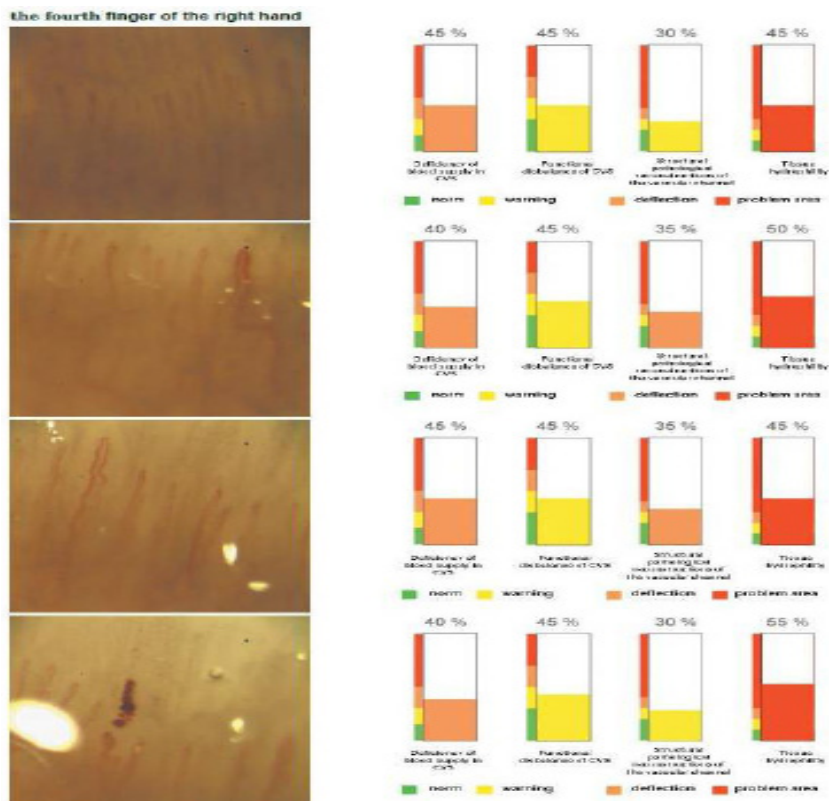


Figure 26: The program is able to generate clinical output in 4 languages: Ukrainian, Russian, English, German

Therefore, after 60 years of its creation due to the digital technology in the 90's of the 20th century, optical capillaroscopy has undergone a renaissance and has grown up into the vascular screening technology with IT-software.

The daily 20 years of clinical application for the diagnosis and treatment of vascular disorders has been accumulated and integrated into the technology of clinical interpretation and digital measurement of the hemodynamic parameters of the microcirculation, and finally filled the vascular screening technology for microcirculatory changes with the intellectual component of in-depth knowledge of Macro-Micro-Angiology.

This approach of the long-term and expensive project of clinical research of the capillaroscopy method allowed redefining the possibility of a method in the framework of vascular screening technology as an evidence base for microcirculatory changes in the vascular bed and monitoring its sanogenic or pathological changes during angiocorrection and angiotherapy.



Figure 27: Technology for vascular screening

Today the vascular screening technology makes reliable diagnosis, which doctors and patients can understand.

- **For a patient** – rapid and available information about the cardiovascular system's state.
- **For a doctor** – quick objectification of processes for decision-making, enhanced customer.
- **For health care** – independent tool of evidence-based medicine, means for legal support and protection against medical mistakes.

IT component of VST enables to:

- visualize problems at various stages of CVD,
- make computer analysis of detected disorders and possible risks,
- create subtechnologies for making tactic decisions in neonatology, pediatrics, angiology, cardiology, angioneurology, oncology, rehabilitation, balneology, insurance medicine.

The vascular screening technology is a unique technology created on the basis of combination of technical components, scientific knowledge of microcirculation and hemodynamics, angioarchitectonics combined in a single complex.

Variety of technical models

Stationary device for vascular screening in a unit for functional or vascular diagnostics.

Mobile version (for fielding advice, diagnosis at a patient's bedside in intensive care and operating room).

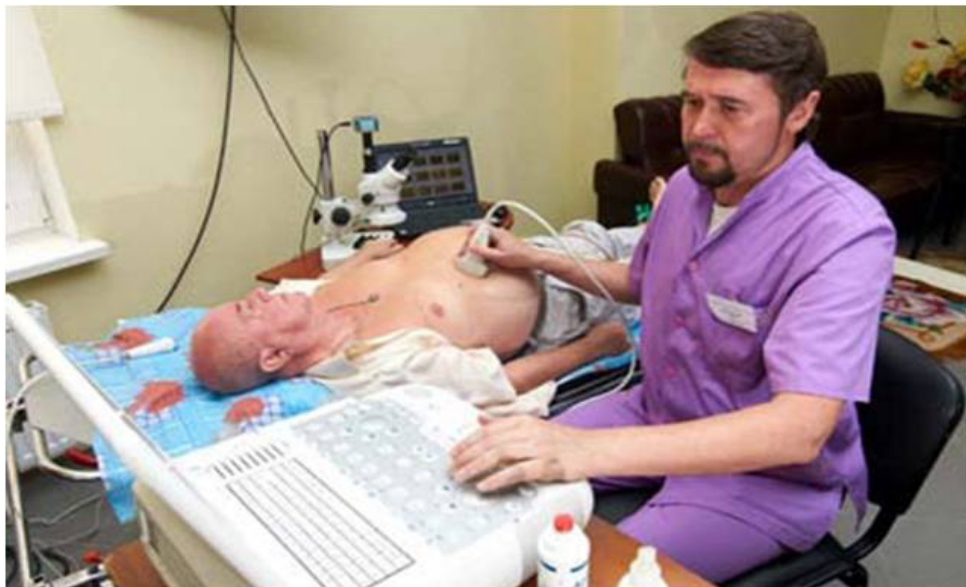

Figure 28: Vascular screening.

KEY BENEFITS OF VASCULAR SCREENING TECHNOLOGY:

- high visualization of information for understanding by a patient;
- patients' confidence and visualization of real images allow a doctor and a patient immediately to discuss ways of the problem solving;
- easy to use: diagnosis lasts 5 minutes;
- non-invasive;

- high accuracy;
- bloodless, painless, safe;
- absence of contra indications;
- high quality of imaging both of capillaries and circulation rate.

VST's hemodynamic parameters:

Visualization of microangioarchitectonics and capillary blood filling is a determinative factor in evaluation of sufficiency of functioning of the whole hemodynamic system so much as capillaries form microcirculatory channel that it is an end link of blood supply system. Capillaries filled with blood evenly are a proof of correct functioning of the system heart – arteries – capillaries – veins – heart.

Microcirculation research by digital optical capillaroscopy gives an opportunity to get an enlarged capillary image on the monitor (1 sq.mm of native microcirculation segment is displayed on the 15'-monitor and fills in the entire monitor field). Therefore, the operator of measurements manually generates a number of macro-mistakes, since movements of the hand with a digital pointer and digital increase of micro-processes and cause significant errors in the measurement of diameter in different segments of the capillary. Therefore, it is necessary to search for digital technologies for stabilization and digital image processing.

This was the aim of creation and development of the technology for vascular screening [30, 44, 45, 46, 47], which allowed not only to improve the technological complex, but also to transfer the software into a fundamentally new level of initial measurement and analytical data processing and the automatic formation of the expert-level conclusion in the form of a clinical interpretation of possible signs of pre-disease, predictions and risks of further development of CVD with a possible clinical picture of the dysshemia.

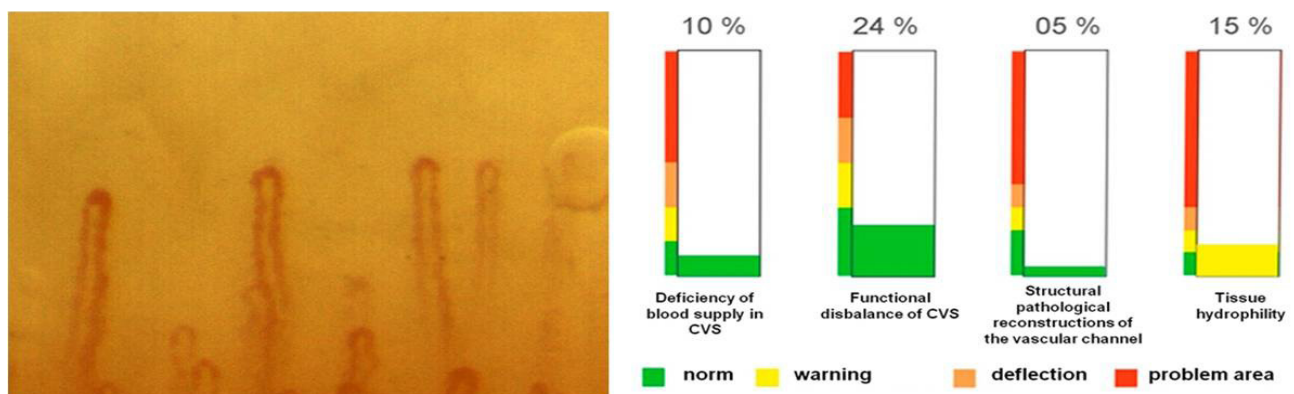


Figure 29: The norm of capillary picture during vascular screening.

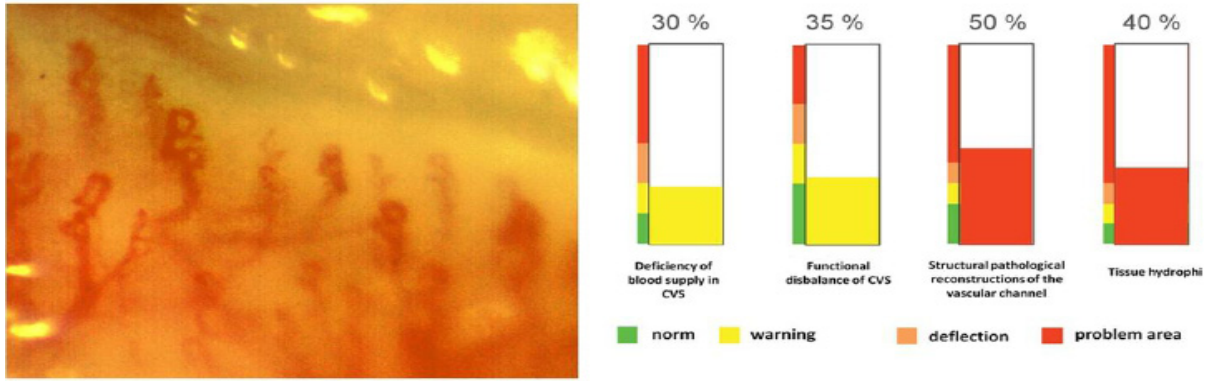


Figure 30: The pathology of capillary picture during vascular screening.

For about 20 years Veritas Research Center (<http://angio-veritas.com/technologies/tehnolohiya-sudynnoho-skryninhu/?lang=en>) has been working under development of the vascular innovative technology for visualization, objectivation and analysis of changes in the microcirculatory channel.

Thanks to the clinical interpretation and smart analytical IT-software, the vascular screening technology has a wide range of application for different levels of medical institutions and the profile of medical practice - from neonatology to psychoneurology, endocrinology, oncology and stomatology.

Vascular screening subtechnology as an improvement software for specific basic medical departments.

Biomarkers of neoangiogenesis as “onco-capillaries”

Application: family doctors, oncologist, urologist, gynecologist.

Benefits: the subtechnology offers an innovative approach to the cancer diagnosis and, importantly, it is an effective tool in the onco-screening, future monitoring of disease conditions of the onco-patients and the disease’s progress at the different stages of cancer pathology.

Congenital malformations of vessels

Application: obstetric, neonatal, pediatric and genetic departments.

Benefits: diagnosis of congenital forms of vascular anomalies.

Normal formation of vessels - the guarantee of health of the nation and the state.

Cardiology and cardiac surgery

Application: cardiology, cardiosurgery, angiosurgery, anesthesiology.

For cardiac surgery – to quickly assess the effectiveness of the operation into the operating

table.

Benefits: to provide immediately examination of the efficiency of heart pump function for whole body with personally approach.

Angioneurology

Application: family doctors, child and adult neurologists, angiologist

Benefits: find vascular pathology at the pre-clinical stage and prescribe personalized appropriate treatment, a neurologist may withdraw completely from strokes statistics among their patients. Pathology of vessels may develop 2-3 years before having a stroke. Vascular screening is an indicator of troubles in human vascular system and the brain in particular.

Psychiatry

Application: for cases like depression, epilepsy, dementia, sleep disorders, phobias and so on.

Benefits: early detection of abnormal conditions of brain vessels would allow identifying congenital or acquired vascular disorders and partially correcting them, thereby improving the quality of life of these patients.

Angiotherapy

Application: intensive care unit, cardiovascular, neurovascular and angiologic centers.

Benefits: fixation of necessary parameters at all stages of therapy that enables specialists dynamically react to obtained results and adjust treatment plans in accordance with patients' needs.

Rehabilitology and balneology

Application: SPA-centres, rehabilitation department

Benefits: This may be like an evidence for protection of the sanatorium, spa and rehabilitation center from critical situation with patients.

Endocrinology and dermatology

Application: diabetes mellitus, thyroid and mammary gland pathology, hypophyseal pathology, obesity, alopecia, hormonal and structural disturbances in the sexual sphere: endometriosis, fibromioma, prostate adenoma, adrenal pathology.

Benefits: it's possible to correct some pathological endocrine disorders due to specific

patterns.

Dentistry

Application: for dentist's therapy of periodontitis and periodontosis, temporal arteritis with the aim to save native teeth.

Benefits: adequate treatment and preservation of natural teeth due to detection of vascular disease in the blood supply for the teeth and gum.

Pharmacology

Application: vascular treatment department, intensive care department

Benefits: the visualized assessment of the patient's state before vascular treatment and after its completion, which confirm the effectiveness of medicines. Evidence based software for treatment managements helps to create adequate treatment scheme and receive predicative successful treatment process with 100 % guaranty due to treatment monitoring management.

Insurance

Application: to determine the risk of critical conditions

Today life insurance is one of the hardest segments in the insurance industry, which is caused by high-risk because of lack of an objective assessment of the insured.

Benefits: This subtechnology in the screening mode makes it possible to assess risks of vascular events and predict possible insurance claims.

Thus, the method of optical visualization of capillaries over the past 20 years has undergone a global renaissance and has developed into a smart technological complex - a technology for vascular screening with high parameters of 100% visualization and objectification available to physicians and patients to understand.

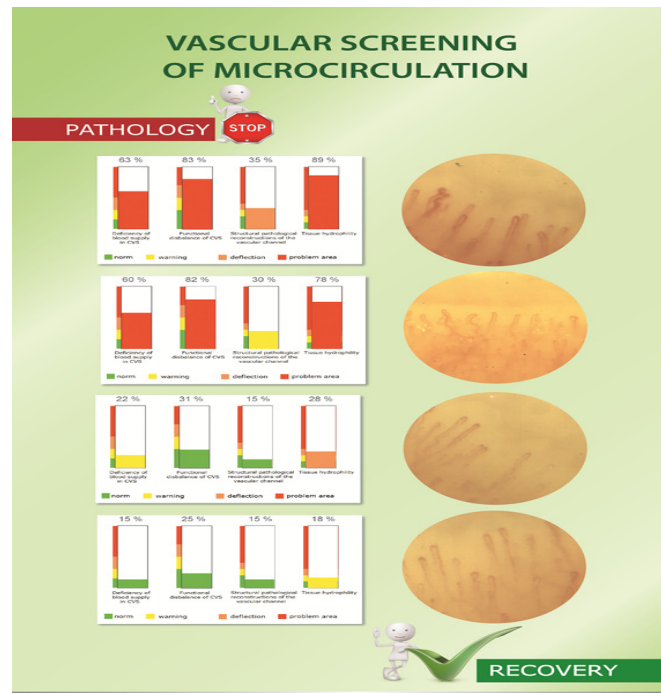


Figure 31: Applied technology for vascular screening in the monitoring of personalised angiotherapy.

At present, the informational capacity of VST is 96%, the specificity is 87%, the sensitivity is 92%, which is achieved owing to analytical data processing and IT technologies of clinical expert-level interpretation [3, 43, 44, 46, 47].

3.7. Radionuclide diagnostics (SCINTIGRAPHY)

Direct non-invasive method.

The method is based on registration of radiation from the artificial radioactive substances injected into the organism with the tropism to one or another organ. The isotopic mark of the radiopharmpreparation allows tracing the character and way of accumulation and excretion of the preparation from the examined organs and tissues [48].

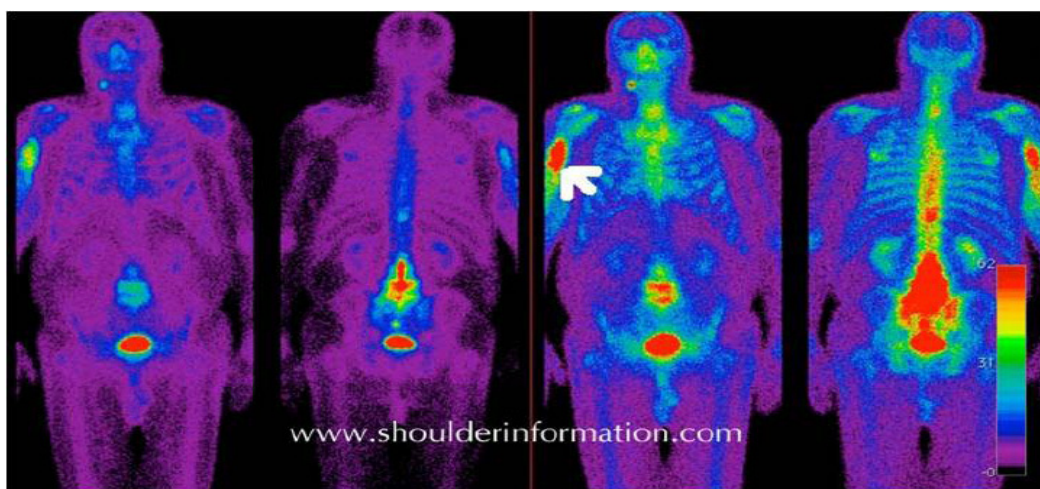

Figure 32: Scintigraphy of a shoulder tumor at the right humerus (white arrow). (http://www.shoulderinformation.com/info/shoulder_diagnostics/shoulder_scintigraphy.htm)

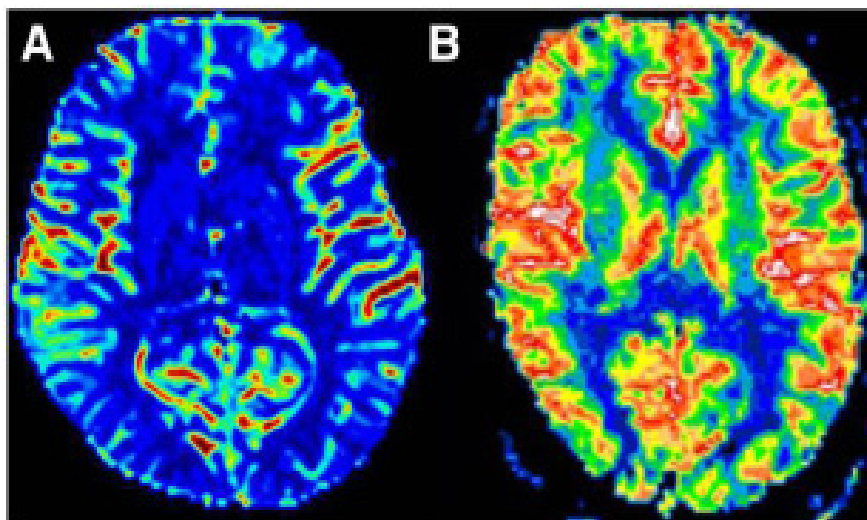


Figure 33: The scintigraphy. (<http://tech.snmjournals.org/content/41/4/306/F2.expansion.html>)

The investigating object – permeability of the vascular system of a certain organ or tissue.

Level of the vascular system examination – determination of parameters of the regional blood flow in assessment of the organ's functioning (radiohepatography, radiocardiography, radiopulmonography, radiorenography, radioencephalography).

Dataprocessing – quantitatively- visual by means of assessment of the period of the half-decay.

Advantages of the method.

1. Applied method for dynamic investigations of the organ's functioning.
2. It reflects functioning of the vascular system in the organ as the whole without explanation of causes of absence of the contrast accumulation.

Disadvantages of the method.

1. Results of application of the method have the statical image and doesn't specify the pathogenetic mechanisms of origin of one or another pathology.

This method is gradually superseded by modern spectrographic programs (SPECT) as a part of CT-MRI studies of organ and system perfusion.

3.8. Radiopaque angiography

Digital subtraction angiography (DSA) is a fluoroscopy technique used in interventional radiology to clearly visualize blood vessels in a bony or dense soft tissue environment. Images are produced using contrast medium by subtracting a "pre-contrast image" or mask from subsequent images, once the contrast medium has been introduced into a structure. Subtraction angiography was first described in 1935 and in English sources in 1962 as a manual technique.

Digital technology made DSA practical from the 1970s [49].

Direct invasive statistic method.

The method is based on the puncture or catheterization of various peripheric arteries, injection of the radiopaque liquid with the further performance of the x-ray films [49,50].

The investigating object – stream of erythrocytes in the volume of the tissue.

Level of the vascular system examination – visualization of the regional arterial (arteriography) and/or venous vascular system (venography, phlebography), lymphatic system (lymphography).

Data processing the obtained– visual, quantitative.

Shortly about angiography methods and methodics:

DSA and fluoroscopy.

In traditional angiography, images are acquired by exposing an area of interest with time-controlled x-rays while injecting contrast medium into the blood vessels. The image obtained includes the blood vessels and all overlying and underlying structures. The images are useful for determining anatomical position and variations, but unhelpful for visualizing blood vessels accurately [49].

In order to remove these distracting structures to see the vessels better, first a mask image is acquired. The mask image is simply an image of the same area before the contrast is administered. The radiological equipment used to capture this is usually an X-ray image intensifier, which then keeps producing images of the same area at a set rate (1 to 7.5 frames per second). Each subsequent image gets the original “mask” image subtracted out [49].

The radiologist controls how much contrast media is injected and for how long. Smaller structures require less contrast to fill the vessel than others. Images produced appear with a very pale grey background, which produces a high contrast to the blood vessels, which appear a very dark grey [49].

The images are all produced in real time by the computer, while the contrast is injected into the blood vessels.

Intravenous digital subtraction angiography (IV-DSA) is a form of angiography which was first developed in the late 1970s [49].

IV-DSA is a computer technique which compares an X-ray image of a region of the

body before and after radiopaque iodine based dye has been injected intravenously into the body. Tissues and blood vessels on the first image are digitally subtracted from the second image, leaving a clear picture of the artery which can then be studied independently and in isolation from the rest of the body [49, 50].

Some limited studies have indicated that IV-DSA is not suitable for patients with diabetes or renal insufficiency because the dye load is significantly higher than that used in arteriography [48]. However, IV-DSA has been used successfully to study the vessels of the brain and heart and has helped to detect carotid artery obstruction and to map patterns of cerebral blood flow. It also helps to detect and diagnose lesions in the carotid arteries, a potential cause of strokes [49, 50].

IV-DSA has also been useful in assessing patients prior to surgery and after coronary artery bypass surgery and some transplant operations [49].

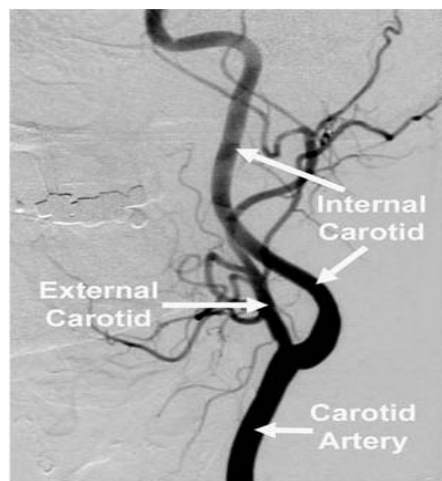


Figure 34: Radiopaque angiography of carotid arteries. (<http://www.daviddarling.info/encyclopedia/A/angiography.html>)

Advantages of the method.

1. Visibility on the large length of the region of the vascular system with the consecutive representation of the passing of the radiopaque substance from the place of injection along the arterial system with the transition through the capillary phase into the venous system.
2. Detects injuries and defects of vessels' development, disorder of their permeability.
3. Makes possible not only to trace the arterial, capillary and venous phases of the cerebral circulation, detect their length in different sections of the vascular system in the organ, but also to examine hemodynamics of separate vascular reservoirs, vascular net of the pathological focal formations (tumours, arteriovenous malformations) by means of the selective injection of the contrast.
4. High diagnostic information in case of tumours with well-developed vascular net, traumatic

and spontaneous hemorrhages, occlusive – stenotic injuries of the major arteries, arterial aneurisms, arteriovenous and arteriosinus pathological shunts.

5. During diagnostic research the catheterizing angiography can transform into the treating method of the endovascular surgery: aneurisms and/or arteriovenous pathological anastomosis are “ungeared” (blocked) with the help of various balloon-catheters, the angioplastics is made under the arterial stenosis, and the regional infusion of medical agents is made.

6. Recently new method of the angiography performance has appeared – digital subtraction angiography – it is the contrast study of vessels with the further computer processing. Change for digital technologies in the angiography has number of advantages such as:

- high quality of allocation of a certain vessel from the general picture and high informative images;
- minimum dose of the contrast substance during the examination;
- convenient archiving and data retrieval;
- absence of an x-ray film and chemicals, low cost per one observation;
- allows reducing traumas during observation due to the possibility of refusal from catheterization and/or decreasing of the number of the injected radiopaque substance. This substance can be injected less traumatic for a patient – intravenous, without using the artery’s catheterization.

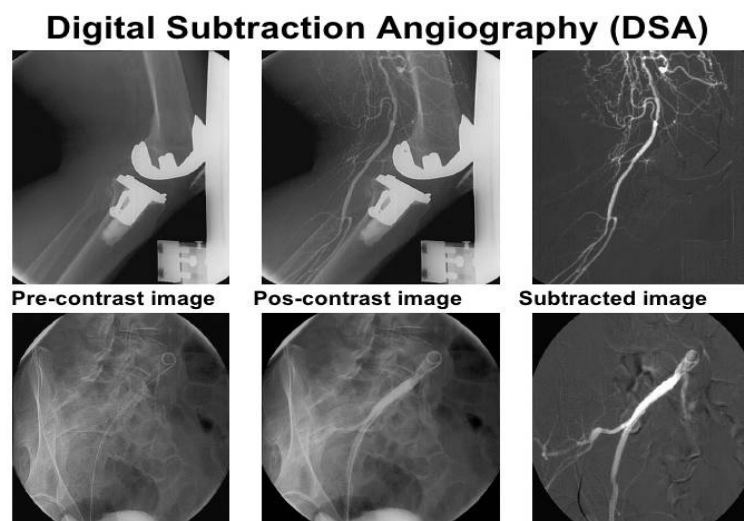


Figure 35: Digital subtraction angiography. (<https://www.slideshare.net/jdtomines/mobile-c-arm-equip-and-dsa>)

Disadvantages of the method.

1. Invasive.
2. High risk of complications from the injection of the contrast (allergic reaction to the contrast, hematoma, thromboembolism), large list of contraindications under the acute inflammatory and infectious diseases, serious patient's condition, mental diseases, allergic reactions to iodine preparations, obvious cardiac, hepatic and renal insufficiency.
3. Delimitation in time of the visualization of the arterial and venous phases of blood flow, impossibility of the simultaneous examination of arteries and veins in the real time.
4. Obtaining images only in one projection of the vessel significantly limits the method's potential in case of the vessel's tortuosity, stenosing injuries, soft arteriosclerotic plaques.
5. Limited time for examination is caused by the fast passing of the portion of the contrast substance through the vascular system, with this connection they assign the arterial, capillary and venous phases of this substance spreading.
6. The obtained angiographic image is static that is the one-moment section. Consequently, it is impossible to perform functional tests and observation in dynamics.

Venography is prescribed according special indications such as chronic thrombophlebitis, thromboembolism, anomaly in development of venous trunks, different disturbances of the venous circulation. The venography is made by the direct and indirect ways. With the direct venography the contrast substance is injected directly to the vein by means of puncture, sometimes catheterization. The indirect venography is made by three ways:

- injection of the contrast substance into the arteries then it comes into veins through the capillary system;
- injection of the contrast substance into the organ's tissues, with this veins are made on films that brings blood from the organ;
- injection of the contrast substance in the medullar space.

Radiopaque angiography in the 90s of the 20th century was considered the gold standard for angiosurgery and cardiosurgery [49, 50].

However, with the advent of CT-MRI technology visualization of the vascular bed in the angio-mode, gradually loses its positions:

DSA is done less and less routinely in imaging departments. It is being replaced by computed tomography angiography(CTA), which can produce 3D images through a test

which is less invasive and stressful for the patient, and magnetic resonance angiography (MRA), which avoids X-rays and nephrotoxic contrast agents [49].

3.9. Ultrasound diagnostics of vessels

Ultrasound vascular diagnostics as a new, non-invasive method of rendering vascular segments alive began its lifecycle in the 90s of the 20th century, due to the emergence of colorcoding programs for blood flow.

Ultrasound diagnostics of vessels includes two complementary methods: ultrasound coloured angioscanning (USAS) and ultrasound dopplerography (USDG). USAS visualizes the vessels' structure and functions of the vessels' wall. And USDG graphically records circulation rate in vessel and characteristics of functioning the vascular wall, interconnection of all links of blood circulation at the local level [3, 23, 28].

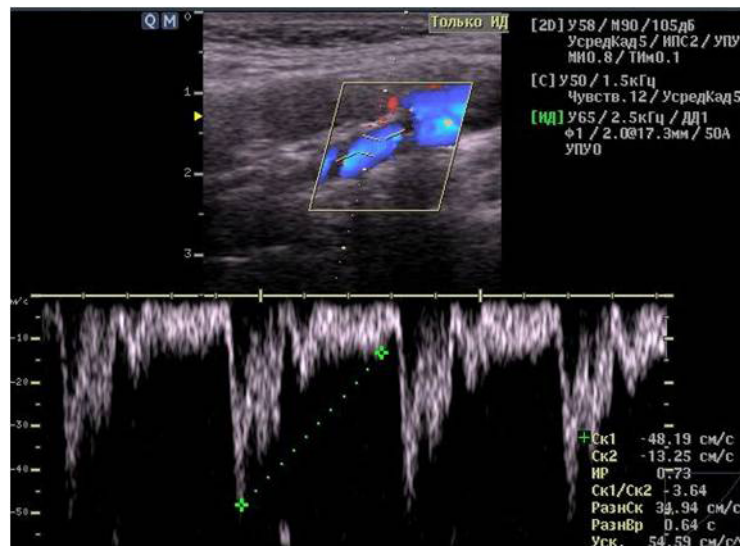

Figure 36: Ultrasound diagnostic system with the effect of coloured cartography of blood flow and ultrasound dopplerography.

Generally, ultrasound angiology has the next vascular approach for objectivisation vascular disorders:

1. US angioscanning
 - 1.1. Black and white mode
 - 1.2. Color-coded mode
 - 1.3. Energetic Doppler-coded mode
 - 1.4. Small-vascular perfusion mode
2. Ultrasound dopplerography
 - 2.1. USDG as separate medical equipment (appeared in the 80's of the 20th century)

2.2. USD as an option for US systems

2.3. Laser Doppler flowmetry (velocimetry)

Non-invasive dynamic method (USAS – direct visual, USDG – indirect graphical).

The method is based on application of the ultrasound radiation with usage of the Doppler effect: the ultrasound wave changes its frequency while it is reflected from the moving elements of blood, in particular erythrocytes.

The investigation object – segment of the major artery or vein.

Level of the vascular system investigation – major vessels.

Data processing– quantitative-qualitative (digital and/or graphical).

US-angioscanning (USAS) can be used in several modes of functioning of the ultrasound system depending on its type and kind such as: in modes of black-and-white image, effect of the colored cartography of blood flow (colored angioscanning) and energetic color-coding of blood volume, color-coding of the tissue perfusion:

- using modern US-system with color-coding and dopplerography one can obtain more information about the condition of circulation in major arteries and veins. In the mode of the colored doppleric picturing it is made the qualitative assessment of the size of the lumen, elastic- tonic and pulsation characteristics of the examined segment of the artery, width of the vascular wall, organization of blood flow with diagnostics of areas of disorganization in the form of turbulence, prognostication of the risk of the possible embolisation of cerebral arteries.

- modern USD-system with color-coding of the effect of the energetic doppler enables to obtain monochrome pattern of the circulation in organs but doesn't give the possibility to analyze the tissue's type in organs, especially of areas with the intensive circulation, that is typical for an individual pathogenetic approach to the treatment tactics. The mode of the energetic doppleric picturing enables to visualize cerebral arteries with the transcranial scanning, assess the character of the arterial angioarchitectonics, tortuosity of the proximal segments.

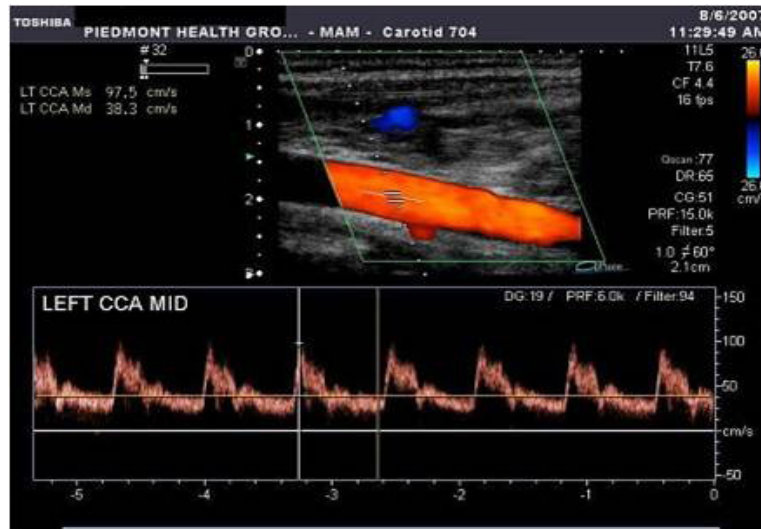


Figure 37: Ultrasound colored angioscanning.

The energetic Doppler reflects the blood volume in vessels in one color, depending on the direction of blood flow.

Red and blue colors reflect different directions of blood flow and not always coincide with the common image of arteries and veins in atlases (arteries – red-colored, veins – blue-colored). Red or blue color on the US-angioscannograms shows only the direction of blood flow – towards the sensor or from the sensor.

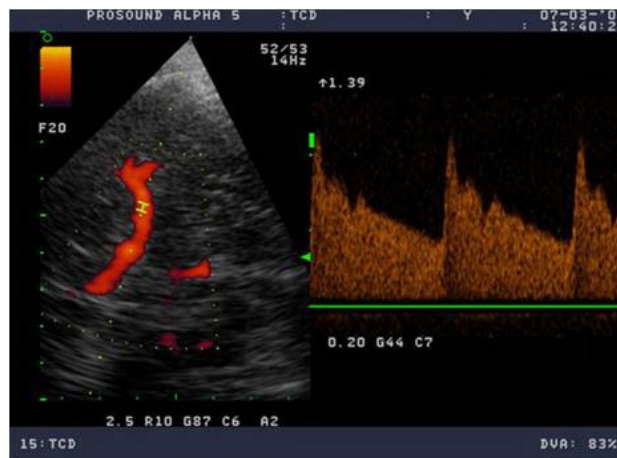

Figure 38: Effects of color-coding of blood flow with visualization of the angio architectonics of organs.

US-angioscanning enables to visualize structural changes – lengthening of an artery (tortuosity, flexure, loop), aneurysmal extension, stenosing- occlusive injury of arteries with a defect of blood filling of the vascular lumen, presence of the heterogenous formations – from enlargement of complex intima-media up to atherosclerotic plaques, thromboemboli.

Method of color-coding of the blood flow with angioscanning enables to study its character, presence of the turbulence of the flow and its cause. However, during one heart cycle (on the average 1 heart cycle per 1 second) rate of changing of different hemodynamic parameters significantly exceeds the potential of perception of the visual analyzer of the human and therefore it requires more detailed graphical layout. Very in this aspect the USDG method

is more sensitive in that time.

With the help of the pencil-gauge **ultrasound dopplerography (USDG)** makes possible to receive a graphical signal from the separately taken point in the projection of one or another vessel. Graphical profile of changes of the linear circulation rate during the heart cycle reflects the character of the flow – laminar or turbulent, continuous or expressed intermittent blood flow, elastic-tonic characteristics of a certain vessel, level of the intravascular resistance distally from the place of location and dependence of blood flow on signs of the hydrodynamic conflict [23,51].

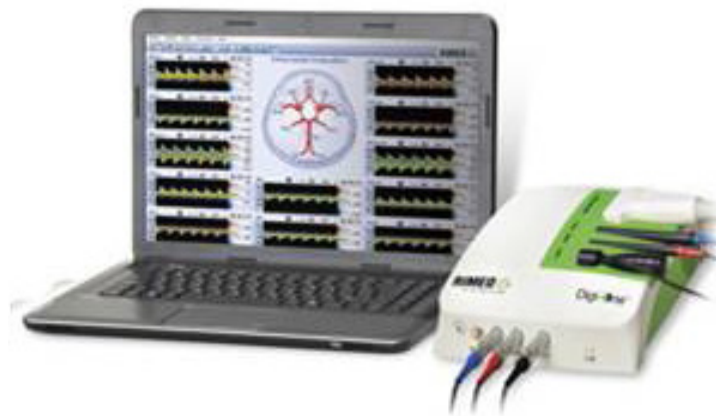

Figure 39: Ultrasound doppler.

Peculiar features and main advantages of the dopplerography method is in the generalization of all local data from the examined segments of arteries and veins, and the information from separate points is analyzed according to the assessment of hemodynamics of the whole regional system.

However, every above-mentioned method has its own advantages and disadvantages. The dopplerographic method is a graphical representation of changes of the velocities' profile during the heart cycle, therefore perfect knowledge of hemodynamic laws, mutual influence of the elasticity of the vascular wall and its tonus on the character of passing of the pulsating wave significantly expands informative and specific features of the method.

It is possible that application of the specific graphical methods will increase the informative feature of the US-angioscanning method.

On the other hand, these investigating methods for the vessels' condition are closely interconnected and must include both examination of major arteries and veins starting from the aortic arch and intraorgan's scanning and dopplerography of the regional arteries and veins. Only this sequence of performance of US-investigation of the vascular system can give the overall picture of etiopathogenesis of the vascular-organ insufficiency.

Advantages of the method

1. Non-invasive.

2. Harmless and possibility of the numerous applications in dynamics.

3. USAS is sensitive to slightest changes in diameter of vessels, localizes areas of stenosis, atherosclerotic plaques, burbles of blood flow in the place of segmental stenosis of vessels.

4. Transcranial angioscanning enables to visualize arteries from the Willis's circle, detect tracts of the collateral change of blood flow with the stenosis and occlusions of major arteries.

5. Obtaining the dynamic image unlike static image with the radiopaque angiography (AG) and MRA.

6. Simultaneous investigation of the arterial and venous beds.

7. Experimental modeling of various pathological states and application of various provoking factors for objectivation of causes of the vascular-cerebral insufficiency:

- tests with stretching of the arm for diagnostics of the expressiveness of the syndrome of the thoracic output;
- respiratory tests;
- tests with the head turning;
- compression Matas's test
- ortho- and antiorthostatic tests;
- tests with dosed physical load;
- acute pharmacological tests.

8. The USDG method proved to be promising in the development of a methodology for analyzing not only the linear velocity of blood flow in systole and diastole and independent of the location angle of the indexes of pulsation, resistance, turbulence, etc. [23].

Disadvantages of the method

1. Impossibility of the review visualization of all vessels: unlike methods MRA and AG US-method enables only investigate a vessel by segments. Nowadays lack of the effect of the review/survey is partially compensated by new technologies – panoramic scanning.

2. Method of USDG is limitedly sensitive for stenosing injuries of arteries up to 50% of the reduction of the lumen.

3. At the same time, the USDG method proved to be more informative about the functioning of the vessel due to a qualitative analysis of the entire dopplerographic curve with the evaluation of elastic-tonic properties, blood pressure, intravascular pressure, and the influence of intracranial pressure. However, for most physicians, such an analysis requires in-depth knowledge of different areas of Macro-Micro-Angiology to formulate proper conclusions and clinical interpretations.

4. As for the ultrasound scanning, the stage of vascular visualization and measurement of their diameter, the intima-media complex, the diagnosis of tortuosity and loops, and atherosclerotic plaques has actually exhausted itself. Therefore, the passion for visualization and ease of perception of these images in 20 years of the 21st century has gradually ceased and today the technique of angioscanning requires more profound knowledge of physicians for clinical interpretation and application in the Macro-Micro-Angiology for personalized angiocorrection and angiotherapy.

The combination of in-depth knowledge of Macro-Micro-Angiology and the possibilities of using ultrasound examination of angioscanning and USDG to form a new ideology for screening vascular disorders at the macro- and peripheral regional levels, with a clinical understanding of the revealed changes [4, 23, 51] and the possibilities of personalized treatment on the principles of evidence-based medicine [4, 29].

During 2010-2017, the methodology of USDG of major arteries and veins gradually developed into Angiomarker technology with the possibility of analysis of about 50 hemodynamic parameters that proved to be significant pathohemodynamic indicators of vascular blood flow disorders, in contrast to structural changes at the macro level [52, 53, 54, 55, 56, 57, 58].

For a successful application of the USDG methodology doctor should have deep knowledge of the anatomy and physiology of the human vascular system, basic knowledge of hydrodynamics and hemodynamics, physics of the ultrasound, characteristics of blood flow as a non-Newtonian liquid.

The methodology essence is in the comprehensive consideration of the blood system as the integral system of the closed arteriovenous-capillary tubing - with its resistance, elasticity of the vascular wall, vascular tone, hydrophilicity of the surrounding tissues.

Up-to-date high-sensitive equipment enables to work both with arterial and venous segments simultaneously, and specially designed software can calculate how significant deviations in a patient from the condition of the arteriovenous balance in the direction to unjustified arterial hyperemia or venous stasis of any degree.

Today, this technique is urgently necessary not only for functional and ultrasound diagnostics, it is relevant to many areas of medicine, such as paediatrics, neonatology, neurology, psychiatry, urology, gynaecology and obstetrics, oncology, cardiology, surgery.

Only inexperienced physician allows himself to ignore the results of the doppler studies of the major and peripheral vessels.

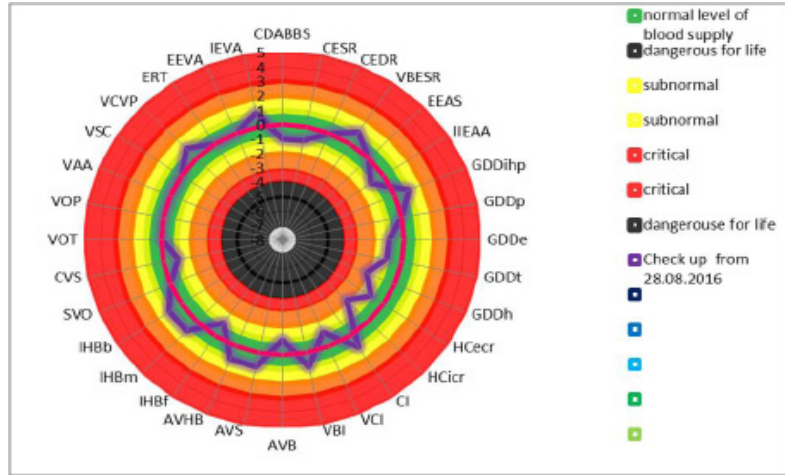


Figure 40: Angiomarkers. The norm.

Normally histogram should be in green and yellow stripes.

If your hemodynamic parameters are depicted in the orange-red range, you should undertake treatment aimed at preventing vascular crises, stroke and heart attack and other life-threatening critical vascular conditions.

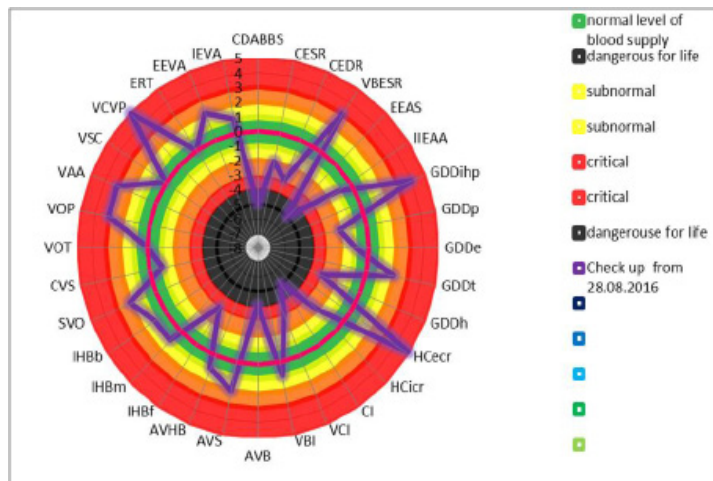


Figure 41: Angiomarkers. The pathology.




Figure 42: Angiomarker technology for a personalized angiocorrection monitoring: from pathology to recovery.

3.10. Laser doppler flowmetry (LDF)

Non-invasive indirect graphical method

The method is based on the application of the laser radiation with usage of the Doppler’s effect [37].

The investigation object – tissue microcirculation in the external layers of the skin, mucous membrane. The control volume: 1mm³ contains nearly 200 microvessels.

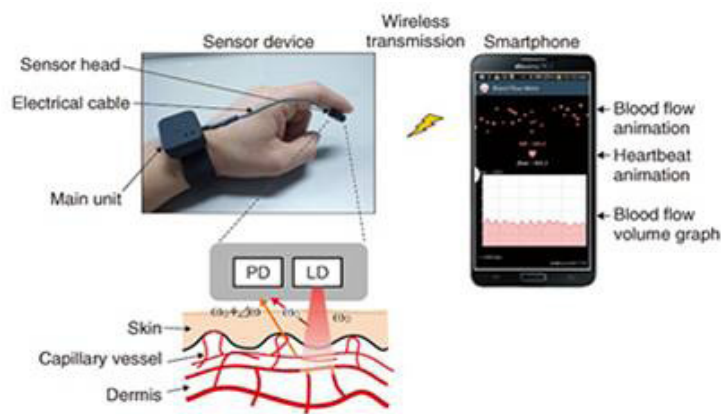


Figure 43: Dynamics of laser doppler flowmetry development from prototype to mini-device. (<https://www.ntt-review.jp/archive/ntttechnical.php?contents=ntr201501fa3.html>).

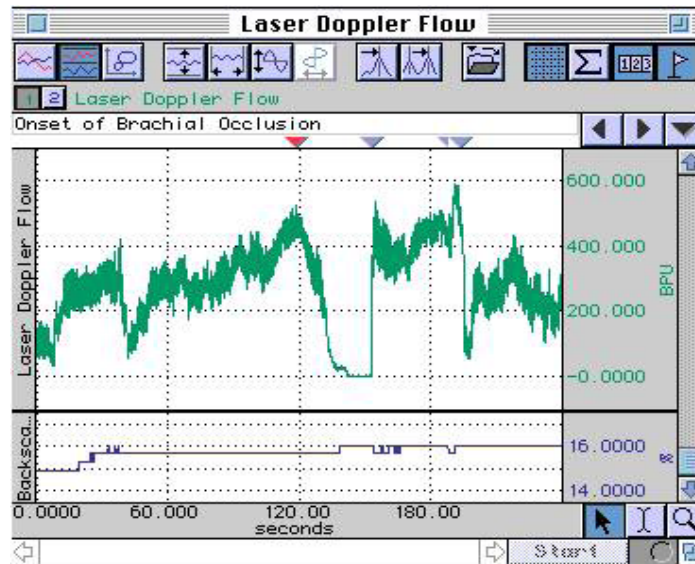


Figure 44: Laser Doppler flowmetry (LDF). (<https://www.biopac.com/?app-advanced-feature=advantages-of-laser-doppler-flowmetry>).

Level of the vascular system investigation – radiation of the magnitude of the blood perfusion in tissue on the microcirculatory level.

Data processing– quantitative- qualitative (digital and/or graphical).

There are low-frequency, high-frequency and pulsate fluctuations of the tissue circulation that is the physiologically important.

Low-frequency fluctuations (LF) from 4 to 12 fluctuations per minute are caused by the activity of smooth-cell myocytes in the wall of microvessels and precapillary sphincters. LF-fluctuations are the representation of the mechanism of an active change in the microcirculation – vasomotion.

High-frequency fluctuations of circulation (HF) from 13 to 30 fluctuations per minute are caused by the periodical changes of the pressure in the venous section of the vascular bed due to the respiratory fluctuations. This compensatory mechanism is observed with the ischemic disorders of the dermal circulation.

Pulsate fluctuations of the circulation (CF) is considered as the basic but passive mechanism of circulation in the microcirculatory bed, it is forming far outside the bed.

Modern laser analyzers are equipped with the mathematical wavelet-converters of amplitudes and frequencies of fluctuations of circulation connected with endothelial, neurogenic and biogenic activity. The influence of the respiratory and cardiac rhythms on the level of microcirculation is taken into account.

Advantages of the method

1. Unlike the ultrasound dopplerography methods, application of the sounding wavelet laser radiation enables to obtain the mapped signal of the greatest amplitude from the thin surface layer (nearly 1mm), that contain structures of the microcirculatory bed such as arterioles, capillaries, venules and arteriolar-venular anastomoses.
2. Possibility of performance of functional tests for investigation of the vasoconstriction and vasodilatation, endothelial activity and neurogenic regulation.

Disadvantages of the method

1. General character of the obtained information: absence of the information differentiation about the certain microvessels – arterioles and venules.
2. LDF method is a relative way of the microcirculation control because the calibration of the device before measurements sharply depends on the heterogeneity of erythrocytes distribution in the tissue, pigmentation and width of the epidermis, which are not controlled under non-invasive investigations.
3. Unlike the optic capillaroscopy the method is indirect with the absence of the visualization of the form and caliber of the capillary, density of capillaries per unit area that essentially influence the final interpretation of the obtained data.

3.11. Computed Tomography

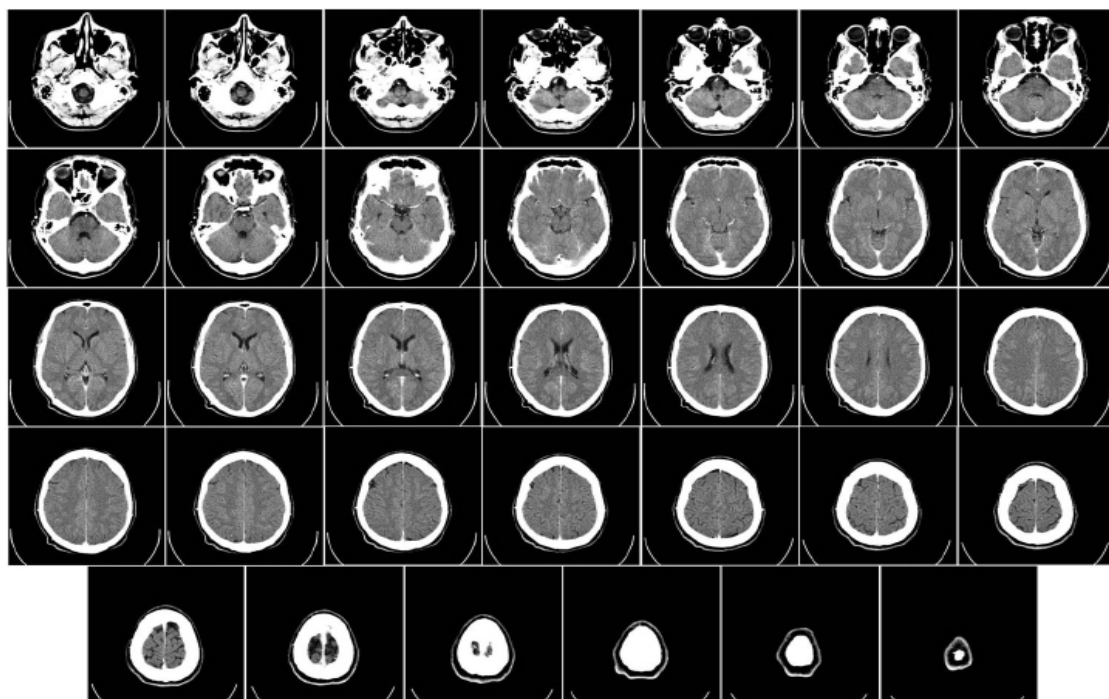


Figure 45: Computed tomography. (https://en.wikipedia.org/wiki/CT_scan)

Direct non-invasive visualizing method

The method is based on application of the x-ray radiation [59].

The investigation object – layer-by-layer investigation of the axial plane.

Level of investigation – state of the liquorodynamic in the brain, with contrast study – state of the regional angioarchitectonics.

Data processing – quantitative- qualitative visualizing method.

Advantages of the method

1. Distinguishes more than hundred stages of changes of the density of the examined tissues – from 0 (for water, liquor) to 100 and more (for bones and calcificates) that enables to differentiate the densitometric differences of normal and pathological parts of the tissue within the limits 0.5-1% that is in 20-30 times more than on common roentgenograms.

2. Minimum width of sections is 2-5mm and enables to differentiate reactive changes in the surrounding tissues (areas of the perifocal brain edema-swelling, ischemic foci, degree of hydrocephalus, tracts of liquor circulation).

3. Resolution – foci of the diameter to 0.5 sm.

4. Sometimes cardio synchronizers are used in the cardiology with CT, which enables to obtain pictures in the certain phase of the heart cycle. This make possible to assess size of the auricles and ventricles and also the heart functioning according many functional parameters.

5. The spiral tomography is a new method of obtaining CT-images due to the movements of emitter by the spiral around the patient's body. Owing to this one can receive information about the full structure of the certain part of the body in some seconds. The computed angiography, which enables to detect efficiently the vascular pathology, 3D-reontgenorgaphy and even virtual endoscopy have appeared on the basis of the method.

Disadvantages of the method

1. Necessity of the intravenous infusion of radiopaque substances for visualization of vessels.

2. Inferior in criteria of informativeness and sharp image to the MRI method.

3. 12. Magnetic Resonance Imaging in Angiomode (MRA)

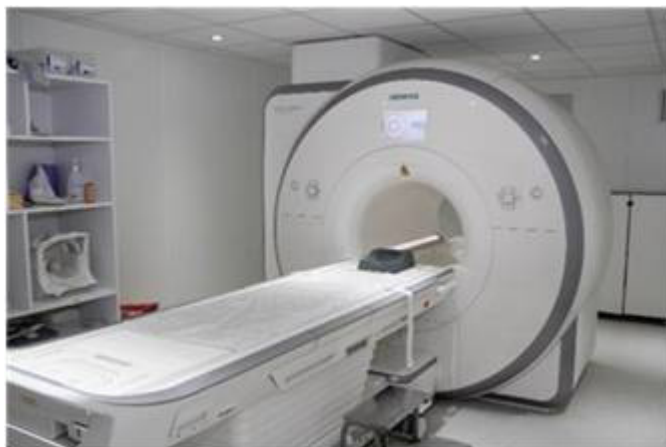

Figure 46: Magnetic resonance imaging. (<https://www.cedars-sinai.edu/Patients/Programs-and-Services/Imaging-Center/For-Patients/Exams-by-Procedure/MRI/>)

Magneto-resonance tomography (MRT)– nuclear-magnetic resonance (NMR) is relatively new kind of obtaining images of organs that is based on the effect of nuclear-magnetic resonance [60, 61].

Zavoyskyy J.K. discovered the phenomenon of NMR in 1944 as the paramagnetic resonance and independently of him Bloch F. and Purcell E.M. discovered it in 1946 as resonance phenomenon of the magnetic moments of the nuclear kerns and for that the received Nobel Prize in 1952. Clinical samples of MR-tomographers appeared in they beginning of 80s for investigation of the internal organs and the head. Latter potential of MRT was expanded for examination of vessels and the heart because it was succeeded to receive images in the real time with application of the sections' synchronization.

Direct non-invasive visualizing method of the introscopy.

The method is based on application of radiation of the radiowave diapason with the wavelength from 1 to 300 m, with application of the phenomenon of the short-term resonating of protons in the electromagnetic field for visualization of tissues depending on the different water containment in them.

The investigation object –visualization of the vascular system on the virtual section of the organ.

Level of investigation –regional angioarchitectonics.

Data processing– visualization of the vascular system, made on the principle of automate scanning controlled by a computer, processing and receiving of the layer-by-layer image of the internal structure of organs.

MRA method (magneto-resonance angiography) visualizes the circulating blood and creates additional potential for detection of vascular injuries.

Magneto-resonance angiography enables to obtain the selective image of vessels (like an image obtained on the common angiograms) safely for patients to assess the degree of tortuosity of major arteries and veins in the head, and also to detect the presence of stenosis and occlusions.

Thus, owing to the advanced method of the observe diagnostics – MRT in the angiomode – it is possible to visualize injuries of major arteries of the head and cerebral arteries due to receiving of their static (fixed) image on the background of MRT-structural injury of the cerebral substance.

Advantages of the method

1. Almost harmless for patient's health because removes the problem of gamma-radial load on the patient and a doctor (unlike CT).
2. High sensitive to separate vitally important isotopes and hydrogen that provides high contrast range of received images.
3. Possibility of receiving images of the vascular bed without injection of the contrast substance and with determination of parameters of blood flow.
4. High resolution – one can observe objects sized by portions of a millimetre.
5. It is possible to obtain not only the transversal but also longitudinal sections, images of structures of vessels in different planes, to form three-dimensional constructions of organs and tissues with high resolution and large contrast range (comparing to CT).
6. High resolution by tonality of black-and-white image with possibility of differentiation gradation of tones from white (fatty tissue) to black (air, bones, calcificates).
7. Precise visualization of vascular walls, atherosclerotic plagues, intracranial aneurysms, arteriovenous malformations, arteriosinus pathological connections.
8. For investigation of extremely small biological objects the resolution is reached 10 mkm on special applications, i.e. it is possible to obtain images of the cell and its internal structures. Therefore, a term MR-microscopy is established.

Disadvantages of the method

1. Necessity of the magnetic field creation with high voltage requires huge energy consumption, application of expensive technologies for providing the super conductance.

2. Impossibility of examination of patients with cardio stimulators, metallic implants, pregnant.
3. Impossibility of detection of foci of the ossification and calcification.
4. Intravenous injection of the magneto intensifying contrasts (such as magnevist, omniscan etc.) are required for increasing of the diagnostic information.

3.13. Perfusion MRT

Method of the positron- emission tomography (PET) enables to obtain simultaneously tomographic sections, perform investigations of the regional circulation and metabolism with the help of the registration of short-living radioindicators that beforehand were injected intravenously. Visualization is provided by the colored scale of the quantitative level of perfusion [62].

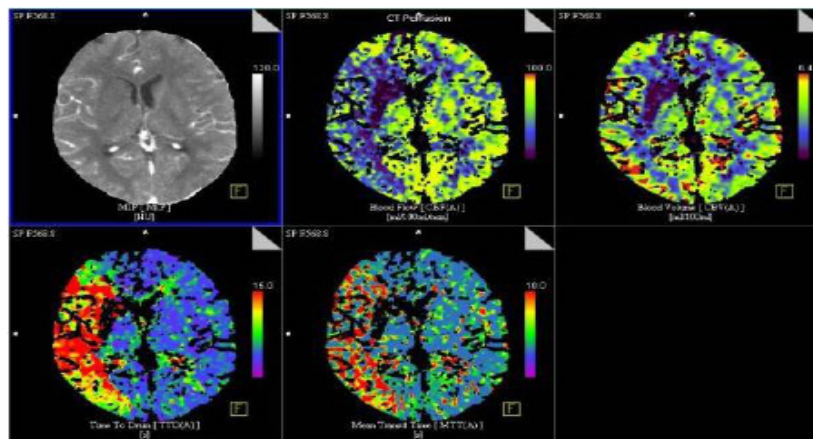


Figure 47: Image of perfusion with application of MRT method (perfusion MRT) gives the possibility to reflect in color different levels of blood supply in tissues of the examined organ. (<http://flexikon.doccheck.com/de/CT-Perfusion>).

Perfusion MRT enables to reflect parts of intensification of circulation during performance of functional mental loads that requires increasing of perfusion in the corresponding area of blood supply.

Taking into account specific features of the functioning of the visual human analyzer and potential of the brain to percept decoded colored images the specific gravity is increasing of the multi-colored images under diagnostics of manipulations.

3.14. Color-coding of gray-scaled scanned MRA- and USD-images

Despite of the sufficient level of visualization with MRA and USD-investigations today new methodological approach is formed to increasing the resolution of received scanned gray-scaled images of the brain and vessels due to the application of the effect of the color-coding [63].

On the first view a mode of 4-64 colored scale seems to be a random set of multiple

colors but it is quite informative for investigation of the circulatory capacity. Only this mode enables to visualize section of the size of 0.5-millimeter of walls in arterioles and venules, character of microcirculation and to color-code blood flows with the help of effect of the optic caustic.

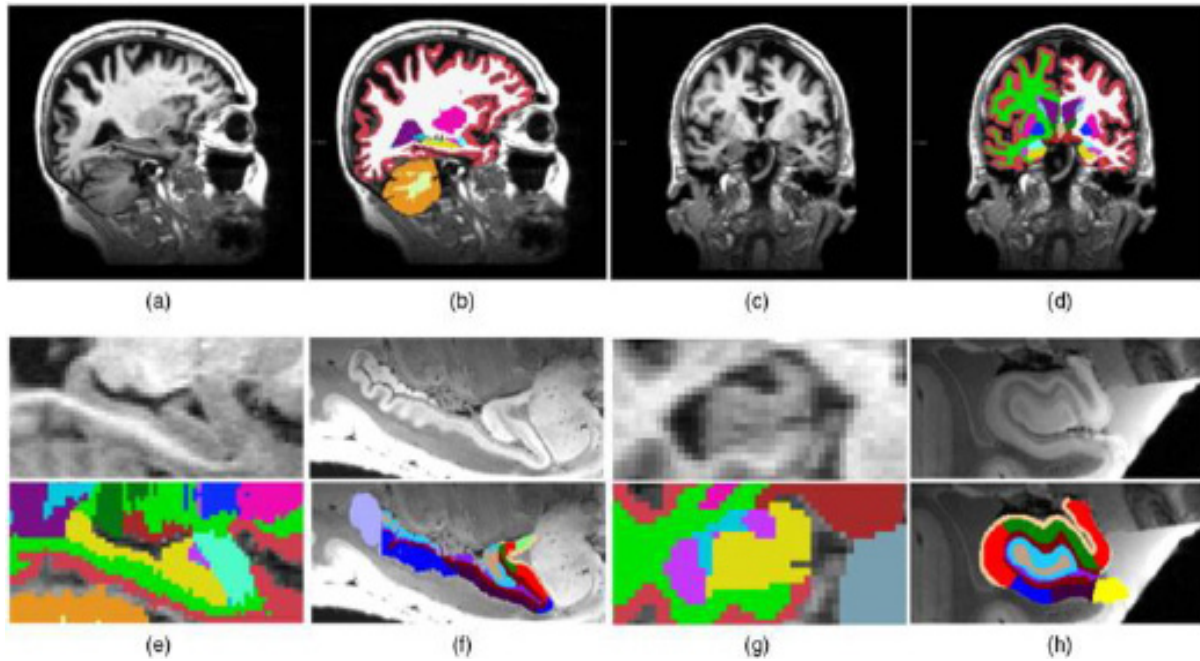


Figure 48: The color-coding of the gray-scaled MRT-images enables to see different densities that significantly expands the potential for interpretation of the received images.

The color-coding of the MRA- images enables to visualize more accurately tracts of the cerebral arteries, their angioarchitectonics, and types of divisions of distal segments. The dirty-brown color visualized the mistiness of the small vessels that was not visible on the gray-scale image.

The mistiness, which was differentiated in color in the aneurysmous formation, is visualized most of all in this projection.

Approaching of small-caliber arterioles (red spots) confirms the presence of the vascular malformation (brown color).

Main advantages of the method

1. In fact, an image, which is got due to color-coding, is like pseudohistological image (approximate to the histological, but not based on the optical visualization of the microstructure, but on the gradation of radiological density and tissue permeability) of organs and tissues that allows to examine different physiological and pathological processes in them;

2. Using the effect of the adequate color-coding owing to the peculiarities of the program we can change different ranges of colors connected with different tissue densities;

3. Color-coding of scanned images help to characterize parts with intensive or weak

microcirculation (ischemia, arterial and venous hyperemia) to differentiate the smallest layers of tissues in organs with different acoustic density (tumors, cysts).

Angiology:

- investigation of the circulation and condition of the vessels' walls in distal segments of the limbs in the normal condition;

- assessment of hemodynamic parameters of the microcirculation as a result of formation of collateral tracts with the presence of stenosis (thrombosis or atherosclerotic vascular occlusion);

- defining the structure of the deeply situated venous valves and thrombus in the deep veins of the low limbs and peripheric circulation for differentiation of the acute, subacute thromboses and postthrombophlebitous syndrome.

Using color-coding of US-image we receive the possibility to characterize different types of tissues, parts with intensive or weak microcirculation (ischemia, arterial and venous hyperemia) unambiguously to objectivate and qualitatively to interpret presence of tissues in organs with different density (tumors, cirrhosis, postmyocardial infarction cicatrices, edema of tissues, calcifications) that can be subjectively and not always distinguished on the black-and-white image and also level of their microcirculation.

This ideology has only partial development in the technology of elastography in some ultrasound systems, but did not fully reveal its potential.

Technology formation requires time, labor and financial resources to create a high-quality, intelligent product that would allow ultrasound and MRI specialists to receive reliable expert-level analytical information.

Perhaps this will happen in the near future, when the society will definitely depart from medical instrument development, and will move on to the development and sale of medical technological sets [27].

3.15. Comparative characteristics of informative features of some investigating methods in Macro-Micro-Angiology

We were trying to describe in brief the methodology of the intravital examination of the vascular system. It is typical that such number of investigating methods causes the sensation of bewilderment concerning the choice of the required equipment and the wish to have all above-mentioned one simultaneously.

However gradually the life arranges everything: resources are usually not enough,

equipment becomes morally and physically outdated and only profound knowledge of basics of hemodynamics can compensate the insufficient number of the equipment supply with the formulation of correct diagnosis.

Therefore, we decided to share our experience and to formulate some algorithms of selection of the necessary diagnostic equipment or consequence of performing the study from screening to final diagnosis pathohemodynamically substantiated.

1. Let' start with the initial diagnostics – stage of screening of the distal links of blood supply on the microlevel. According to the logic the assessment of a link in the vascular bed that is the most distant from the heart – the periphery of blood supply. This can be realized by two means: 1 – assessment of the microcirculation level (optic or computed capillaroscopy); 2 – assessment of impairments of passing of the pulsate wave (sphygmography, computed pletismography). That is the usage of the methods that can answer for the question concerning global disorders in blood supply in the vascular conglomerate the heart – vascular bed.

2. Next stage – search for causes of disorders in blood supply – stage of the pathohemodynamic factors on the macrolevel: examination of the pumping function of the myocardium and condition of the major vessels in the human organism. Here naturally we can assign screening and specific levels.

At the screening level the method of the ultrasound dopplerography is the most informative, which enables to detect with high accuracy disorders of blood supply in a segment of the blood carrying bed, suspect stenosing-occlusive injuries or aneurysmal formation in a certain segment of the artery.

Next specific level – specifying the character of the injury of the vascular wall with the help of its ultrasound scanning and investigation of the vessel's permeability. On this stage it is succeeded to detect with 80-90% reliability atherosclerotic plaques, thrombotic masses in the lumen of the vascular wall that hinder an adequate blood supply for an organ, and apart (distal places of location of a certain segment of the artery or vein).

3. Stage of the precise diagnostics – the stage of proving demonstration. High-technological methods for investigation: radiopaque angiography, magneto-resonance tomography in the angiomode, USD-equipment of the experimental class. Only these methods can unambiguously confirm the pathology detected on the second stage and helps to make a decision concerning the choice of the certain tactics for the operating treatment.

The methods of capillaroscopy and USDG are quite sensitive and informative regarding assessment of lack of the blood supply in the projection of the major arteries of the head and in the microcirculatory bed. As according to the ontogenesis laws capillaries of the nail bed

and capillaries of the cerebral cortex are formed in one gestation period so their likeness has been proved. Thus we indirectly can judge about the condition of blood supply for the cerebral cortex.

Our experience of treatment patient of the psychoneurological profile has shown the validity of the approach. We have formed the following postulate in our practice: if the pumping function of the myocardium, condition of the major blood supply and condition of the microcirculation correspond to the norm so functioning of the hemodynamic system is stable. Therefore, it can “resist” and adequately react to pathological factors of influencing of the environment. We can send this patient home under the clinical observation without prescription of vasoactive agents. Besides, we can be absolutely sure in relative safety of functioning of its hemodynamic system. Even in patients with epilepsy the hemodynamic system, which was led to stability of all parameters, didn’t miss the rhythm and didn’t provoke convulsive paroxysms after having the procedure and acute respiratory disease.

Table 1. Comparative characteristics of the informative characteristics of investigation of the vascular system (in percentages)

Criteria of the informative characteristics	MRA	AG	USAS	USDG
Resolution (segment of an artery/vein)	Visible regional	Visible within the reservoir	Segmental	Local-regional
Sensitivity to deficiency of the cerebral circulation	83	87	60	89
Specificity	60	56	93	91
Hydrodynamic signs of ICH	-	-	-	100
Hemodynamic importance for CVD	53	50	65	100
Stenosis lesion of major arteries	34	95	93	74
Collateralization	95	98	36	94
Changes of elasticity of the vascular wall	-	-	48	100
Changes of tonus of the vascular wall	-	-	26	99
Steal-syndrome	54	95	38	75
Condition of the arteriovenous balance	33	30	24	100
Venous dyschemia	57	Venography 57	47	98

Data from the table 1 show that every method for investigation of the vascular system has its advantages. Therefore, it is necessary to unite them in the complex.

USDG can be considered as a screening method of diagnostics of the hemodynamically indicated pathology, it is highly sensitive under various dyshemias in the proximal segments of major arteries and veins in the head and the neck.

4. Conclusion

If we investigate profoundly every method of examination of the condition of the vascular system, then unambiguously we can say that all they are necessary for the completed diagnostics of the vascular bed injury. The difference is in assessment way – survey or local, a caliber of the vessel or circulation, pressure or volumetric blood flow, perivascular edema or extravasal compression of the artery, one-moment assessment of function of the artery and vein that follows it can be defined.

As we can see all above-mentioned methods have both advantages and disadvantages and certain limitations in adoption. The choice of one or another algorithm of observation depends only on level of intellect of a doctor and necessity in the depth of diagnostics. Of course, if one doesn't have lack of knowledge for assessment of the seen image the best he will assess the potential to examine different aspects of blood supply.

Therefore, today in the age of digital technology it is required not only medical devices for visualizing vascular pathology, but also powerful software products for in vivo visualization of vascular pathology and monitoring the dynamics of all necessary processes that are important for a practitioner and clinician during treatment of a particular patient.

Thus, the modern level of medical technology allows visualization virtually the whole cardiovascular system, not arterial or venous channel, with non-invasive or X-ray diffraction agents.

However, it should be emphasized that CT-MRT technology in the angio-mode allows visualizing the vascular regional channel for the subject of gross structural changes in angioarchitectonics, stenotic-occlusive processes, which often require surgical intervention by an angiosurgeons or a vascular neurosurgeon.

At the same time, the disadvantage of these technologies is static images that do not always fully reflect problems in the hemodynamics of CVS, since it is a dynamic system of vascular blood flow.

Therefore, from the standpoint of dynamism, visualization methods that are capable for analytically processing information and providing counselling assistance to a practitioner

in the process of personalized angiotherapy and angiocorrection are more prioritized in the evidence base of the therapeutic Macro-Micro-Angiology. The first such smart technologies are the capillaroscopy in the model of vascular screening technology and the transformation of USDG in angioma marker technology due to the extensive knowledge base of expert-level, which is the basis of automated software to formulate conclusions of the clinical interpretation of detected vascular changes in a particular patient.

Such vascular dynamical methods require further development in technological complexes with the possibility of obtaining a completed and reliable conclusion with clinical interpretation, which is understood by a practical physician and algorithms for using vascular innovative technologies in personalized angiocorrection and angiotherapy.

References

1. Becker RC. COVID-19 update: Covid-19-associated coagulopathy. *J Thromb Thrombolysis*. 2020;50(1):54-67.
2. Galen Wikipedia.
3. Lushchyk UB, Novytskyy VV, LushchykNG, BabiyIP, Alexeyeva TS. The Up-to-date Potential of an Integrated Functional Estimation of the Arteriovenous Balance in the Closed Vascular System on the Macro- and Microlevel (popular functional angiology: from main arteries through capillaries to main veins). Kyiv: Istyna. 2006: 120.
4. Lushchyk U. Method of regional angioarchitectonics evaluation: State Patent of Ukraine. No. 67707?. 2003.
5. Saxena V. A noninvasive, multimodality approach based on MRS and MRI techniques for monitoring intracranial brain tumor angiogenesis Applied Imagery and Pattern Recognition Workshop. 2005.
6. Emmanuel Deshayes, Vincent Dunet, Curzio Rüegg, Prior JO. Neoangiogenesis imaging in nuclear medicine. *Medecine Nucleaire*. 2012.
7. Matthew R Dreher, Wenge Liu, Charles R Michelich, Mark W Dewhirst, Fan Yuan, Ashutosh Chilkoti. Tumor Vascular Permeability, Accumulation, and Penetration of Macromolecular Drug Carriers. *JNCI: Journal of the National Cancer Institute*. 2006; 98: 335–344.
8. Ribatti D. Judah Folkman, a pioneer in the study of angiogenesis. *Angiogenesis*. 2008; 11: 3-10.
9. Raphael Müller, Tyler Weirick, David John, Giuseppe Militello, Wei Chen, Stefanie Dimmeler, et al. ANGIOGENES: knowledge database for protein-coding and noncoding RNA genes in endothelial cells. 2016.
10. Nadia Alfaidy. Placenta: glande endocrine, cas de l'endocrine gland derived endothelial growth factor (EG-VEGF). *Annales d'Endocrinologie*. 2014; 75: 254–255.
11. Francesca Amoroso, Miere A, Semoun O, Jung C, Capuano V, Souied EH. Optical coherence tomography angiography reproducibility of lesion size measurements in neovascular age-related macular degeneration (AMD). *British Journal of Ophthalmology*. 2018.
12. Abhilash Guduru, et al. Optical coherence tomography angiography characterisation of Best disease and associated choroidal neovascularization. *British Journal of Ophthalmology*. 2017.
13. Stephen Metcalf, HardevPandha, Richard Morgan. Antiangiogenic effects of zoledronate on cancer neovasculature. *Future Oncology*. 2011; 7: 1325-1333.
14. Paltsyv MA, Anichkov NM. Pathological anatomy, M. Medicine. 2001: 680.

15. DaCosta ML, Regan MC, al Sader M, Leader M, Bouchier-Hayes D. Diphenylhydantoin sodium promotes early and marked angiogenesis and results in increased collagen deposition and tensile strength in healing wounds. *Surgery*. 1998; 123: 287-293.
16. Tuncel A, Serin M, Bayramicli M. Venous component in scar penetrating neovascularisation. *J PlastSurg Hand Surg*. 2017; 9: 1-6.
17. Shalini Sanyal, et al. Chronic pesticide exposure and consequential keratectasia& corneal neovascularisation. Article in *Experimental Eye Research*. 2017; 164.
18. Tsutomu Oikawa. Control of tumor-related angiogenesis. *Human Cell*. 1999; 11: 201-206.
19. UB Lushchyk Vascular innovations in oncology and neoangiogenesis.
20. Khomenko EV, Oryabinska LB, Minchenko OG. Vascular endothelial growth factor: biology and therapeutical importance. *Problems of ecological and medical genetics and clinical immunology*. 2012; 5: 119-1131.
21. Olga Golubnitschaja, et al. Flammer Syndrome and potential formation of pre-metastatic niches: A multi-centred study on phenotyping, patient stratification, prediction and potential prevention of aggressive breast cancer and metastatic disease. Conference paper EPMA-World Congress. 2015.
22. Lushchyk, et al. IT- technology for vascular monitoring in prevention and prediction of the oncopathology. *EPMA Journal*. 2014; 5: A64.
23. Lushchyk UB. «Blind» Doppler for clinical Intellectuals (qualitative assessment of cerebral dyshemias). *Istyna: SMCUMD*. 2004: 264.
24. Guerrero-Vargas NN, et al. Circadian disruption promotes tumor growth by anabolic host metabolism; experimental evidence in a rat model. *BMC Cancer*. 2017; 17: 625.
25. MINDY WAIZER Exploring the Link Between Stroke and Cancer Curetoday. 2017.
26. Mohammed A Abdelsaid, et al. Enhanced VEGF signalling mediates cerebral neovascularisation via downregulation of guidance protein ROBO4 in a rat model of diabetes. *Diabetologia*. 2017.
27. Lushchyk UB, Novytskyy VV. Modern medical technology in analytic angiology. *Kyiv*. 2011: 120.
28. Lushchyk UB, Novytskyy VV. Some Aspects of the Applied Hemodynamics in the Epoch of the Intravital Visualizing Technologies. *Istyna: SMCUMD*. 2006: 36.
29. Lushchyk UB, Novytskyy VV, Alexeyeva TS, Francevich KA, Branytska NS. Analytical aspects of an individual hemodynamic correction in the angioneurology. *Kyiv: Istyna*. 2006: 130.
30. Lushchyk, et al. Predictive and preventive strategies to advance the treatments of cardiovascular and cerebrovascular diseases: the Ukrainian context. *The EPMA Journal*. 2012; 3: 12.
31. Lushchyk UB, Novytskyy VV. Theory of the vascular blood duct: logics and vectors of influence on a vascular pathology in angiosurgery and angiotherapy. *Vascular surgeon*. 2013.
32. Koch, Edouard, et al. “Morphometric Analysis of Small Arteries in the Human Retina Using Adaptive Optics Imaging: Relationship with Blood Pressure and Focal Vascular Changes.” *Journal of Hypertension*. 2014; 32: 890–898.
33. Gasljevic, Gorana, et al. “Histopathological Findings in Colorectal Liver Metastases after Electrochemotherapy.” *Ed. Obul Reddy Bandapalli. PLoS ONE*. 2017; 12: e0180709.
34. Holzer W, Polzer K, Marko A. Rheokardiographie. Maudrich, Wien
35. K. POLZER, F. SCHUHFRIED, AND H. HEEGER Cardiac Department of the Hanusch-Hospital, Vienna:1958

<https://www.ncbi.nlm.nih.gov/pmc/articles/PMC1017636/pdf/brheartj00366-0144.pdf>

36. Garrod AH. On Sphygmography. *Journal of Anatomy and Physiology*. 1872; 6: 399-404.
37. Micheels J, Alsbjorn B, Sorensen B. Laser doppler flowmetry. A new non-invasive measurement of microcirculation in intensive care? *Resuscitation*. 1984; 12: 31-39.
38. Hwang CS, Yang SP, Jang KW, Park JW, Jeong KH. Angle-selective optical filter for highly sensitive reflection photoplethysmogram. *Biomed Opt Express*. 2017; 8: 4361-4368.
39. Baek HJ, Shin J, Jin G, Cho J. Reliability of the Parabola Approximation Method in Heart Rate Variability Analysis Using Low-Sampling- Rate Photoplethysmography. *J Med Syst*. 2017; 41: 189.
40. Patel Z, Thaha MA, Kyriacou PA. Development of an intraluminal intestinal photoplethysmography sensor. *Conf Proc IEEE Eng Med Biol Soc*. 2017; 1840-1843.
41. Wolfe TW, Coin CG, Boles GW, Kearns HJ, Hallum GD. ECHOENCEPHALOGRAPHY. *J Okla State Med Assoc*. 1964; 57: 484-8.
42. Bulakhova LO. Capillaroscopic Observations for Certain Mental Illnesses / *Physiological Journal of the Academy of Sciences of the USSR*. 1955; 97-103.
43. Lushchik, et al. Screening of vascular pathologies – evidence-based monitoring of prevention efficiency. *EPMA Journal*. 2014; 5: A91.
44. Lushchik UB, Novytskyy VV, Kolosova JA. Up-to-date potential of the capillaroscopy *Istyna*. 2004: 36.
45. Lushchik U. Device for capillary circulation registration: State Patent of Ukraine. 2007.
46. Lushchik U. Device for the vascular screening. Patent No. 2013
47. Lushchik, et al. IT- technology for vascular monitoring as an evidential base in prevention and prediction of a vascular pathology. *EPMA Journal*. 2014; 5: A64.
48. Scintigraphy. From Wikipedia, <https://en.wikipedia.org/wiki/Scintigraphy>
49. Digital subtraction angiography. Wikipedia. https://en.wikipedia.org/wiki/Digital_subtraction_angiography
50. Kuninaka H, et al. Use of postmortem computed tomography angiography to detect vascular injuries accompanying skull base fracture. *Leg Med (Tokyo)*. 2016; 23: 55-58.
51. Lushchik U. Method of ultrasound diagnosis of cerebral vessels: State Patent of Ukraine. 1995.
52. Lushchik, et al. A Mathematical Model of the Background Functioning of a Living Organism Conference Paper, 34 Congress of Neurootological and Equilibriometric Society. 2007.
53. Lushchik et al. A project of harmonious health renewal in psychoneurological patients on the basis of the personalized algorithms for treatment and rehabilitation. *EPMA Journal*. 2013; 5.
54. Lushchik, et al. Medical management in the personalized renewal of the brain dysfunctions Conference Paper. *EPMA Congress*. 2015.
55. Lushchik UB. Macro- and Microlevel of Noninvasive Examination of the Vascular System. 2015.
56. Lushchik UB. Some Aspects of the Applied Hemodynamics in Diagnostic Angiology. 2015.
57. Lushchik UB. The personalized angiotherapy as a predictive approach to renewal of the cardiovascular system Conference Paper. *EPMA Congress*. 2015.

58. Lushchik UB. Models for Living Organism's Functioning at Normal and Pathological Conditions.
59. Computed tomography.
60. Magnetic resonance imaging.
61. Magnetic resonance angiography.
62. Essig M, Nguyen TB, Shiroishi MS, et al. Perfusion MRI: The Five Most Frequently Asked Clinical Questions. *AJR American journal of roentgenology*. 2013; 201.
63. Lushchik U. Method of assessment of a grey-scaled scanned image: State Patent of Ukraine. No. 67708 A as of 31.12.03