

Kidney Transplantation

Chapter 4

Laparoscopic Surgery for Live Donor Nephrectomy

Bulang He

Clinical Associate Professor, The University of Western Australia, Consultant Transplant Surgeon, Sir Charles Gairdner Hospital, Australia.

Email: Bulang.He@health.wa.gov.au

1. Introduction

Laparoscopic surgery for live donor nephrectomy has been well implemented in kidney transplant centres around the world since mid 1990s [1-3]. It has been demonstrated that laparoscopic surgery has the advantage of smaller incision, less pain, quicker recovery and better cosmetic appearance and comparable kidney graft function when compared with conventional open surgery [2,4-6]. There are various surgical techniques with two major approaches transperitoneal laparoscopy and retroperitoneal retroperitoneoscopy. Hand assistance to each of these two approaches has also been widely employed. There is no large clinical trial to demonstrate which technique is superior to another, although some literature reviews have found there is a tendency of less blood transfusion, less vessel injury, less conversion to open surgery and less delayed graft function rate in retroperitoneoscopic approach [7,8]. However, the papers included in these literature reviews have a high heterogeneity and the interpretation of the results has to be with caution. As it is well understood that live donor nephrectomy is a very technical demanding surgery as the donor is a healthy person to undergo a major surgery for others benefits. There is a zero tolerance of any complications from surgery of live donor nephrectomy. Nevertheless, from large cohort studies and reviews, the major complication with Clavien Grade III or higher have been reported about 7.3%, while all complications were about 17% from laparoscopic live donor nephrectomy [9,10]. Therefore, a proper training and supervision of the surgical technique is fundamental for live donor nephrectomy by laparoscopic surgery. This chapter will overview the techniques for laparoscopic and retroperitoneoscopic live donor nephrectomy. The advantage and disadvantage of each technique and the prevention and management of the complications will be also discussed.

2. Assessment of Live Kidney Donor

It is essential for a potential donor to undergo a rigorous assessment of the suitability for a kidney donation in the setting of a multidisciplinary team. Many guidelines have been established by various nations. The key points are summarized below [11-15].

Assessment of a potential live kidney donor should be in a planned logical structure to avoid inconvenience and minimize the travels to the hospital. The potential donor should be fully supported emotionally and socially at all times. The past and present medical history should be taken with focus on these diseases:

Hypertension, Diabetes, Kidney stones, Urological disorder

Infection disease: (Sexual transmission disease, HIV, Hepatitis B, Hepatitis C, Tuberculosis, Malaria and other geographical featured parasite infection disease)

Malignant disease, Cardiovascular disease, Respiratory disorder, Mental health and social condition

Assessment of kidney function:

It is fundamental to measure Glomerular filtration rate (GFR) for assessment of kidney function during workup. The threshold of GFR for consideration of kidney donation is $> 80\text{ml}/\text{minute}/1.73\text{M}^2$. There is a justification for GFR based on gender and age from UK guideline as below:

https://bts.org.uk/wp-content/uploads/2018/01/BTS_LDKT_UK_Guidelines_2018_Consultation_Draft.pdf

Age and Gender-Specific GFR based on almost 3000 Healthy Potential UK living kidney donors

Age(years)	Measured GFR (mL/min/1.73m ²)	
	Male	Female
20-29	100 (74-126)	98 (72-125)
30-34	100 (74-126)	98 (72-125)
35	99 (73-126)	98 (72-125)
40	96 (70-122)	94 (68-121)
45	93 (67-119)	91 (64-117)
50	90 (63-116)	87 (60-113)
55	86 (60-112)	83 (56-109)
60	83 (57-109)	79 (52-105)
65	80 (54-106)	75 (48-101)
70	76 (50-102)	71 (44-97)
75	73 (47-99)	67 (40-94)
80	70 (44-96)	63 (36-90)

Donor Age:

Most transplant centers do have concerns for potential donor with age < 21 years old due to their long life after donation and considered as relative contraindication. The donor of age < 18 is not considered for donation. There is no upper age limit for live kidney donation. Extra care must be taken for donors age > 60 years as increased risk of perioperative complications.

Donor obesity:

It is recommended that the donor's BMI should be < 30 kg/M²; the donation should be discouraged if the BMI >35 kg/M². Further discussion should be made for donation with effort to lose body weight if BMI is between 30-35 kg/M².

Proteinuria:

Albumin excretion > 300mg/day or protein excretion > 500mg/day is absolute contraindication for kidney donation.

Screening of infection diseases:

Routine screening includes HIV, HCV, HBV, EBV, CMV, Herpes Simplex and Toxoplasmosis. Additional screening may be necessary subject to local epidemiology of infection disease

Screening of malignancy: The screening test should be based on local epidemiology and use similar protocol for cancer screening in general population.

Surgical imaging: Multidetector computed Tomography Angiography (CTA) has been widely used in live donor work up for kidney anatomical study since late 1990's. The accuracy for even small accessory artery is about 95%-100% [16,17]. Other pathologies can also be identified on CTA if present such as renal cyst or renal mass lesion. Renal collecting system can be better visualized by a delayed phase while the contrast is excreted into the collecting system or taking an abdominal x-ray film including kidney, ureter and bladder (KUB) immediately post CTA [18]. Alternately, Magnetic Resonance Angiography (MRA) can be used for live kidney donor work up if CTA is contraindicated for the potential donor. The accuracy for small vessels by MRA is inferior to CTA [19].

3. Surgical Techniques

3.1. Trans peritoneal Laparoscopic Live Donor Nephrectomy (Take left as an example): [20].

The patient is under general anesthesia with endotracheal intubation and a urethral

catheter inserted. The patient is secured in a flexed, lateral decubitus position with left side up and careful padding at pressure area. One dose of antibiotics (Cefazolin 1.0 gram IV) is given at induction. Heparin 5000 IU is injected subcutaneously. Mannitol (20 grams) is given intravenously about 30 minutes prior to renal vessel division.

After prep and drape, a small incision (2 cm) is made at the ipsilateral mid-clavicular line cranial to umbilicus for the camera Hasson port and a pneumo-peritoneum is established. A 30 degrees scope is inserted via the Hasson port and inspection of the intra peritoneal organs is conducted. A 5-mm/12 mm port is inserted under vision at the site below the costal line for the left hand and A 12 mm port is inserted for right hand at the site forming a working triangular shape with other 2 ports. Sometimes, a fourth port may be required for retraction if exposure of renal hilum is difficult. It is usually placed via the left flank under the vision.

A dissection is commenced by incising the white line of Toldt and the descending colon is mobilized medially (**Figure 1**). The kidney is exposed and the ureter is identified. The bundle of ureter with gonadal vein is lifted up with left hand instrument (**Figure 2**). The dissection is continued along with the gonadal vein leading towards the renal vein. The anterior tissue over the renal vein is dissected and the adrenal vein is identified and divided. The lumbar veins are dissected and divided for better exposure the renal artery. The renal artery is then further dissected free from surrounding tissues. After completion of the renal vein and renal artery dissection (**Figure 3**), the ureter is divided at the level of iliac vessels with the gonadal vein. The gonadal vein may be left behind without taking with the ureter [21]. The kidney is mobilized free from the attachment. Care is taken around the upper pole area avoid accidental injury to the spleen, pancreas and pleura.

After mobilization of the kidney, a small incision is made at the left iliac fossa for delivery of the kidney graft. Sometimes a Pfannenstiel incision may be used as alternative. The Endocatch bag is introduced via the corner of the small incision and the kidney is placed in the bag. The Endo-TA vascular stapler is used to secure the renal artery (**Figure 4**). Two large Hem-o-lok (locking polymer clips) are used to secure the renal vein (**Figure 5**). Then renal pedicle is divided and the kidney is delivered in the bag via the small incision.

The kidney is perfused immediately with cold (4 °C) UW solution (UW 1 L + 10, 1000 IU of heparin) while immersed in the ice slush on the back table. The kidney is prepared and excessive fat tissue is cleaned on the back table for transplantation.

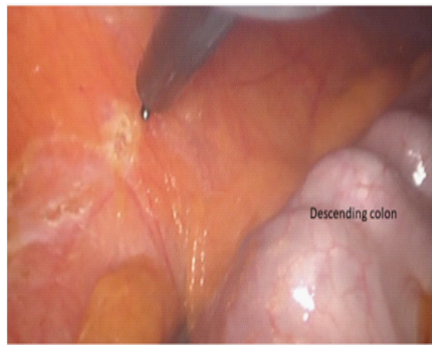


Figure 1: The white line of Toldt is incised and the descending colon mobilized medially

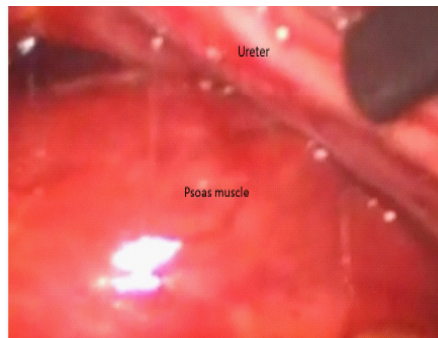


Figure 2: The ureter identified and dissected towards renal hilum

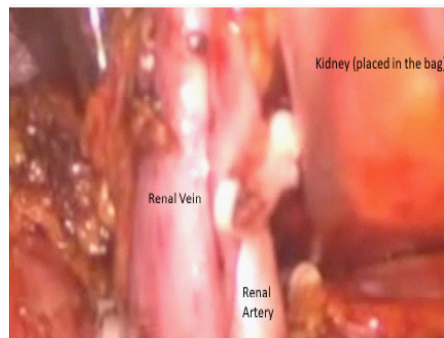


Figure 3: The Renal artery and renal vein dissected

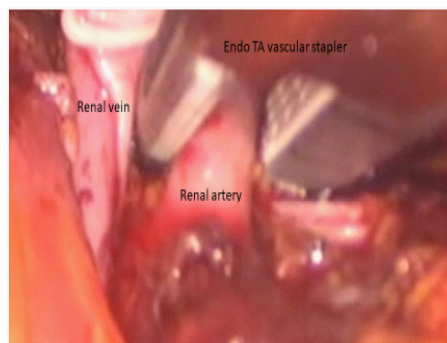


Figure 4: The Renal artery secured with Endo TA vascular stapler

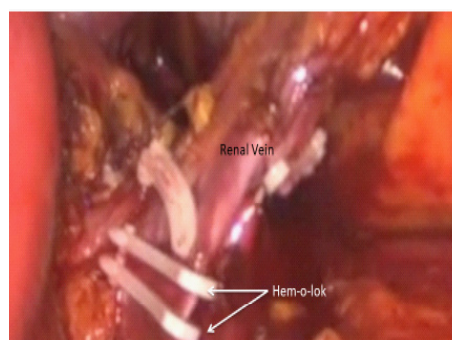


Figure 5: The Renal vein secured with large hem-o-lok x 2

3.2. Hand-assisted laparoscopic donor nephrectomy

Hand assistance is a modification to the pure laparoscopy. It is felt easier with a hand in situ for helping the dissection and ready for controlling bleeding if it occurs. Some studies have shown the kidney graft warm ischemic time is shorter by hand assistance [22]. But, the length of hospital stay is longer and estimated blood loss from the surgery is greater than pure laparoscopic technique [23]. However, these conclusions are controversial from different studies. It is understood many transplant units have employed this hand-assistance technique [24-28].

3.3. Retroperitoneoscopic live donor nephrectomy

Retroperitoneoscopic live donor nephrectomy was first reported by Yang et al in 1994 [29]. But it has not been widely employed. From the literature, it is learnt that most of Asian countries and some of European countries are in favor of this approach. Retroperitoneoscopic approach has the advantage of quick access to renal vessels, better visualization of the lumbar veins, avoid violating intra abdominal organs. The kidney graft function is comparable to those by transperitoneal laparoscopic approach [30]. Recently, there seems to be an increase in recognition of retroperitoneoscopic live donor nephrectomy [7,8,31-33].

Surgical technique (Take the left side as an example): [34,35]

One dose of prophylaxis antibiotics (Cefazolin 1.0 gram) is given intravenously. Heparin 5000 IU is injected subcutaneously after intubation.

The patient is secured in a flexed, decubitus position with left side up. A small incision is made at the media axillary line, 1 cm below the 12th rib. The diathermy is used to cut the muscular layer and the lumbar dorsal fascia until the retroperitoneal fat is encountered. The retroperitoneal space is created by a gentle dissection with an index finger followed by insertion of a balloon dilator to the retroperitoneal space. A 0° scope is placed inside of the balloon dilator and the working space is created with peritoneum pushed medially by inflation of the balloon under vision. The ureter is often visualized with its peristalsis (Figure 6). The balloon dilator is replaced with a Hanson balloon port for camera. The pneumo-retroperitoneum is established per laparoscopic surgery. A 12 mm port is inserted at the site 3 fingers anterior to the camera port under vision for the left hand instrument. Another 12 mm port is placed under vision at the renal angle 3 fingers posterior to the camera port for the right hand.

The dissection is started by incising the Gerota fascia towards the upper pole of the kidney in parallel with the Psoas muscle. The perinephrectic fat and the proximal ureter are exposed (Figure 7). A fan retractor is usually used to lift kidney medially. The renal pedicle is inspected by visualizing the pulsation of the renal artery. The lumbar veins are usually

encountered around the renal artery, which are carefully dissected and divided for better exposure of the renal artery. The renal artery is further dissected free from surrounding tissues with caution. The renal vein is then dissected free from the surrounding tissues. The gonadal vein is seen inferiorly joining to the renal vein. The gonadal vein can be divided by Ligasure or remain attached to the renal vein.

At this stage, the kidney is mobilized free from its attachments. In some donors, the posterior perinephrectic fat could be excised to give a better vision during mobilization of the kidney. The upper pole of the kidney is dissected moving towards anterior aspect of the kidney. The focus at this stage is to identify the adrenal vein, which is then dissected and divided obtaining a better length of the renal vein. The dissection is continued along the anterior aspect of the renal vein towards the lower pole of the kidney anteriorly. The whole kidney, renal artery and renal vein are now completely free from the attachment (Figure 8). The ureter is divided at the level of the iliac vessels. At this stage, a small incision (8 cm) is made at the left iliac fossa for access to the retroperitoneal space for delivery of the kidney graft. Care is taken without breaching the peritoneum. A Gel port is placed over the small incision for easy access to the retroperitoneal space.

Pneumo-retroperitoneum is established again. The kidney is lifted up with a left hand instrument and the renal artery is properly exposed. An Endo-TA vascular stapler is applied to seal the renal artery (Figure 9). For better access to the renal vein, the renal artery is first divided by a pair of endoscopic scissors. Two large Hem-o-loks are applied to seal the renal vein (Figure 10) and the renal vein is divided.

The kidney is free to be removed via the Gel port and perfused immediately with cold UW solution (1L+10, 000 IU of heparin) while immersed in the ice-slush basin. The kidney graft is inspected for quality of perfusion and is prepared for transplantation.

The incision at left iliac fossa is closed first and hemostasis is carefully checked with pneumatic pressure at 6 mmHg. The renal bed is washed with normal saline. The incision and port sites are closed in layers.

4. Surgical Complications and Management

4.1 Perioperative complications

4.1.1. Bleeding

The incidence of perioperative bleeding was reported from 1-17% in the era of laparoscopic live donor nephrectomy, which is slightly higher than the rate of 0.3-3% from open live donor nephrectomy [4,10,36]. Accidental injury to the major vessel may occur during dissection of the renal artery and vein. On the left side, the lumbar veins are often

in large caliber and short. The extra care needs to be taken during dissection and division of them. The incidence of major vessel injury is about 1-3%, which is more likely require conversion to open surgery immediately to avoid the serious consequence [10,26]. About half of the conversion from laparoscopy to open surgery was due to the bleeding [2,26]. The conversion rate ranged from 0% to 13.3 % [4]. The intraoperative transfusion rate was 0-10% for laparoscopic donor nephrectomy while it was 0-5% in open live donor nephrectomy. The post-operative blood transfusion rate is around 1-7%% in the cohort of laparoscopic live donor nephrectomy, whereas it was about 3-5% from open live donor nephrectomy [1,2].

The most critical issue for live donor nephrectomy is how to secure the renal artery. It is recommended to use transfixion device (vascular stapler). Vascular endo-clip or Hem-o-lok is not recommended to use as along for seal the renal artery stump as the risk of massive bleeding

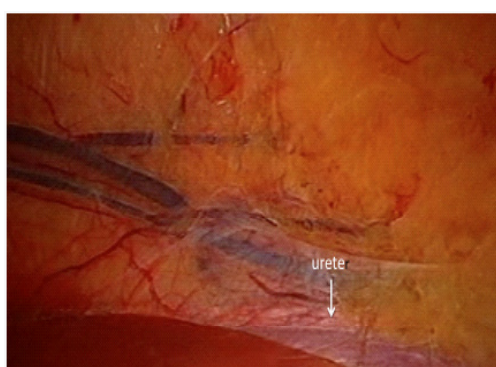


Figure 6: Retroperitoneal working Space created and the ureter visualised

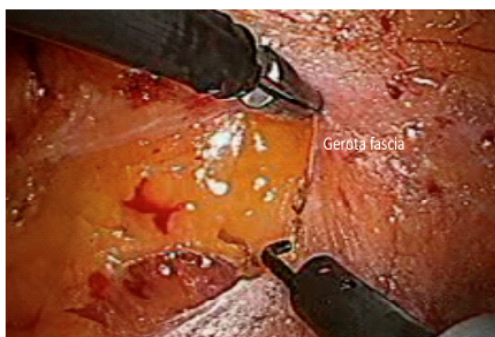


Figure 7: The Gerota Fascia incised towards upper pole of kidney

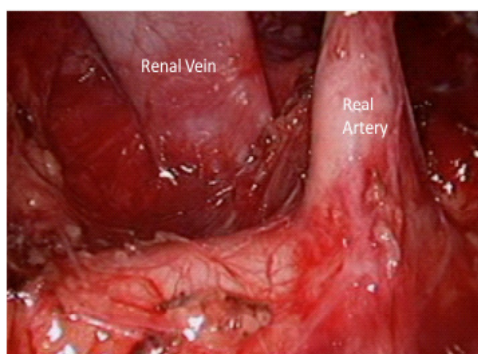


Figure 8: The renal artery and renal vein dissected

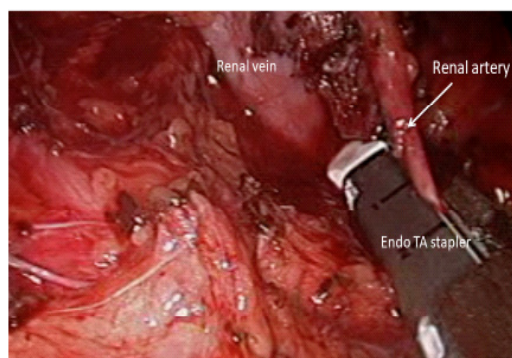


Figure 9: The renal artery secured by Endo TA vascular stapler

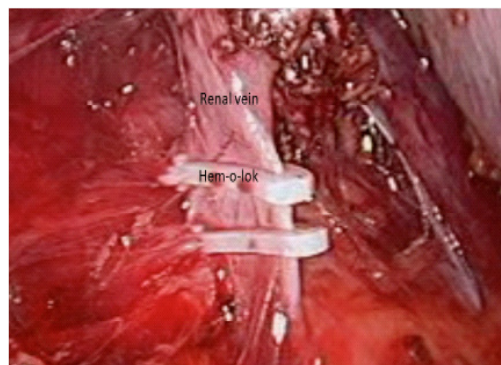


Figure 10: The renal vein secured by large Hem-o-lok x2

if it is dislodged during post-operative period [37,38]. There were some reports of donor death as a result of using non-transfixion device (Hem-o-lok slipped off the renal artery stump) post laparoscopic live donor nephrectomy [37,39]. The Majority of surgeons apply the Endo GIA or Endo TA for renal artery control as the safest technique in a survey from America and Europe [37,40]. However, there were some reports on faulty of the vascular stapler resulting in the jam of the device or malfunction [40-42]. It should be aware that no of these current available devices is perfect for securing the renal artery stump [40]. So to be prepared for further action if this occurs. Nevertheless, it is noted that some studies have reported that the Hem-o-lok is safe and reliable for securing the renal artery for live donor nephrectomy without adverse event [6,43-45]. So the surgeon needs to make sure which device he or she felt confident to apply for live donor nephrectomy.

The mortality rate for laparoscopic live donor nephrectomy is about 0.03%, one major cause is due to bleeding and another one is due to pulmonary embolism (PE) [2,4,10]. This mortality rate of 0.03% has not changed since the era of open live donor nephrectomy [4,20,24]. PE may occur even two weeks after discharge. Therefore, it is important to have a strict protocol for prophylaxis of DVT/PE for 4 weeks after surgery [46,47]. In our practice, the donor is routinely given Clexane 40 mg subcutaneously daily injection for 4 weeks after discharge [20].

4.1.2. Adjacent organ injury

Adjacent organs can be injured during the dissection of the kidney. On the left side, the splenic laceration has been reported about 1-2% [7,10]. It may result in a large hematoma

formation or requirement of splenectomy. The bowel injury and perforation have also been reported [10]. The bowel obstruction, ileus and internal hernia may occur after laparoscopic transperitoneal approach [10,48]. The care must be taken during the procedure when the instrument is inserted into the operation field. The tip of instrument should be always kept under vision, in particular when it is in motion. Retroperitoneoscopic approach is superior in this regard as it avoids violation to the intra abdominal organs [7,8]. Bladder injury has been reported when Pfannenstiel incision is used for delivery of the kidney graft [49].

4.1.3. Kidney graft injury

Kidney graft can be injured during the dissection with instrument causing hematoma or laceration of the kidney. At the early era of laparoscopic live donor nephrectomy, some kidney grafts were lost as a result of accidental injury to the vascular structure, which is not amenable for transplantation. The kidney graft can be fractured by Endocatch device or by the tight edge of the incision [50,51]. Therefore, care should be taken at all times during handling the kidney graft.

4.1.4 Wound infection and hernia formation

Wound infection rate is very low in live donor nephrectomy. It is usually minor with local erythema or discharge when it occurs. This minor infection is often resolved satisfactorily by local wound care and oral antibiotics treatment. The incidence of incisional hernia from the small incision is about 2-4% [52-57]. The major wound infection is a risk for hernia formation. For Hanson port, the muscular layer closure is required to prevent hernia formation. For other ports, the fascia and subcutaneous fat closure are efficient to prevent hernia prior to skin closure. For the small incision of delivery the kidney, proper layer closure is important to recover the anatomical structure and prevent hernia formation.

4.1.5 Chyle leak or Chylous Ascites

Chyle leak or Chylous ascites is a rare complication following laparoscopic or retroperitoneoscopic live donor nephrectomy. The incidence was reported from 1% - 3.8 % [58]. The cause of chyle leak is due to the unsealed lymphatic tubes after division during the dissection of the renal pedicle. If a large lymphatic trunk is not sealed during the dissection, some milk like chyle fluid can be seen in the surgical field. The care should be taken to stop this leakage before completion of the surgery to prevent chylous ascites. The occurrence of chyle leak or chylous ascites ranges from day 1 to day 45 after surgery. It is associated with increase of diet with the progress of recovery. For mild to moderate chyle leak < 800 mL /24 hours. The patient is required on low fat diet for 1- 2 weeks. The drain is remained in situ and the volume is monitored on daily basis. Octreotide 100µg subcutaneous injection 3 times a day is recommended. A dietician should be involved to give patient education regarding the oral

intake. Most time, the patient will recover without further consequence. For severe Chylous ascites > 800 ml/24 hours, the patient should be restricted without any food by mouth but water only. The TPN should be commenced immediately. The patient is closely monitored the progress and the response to the treatment. Surgical exploration and sealing of the leakage should be considered if the drain is ongoing with high volume. Extra care is required for severe chylous ascites to prevent malnutrition and infection [58-60].

5. References

1. Wilson CH, Sanni A, Rix DA, Soomro NA. Laparoscopic versus open nephrectomy for live kidney donors. The Cochrane database of systematic reviews 2011:CD006124.
2. Fonouni H, Mehrabi A, Golriz M, et al. Comparison of the laparoscopic versus open live donor nephrectomy: an overview of surgical complications and outcome. *Langenbeck's archives of surgery / Deutsche Gesellschaft fur Chirurgie* 2014;399:543-51.
3. Ratner LE, Montgomery RA, Kavoussi LR. Laparoscopic live donor nephrectomy. A review of the first 5 years. *The Urologic clinics of North America* 2001;28:709-19.
4. Shokeir AA. Open versus laparoscopic live donor nephrectomy: a focus on the safety of donors and the need for a donor registry. *The Journal of urology* 2007;178:1860-6.
5. Simforoosh N, Basiri A, Shakhssalim N, et al. Long-term graft function in a randomized clinical trial comparing laparoscopic versus open donor nephrectomy. *Experimental and clinical transplantation : official journal of the Middle East Society for Organ Transplantation* 2012;10:428-32.
6. Mansour AM, El-Nahas AR, Ali-El-Dein B, et al. Enhanced Recovery Open vs Laparoscopic Left Donor Nephrectomy: A Randomized Controlled Trial. *Urology* 2017;110:98-103.
7. He B, Bremner A, Han Y, Hamdorf JM. Determining the Superior Technique for Living-donor Nephrectomy: the Laparoscopic Intraperitoneal Versus the Retroperitoneoscopic Approach. *Experimental and clinical transplantation : official journal of the Middle East Society for Organ Transplantation* 2016;14:129-38.
8. Ozdemir-van Brunschot DM, Koning GG, van Laarhoven KC, et al. A comparison of technique modifications in laparoscopic donor nephrectomy: a systematic review and meta-analysis. *PloS one* 2015;10:e0121131.
9. Kortram K, Ijzermans JN, Dor FJ. Perioperative Events and Complications in Minimally Invasive Live Donor Nephrectomy: A Systematic Review and Meta-Analysis. *Transplantation* 2016;100:2264-75.
10. Lentine KL, Lam NN, Axelrod D, et al. Perioperative Complications After Living Kidney Donation: A National Study. *American journal of transplantation : official journal of the American Society of Transplantation and the American Society of Transplant Surgeons* 2016;16:1848-57.
11. Arunachalam C, Garrues M, Biggins F, Woywodt A, Ahmed A. Assessment of living kidney donors and adherence to national live donor guidelines in the UK. *Nephrology, dialysis, transplantation : official publication of the European Dialysis and Transplant Association - European Renal Association* 2013;28:1952-60.
12. Meyer KB, Bjork IT, Wahl AK, Lennerling A, Andersen MH. Long-term experiences of Norwegian live kidney donors: qualitative in-depth interviews. *BMJ open* 2017;7:e014072.
13. Janki S, Klop KW, Dooper IM, Weimar W, Ijzermans JN, Kok NF. More than a decade after live donor nephrectomy: a prospective cohort study. *Transplant international : official journal of the European Society for Organ Transplantation* 2015;28:1268-75.

14. Muzaale AD, Massie AB, Wang MC, et al. Risk of end-stage renal disease following live kidney donation. *JAMA : the journal of the American Medical Association* 2014;311:579-86.
15. Lentine KL, Kasiske BL, Levey AS, et al. KDIGO Clinical Practice Guideline on the Evaluation and Care of Living Kidney Donors. *Transplantation* 2017;101:S1-S109.
16. Kapoor A, Kapoor A, Mahajan G, Singh A, Sarin P. Multispiral computed tomographic angiography of renal arteries of live potential renal donors: a review of 118 cases. *Transplantation* 2004;77:1535-9.
17. Laugharne M, Haslam E, Archer L, et al. Multidetector CT angiography in live donor renal transplantation: experience from 156 consecutive cases at a single centre. *Transplant international : official journal of the European Society for Organ Transplantation* 2007;20:156-66.
18. Holden A, Smith A, Dukes P, Pilmore H, Yasutomi M. Assessment of 100 live potential renal donors for laparoscopic nephrectomy with multi-detector row helical CT. *Radiology* 2005;237:973-80.
19. Asgari MA, Dadkhah F, Ghadian AR, Razzaghi MR, Noorbala MH, Amini E. Evaluation of the vascular anatomy in potential living kidney donors with gadolinium-enhanced magnetic resonance angiography: comparison with digital subtraction angiography and intraoperative findings. *Clinical transplantation* 2011;25:481-5.
20. He B, Mitchell A, Delriviere L, et al. Laparoscopic donor nephrectomy. *ANZ journal of surgery* 2011;81:159-63.
21. Kocak B, Baker TB, Koffron AJ, Leventhal JR. Ureteral complications in the era of laparoscopic living donor nephrectomy: do we need to preserve the gonadal vein with the specimen? *Journal of endourology / Endourological Society* 2010;24:247-51.
22. Nakajima I, Iwadoh K, Koyama I, Tojimbara T, Teraoka S, Fuchinoue S. Nine-yr experience of 700 hand-assisted laparoscopic donor nephrectomies in Japan. *Clinical transplantation* 2012;26:797-807.
23. Ungbhakorn P, Kongchareonsombat W, Leenanupan C, et al. Comparative outcomes of open nephrectomy, hand-assisted laparoscopic nephrectomy, and full laparoscopic nephrectomy for living donors. *Transplantation proceedings* 2012;44:22-5.
24. Greco F, Hoda MR, Alcaraz A, Bachmann A, Hakenberg OW, Fornara P. Laparoscopic living-donor nephrectomy: analysis of the existing literature. *European urology* 2010;58:498-509.
25. Alberts V, Idu MM, Minnee RC. Risk factors for perioperative complications in hand-assisted laparoscopic donor nephrectomy. *Progress in transplantation* 2014;24:192-8.
26. Leventhal JR, Paunescu S, Baker TB, et al. A decade of minimally invasive donation: experience with more than 1200 laparoscopic donor nephrectomies at a single institution. *Clinical transplantation* 2010;24:169-74.
27. Dols LF, Kok NF, Ijzermans JN. Live donor nephrectomy: a review of evidence for surgical techniques. *Transplant international : official journal of the European Society for Organ Transplantation* 2010;23:121-30.
28. Fisher PC, Montgomery JS, Johnston WK, 3rd, Wolf JS, Jr. 200 consecutive hand assisted laparoscopic donor nephrectomies: evolution of operative technique and outcomes. *The Journal of urology* 2006;175:1439-43.
29. Yang SC, Lee DH, Rha KH, Park K. Retroperitoneoscopic living donor nephrectomy: two cases. *Transplantation proceedings* 1994;26:2409.
30. Goldfarb DA. Retroperitoneoscopic live donor nephrectomy (RPLDN): establishment and initial experience of RPLDN at a single center. *The Journal of urology* 2005;174:1018.
31. Elmaraezy A, Abushouk AI, Kamel M, Negida A, Naser O. Should hand-assisted retroperitoneoscopic nephrectomy replace the standard laparoscopic technique for living donor nephrectomy? A meta-analysis. *International journal of surgery* 2017;40:83-90.

32. Dols LF, Kok NF, d'Ancona FC, et al. Randomized controlled trial comparing hand-assisted retroperitoneoscopic versus standard laparoscopic donor nephrectomy. *Transplantation* 2014;97:161-7.
33. Troppmann C, Daily MF, McVicar JP, Troppmann KM, Perez RV. The transition from laparoscopic to retroperitoneoscopic live donor nephrectomy: a matched pair pilot study. *Transplantation* 2010;89:858-63.
34. Tanabe K, Miyamoto N, Ishida H, et al. Retroperitoneoscopic live donor nephrectomy (RPLDN): establishment and initial experience of RPLDN at a single center. *American journal of transplantation : official journal of the American Society of Transplantation and the American Society of Transplant Surgeons* 2005;5:739-45.
35. Ng ZQ, Musk G, Rea A, He B. Transition from laparoscopic to retroperitoneoscopic approach for live donor nephrectomy. *Surgical endoscopy* 2018;32:2793-9.
36. Simforoosh N, Soltani MH, Basiri A, et al. Evolution of laparoscopic live donor nephrectomy: a single-center experience with 1510 cases over 14 years. *Journal of endourology / Endourological Society* 2014;28:34-9.
37. Friedman AL, Peters TG, Jones KW, Boulware LE, Ratner LE. Fatal and nonfatal hemorrhagic complications of living kidney donation. *Annals of surgery* 2006;243:126-30.
38. Friedman AL, Peters TG, Ratner LE. Regulatory failure contributing to deaths of live kidney donors. *American journal of transplantation : official journal of the American Society of Transplantation and the American Society of Transplant Surgeons* 2012;12:829-34.
39. Hsi RS, Ojogho ON, Baldwin DD. Analysis of techniques to secure the renal hilum during laparoscopic donor nephrectomy: review of the FDA database. *Urology* 2009;74:142-7.
40. Janki S, Verver D, Klop KW, et al. Vascular management during live donor nephrectomy: an online survey among transplant surgeons. *American journal of transplantation : official journal of the American Society of Transplantation and the American Society of Transplant Surgeons* 2015;15:1701-7.
41. Chan D, Bishoff JT, Ratner L, Kavoussi LR, Jarrett TW. Endovascular gastrointestinal stapler device malfunction during laparoscopic nephrectomy: early recognition and management. *The Journal of urology* 2000;164:319-21.
42. Cabello R, Garcia JV, Quicios C, Bueno G, Gonzalez C. Is There a New Alternative for a Safer Kidney Artery Ligation in Laparoscopic Donor Nephrectomy? *Journal of laparoendoscopic & advanced surgical techniques Part A* 2017;27:715-6.
43. Casale P, Pomara G, Simone M, Casarosa C, Fontana L, Francesca F. Hem-o-lok clips to control both the artery and the vein during laparoscopic nephrectomy: personal experience and review of the literature. *Journal of endourology / Endourological Society* 2007;21:915-8.
44. Baldwin DD, Desai PJ, Baron PW, et al. Control of the renal artery and vein with the nonabsorbable polymer ligating clip in hand-assisted laparoscopic donor nephrectomy. *Transplantation* 2005;80:310-3.
45. Ponsky L, Cherullo E, Moinzadeh A, et al. The Hem-o-lok clip is safe for laparoscopic nephrectomy: a multi-institutional review. *Urology* 2008;71:593-6.
46. Vastag B. Living-donor transplants reexamined: experts cite growing concerns about safety of donors. *JAMA : the journal of the American Medical Association* 2003;290:181-2.
47. Horie H, Endo N, Sata N, Yasuda Y, Nagai H. [Postoperative venous thrombosis in general surgery patients and perioperative prophylaxis]. *Nihon Geka Gakkai zasshi* 2005;106:232-6.
48. Toohar R, Boulton M, Maddern GJ, Rao MM. Final report from the ASERNIP-S audit of laparoscopic live-donor nephrectomy. *ANZ journal of surgery* 2004;74:961-3.
49. Metcalfe PD, Hickey L, Lawen JG. Bladder perforation during laparoscopic donor nephrectomy. *The Canadian*

journal of urology 2004;11:2456-8.

50. Simon SD, Castle EP, Ferrigni RG, et al. Complications of laparoscopic nephrectomy: the Mayo clinic experience. *The Journal of urology* 2004;171:1447-50.
51. Mohamed HK, Lin A, Savage SJ, Rajagopalan PR, Baliga PK, Chavin KD. Parenchymal transection of the kidney inflicted by endocatch bag entrapment during a laparoscopic donor nephrectomy. *American journal of transplantation : official journal of the American Society of Transplantation and the American Society of Transplant Surgeons* 2006;6:232-5.
52. Wang K, Liu DF, Wang L, et al. Inguinal incision as a successful route to extract the kidney during laparoscopic retroperitoneal live-donor nephrectomy. *Experimental and clinical transplantation : official journal of the Middle East Society for Organ Transplantation* 2013;11:396-9.
53. Chin EH, Hazzan D, Herron DM, et al. Laparoscopic donor nephrectomy: intraoperative safety, immediate morbidity, and delayed complications with 500 cases. *Surgical endoscopy* 2007;21:521-6.
54. Chin EH, Hazzan D, Edye M, et al. The first decade of a laparoscopic donor nephrectomy program: effect of surgeon and institution experience with 512 cases from 1996 to 2006. *Journal of the American College of Surgeons* 2009;209:106-13.
55. Cabral JF, Braga I, Fraga A, Castro-Henriques A, Principe P, Silva-Ramos M. From Open to Laparoscopic Living-donor Nephrectomy: Changing the Paradigm in a High-volume Transplant Center. *Transplantation proceedings* 2015;47:903-5.
56. Jacobs SC, Cho E, Foster C, Liao P, Bartlett ST. Laparoscopic donor nephrectomy: the University of Maryland 6-year experience. *The Journal of urology* 2004;171:47-51.
57. Serrano OK, Kirchner V, Bangdiwala A, et al. Evolution of Living Donor Nephrectomy at a Single Center: Long-term Outcomes With 4 Different Techniques in Greater Than 4000 Donors Over 50 Years. *Transplantation* 2016;100:1299-305.
58. Ng ZQ, He B. A Proposed Classification System and Therapeutic Strategy for Chyle Leak After Laparoscopic Living-Donor Nephrectomy: A Single-Center Experience and Review of the Literature. *Experimental and clinical transplantation : official journal of the Middle East Society for Organ Transplantation* 2018;16:143-9.
59. Aerts J, Matas A, Sutherland D, Kandaswamy R. Chylous ascites requiring surgical intervention after donor nephrectomy: case series and single center experience. *American journal of transplantation : official journal of the American Society of Transplantation and the American Society of Transplant Surgeons* 2010;10:124-8.
60. Capocasale E, Iaria M, Vistoli F, et al. Incidence, diagnosis, and treatment of chylous leakage after laparoscopic live donor nephrectomy. *Transplantation* 2012;93:82-6.