

# Diagnosis and Management of Tuberculosis

## Chapter 5

### CNS Tuberculosis: An Overview

*Aadil S Chagla<sup>1\*</sup>; Khalil I Mathai<sup>2</sup>; Amey S Parab<sup>3</sup>*

*<sup>1</sup>Department of neurosurgery, Seth G S Medical College and King Edward Memorial Hospital and Senior Consultant Neurosurgeon, Breach Candy Hospital and Research Centre, Mumbai Maharashtra – India.*

*<sup>2</sup>Senior Consultant Neurosurgeon, Kerala Institute of Medical Sciences, Trivandrum Kerala – India.*

*<sup>3</sup>Assistant Professor Neurosurgery, Goa Medical College and Hospital, Bambolim, Goa - India.*

*\*Correspondence to: Aadil S Chagla, Department of neurosurgery, Seth G S Medical College and King Edward Memorial Hospital and Senior Consultant Neurosurgeon, Breach Candy Hospital and Research Centre, Mumbai Maharashtra – India.*

*Email: [aadilchagla@kem.edu](mailto:aadilchagla@kem.edu)*

#### 1. Introduction

Tuberculosis (TB) is foremost amongst ‘the captains of death’ of men. It has afflicted humanity from time immemorial. Predictions of its eradication a few decades ago seemed premature and misjudged as the resurgence of TB on the back of the AIDS pandemic derailed benefit paradigms and the emergence of a spectrum of drug resistance brought in new challenges. WHO declared TB a global emergency in April 1995. The historical names for the disease reflect the wasting that is associated with uncontrolled disease. The English called it “consumption” and the Vedas “Yakshma”. The word Tuberculosis is derived from the Latin term ‘Tubercula’ which means small lump.

The day on which Robert Koch declared his discovery of the Tubercle bacillus, on the 24th of March 1882, is commemorated as the ‘World Tuberculosis Day. As the discovery of X-rays by William Conrad Rontgen offered an accessible window into the pathological ravages of pulmonary disease, the discovery of Streptomycin, PAS and INH in the 1940’s sparked the era of effective antitubercular therapy. Today, 3.7% of new cases of Tuberculosis are caused by Multidrug resistant organisms. Amongst patients previously treated for TB, the incidence is 20%. Finally 9% of recurrent TB is XDR (extremely drug resistant).

Tuberculosis (TB) is a global disease, 9.2 million new TB cases occur globally every

year. Of these patients around 13% are HIV positive. Around 1.7 million deaths each year are attributable to Tuberculosis. WHO aims to reduce deaths due to Tuberculosis by 95% by the year 2035. HIV 1 infection is the strongest risk factor for tuberculosis and in India TB is the most common opportunistic infection in HIV positive patients. CD4 counts, the mark of immune competence in HIV, is of strong predictive value in prognosis. The commonest cause of HIV associated deaths in Africa is Tuberculosis. At a global level one third of all TB mortality is associated has an HIV- TB association.

Around 20% of tuberculosis patients have extrapulmonary tuberculosis. Tuberculosis can affect a variety of organ systems including the CNS. Neuromeningeal tuberculosis is rarely seen in immunocompetent individuals in the west. In developing countries TB meningitis is the most common and devastating form of CNS tuberculosis resulting in Vasculitis, Infarctions and Hydrocephalus with consequent Cognitive, Intellectual and Endocrine sequelae.

The clinical manifestations of TB reflect the myriad interplays between Mycobacterium Tuberculosis (MTB) and the human host. DNA evidence suggests that man and the tubercle bacillus have coevolved from the Neolithic ages [1]. With prosperity and progress the incidence of this once global scourge now expresses profound geographic variations. Today the disease predominantly afflicts denizens of the third world [2]. India and China together account for 40% of the world wide incidence. The incidence of HIV with TB is highest in Africa. Around two million people die of tuberculosis yearly across the world. The immunocompromised population, whether afflicted by AIDS or with immune deficiency induced by cancer therapy or post transplant regimes remains vulnerable to Tuberculosis. An additional confounding factor has been the emergence of drug resistant variants which pose additional and sometimes unsurmountable impediments to effective treatment. Indeed the professed WHO target of eradicating tuberculosis by 2050 has been stymied by evolution of multidrug resistant (MDR), extensively drug resistant (XDR) and functionally untreatable strains of MTB.

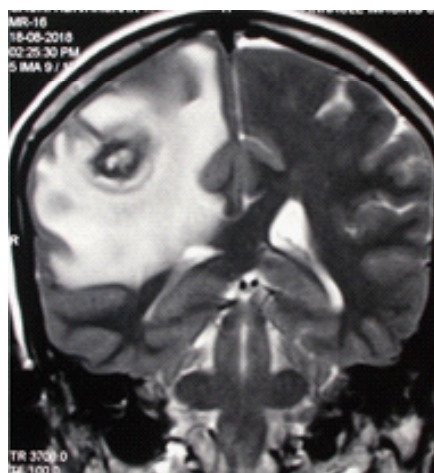
Tuberculosis is almost inevitably transmitted through the respiratory tract. The initial inoculum is often eliminated or kept in check by host defence mechanisms. Both host and pathogen factor variables influence the efficacy and outcome of this encounter. Vitamin D is one amongst the nutritional supplements which contributes to an effective immune restraint [3]. In about 15% of patients the initial infection progresses to clinical disease syndromes. In around 12% of cases the organism escapes the initial immune confined to reactivate and result in clinical disease [4]. Genetic susceptibility to TB is due to multiple genomic traits [5].

Hematogenous dissemination of the tubercle bacillus from the primary focus culminates in the occurrence of extrapulmonary tuberculosis. Some of the more sinister syndromes of the disease are consequent to CNS invasion. The blood brain barrier (BBB), constituted by tight endothelial junctions supported and nourished by supporting astrocytic foot processes

prevents passive intracranial egress of infections and toxins [6]. Endothelial cells may be the initial residence of MTB in the CNS. Tubercle bacilli cross the BBB via infected monocytes/neutrophils [7]. The initial focus in the brain is called the ‘Rich’ focus after Arnold Rich, who along with Howard McCordick first demonstrated cascading foci in the meninges and brain parenchyma of patients with TB meningitis. MTB enter the CSF consequent to rupture of the ‘Rich’ focus. A T-cell response occurs. Cytokines like TNF alpha and Interferon gamma are activated. Inflammation causes obstruction of CSF pathways resulting in hydrocephalus and vasculitis which leads on to infarctions. Suppressing the inflammatory response therefore is integral to therapeutic regimens in CNS Tuberculosis [8].

The brain has limited regenerative capacity. This necessitates a certain degree of immunological privilege with a restricted supply of dendritic cells and limited expression of MHC class 2 molecules [9]. The tailored immune capability has been used to explain many unique features of CNS tuberculosis. Selective privilege is responsible for the delayed onset of inflammatory meningitis in disseminated tuberculosis. The phenomenon of delayed enlargement of Tuberculomas, the so called ‘paradoxical’ growth which occurs well after the initiation of antitubercular treatment is also explained by the unique immunological milieu of the brain. Both host and pathogen factors may play a part in the unique clinicopathological manifestations of an index case of CNS tuberculosis [10].

Tuberculomas which are tubercular granulomas occur in the cerebral parenchyma because of haematological dissemination. Tuberculomas in the subarachnoid space are more often the consequence of tubercular meningitis. Around 39% of patients with TB meningitis develop tuberculomas which may appear paradoxically after initiation of antitubercular treatment. Factors in tubercular meningitis that predispose to tuberculoma formation include high levels of CSF protein (>3g) and the presence of meningeal enhancement on contrast imaging [11, 12].



## 2. Manifestations of CNS Tuberculosis

CNS Tuberculosis occurs in 1% of Tuberculosis patients but has the most dire morbidity and mortality.

The wide spectrum of CNS TB includes the following:

### **2.1. Brain**

1. TB meningitis
2. Tubercular encephalopathy
3. Vasculopathy- End arteritis
4. Hydrocephalus
5. Tuberculoma
6. Brain Abscess

### **2.2. Spinal Cord**

1. Intramedullary tuberculoma
2. Spinal meningitis
3. Secondary injury to spinal cord in Potts spine

### **3. Clinical Syndromes associated with CNS tuberculosis**

1. The meningitis syndrome
2. Hydrocephalus syndrome
3. Intracranial space occupying lesion syndrome including
  - a. Seizure phenomena
  - b. Focal Neurological deficits which can be due to infarcts or mass lesions
  - c. Focal neurological defects
4. The vasculitis syndrome resulting in infarcts.
5. Spinal Cord Syndromes
  - a. Intramedullary syndromes
  - b. Potts spine manifestations
  - c. Radicular syndromes associated with arachnoiditis

6. Visual impairment which can occur
  - a. Secondary to increased icp
  - b. Due to basal arachnoiditis
  - c. Associated with optic nerve granulomas
  - d. Adverse effect of ATT especially Ethambutol

#### 4. Tubercular Meningitis

TB meningitis is the commonest form of CNS Tuberculosis. It accounts for 5% of extrapulmonary tuberculosis. TB meningitis affects children often and the age group less than one year is most vulnerable. In India, the estimated mortality attributed to CNS TB is 1.5/100,000.

##### 4.1. Pathogenesis

Human infection is transmitted by the respiratory route. MTB is essentially and dominantly a lung residing pathogen. In the lungs the bacillus is phagocytosed by alveolar macrophages. Intracellular signalling pathways result in the formation of a phagocytic cup. In successful antibacterial defence the phagosome fuses with lysosomes to neutralise the invasive agent.

Macrophagic strategies to lyse bacteria include:

1. The induction of nitric oxide and reactive oxygen species. These kill bacteria by oxidising membrane lipids and fragmenting DNA.
2. Preventing intracellular phagocytosed bacteria from having access to nutrients like amino acids, fatty acids and iron.
3. Induction of antimicrobial peptides and cytokines.
4. Macrophages use autophagy for intrinsic cleansing of senescent organelles as well as of phagocytosed bacteria [12].

Approximately one third of the world population harbours a dormant tubercular infection. Around 10% of these may progress to active disease. This rate may be higher in children, at around 50% reflecting a higher vulnerability to disease progression. Tubercle bacilli which escape autophagic destruction disseminate by the hematogenous route. They seed end arterioles of the Brain or Meninges and mature into tubercular micro-abscesses. These micro-abscesses may burst and release contents into the subarachnoid space culminating in TB meningitis. In

the brain parenchyma they may evolve into a brain abscess or into a tuberculoma depending upon the immunologic response or the host and on the virulence of the pathogen (MTB). In the subarachnoid space TBM produces adhesions and exudates. The adhesions may result in radiculopathy syndromes or in blockage of CSF pathways and consequent hydrocephalus. The basal meninges and cisterns are commonly affected. Cranial nerve involvement often occurs especially affecting the 6th and 7th nerves. Hydrocephalus is relatively common and is attributable to basal/ cisternal adhesion as well as to the high protein content of the CSF. Obstructive hydrocephalus is less common and occurs due to tuberculomas blocking CSF pathways or due to adhesive ependymitis. Exudates may coalesce into cisternal tuberculomas in a process which may be augmented by antitubercular therapy. This enlargement or appearance of fresh mass lesions is described as a paradoxical reaction. Paradoxically enlarging tuberculomas may merit surgical excision if they are in critical locations or producing clinical syndromes by mass effect. In this scenario ATT is continued and corticosteroids are added to the regime. A meta-analysis of 7 randomised controlled trials concluded that corticosteroids are beneficial in HIV-positive patients with TB meningitis. There is no clear consensus on the administration of steroids to TBM patients who are HIV positive. [13]

#### **4.2. Clinical features**

The clinical features of Tb meningitis in adults includes headache, vomits and altered sensorium with or without fever. Children with TBM have headache less frequently, but have seizures along with nausea and vomits. HIV positive individuals with tuberculosis are more likely to develop TB meningitis, with an incidence of 10% versus the 2% incidence in non HIV individuals. CD 4 counts of <100 are associated with a higher incidence of CNS TB. The risk of CNS Tuberculosis however can flare up even in the early phase of HIV when the CD 4 counts are still normal as well as in the phase after initiation of ART when the counts are recovering. HIV patients with TBM have a distinct syndrome wherein the classical triad of fever, headache and meningeal signs is replaced by early alteration in sensorium along with other manifestations of HIV like lymph adenopathy and of other extrapulmonary tuberculosis manifestations (13). Other immune compromised states influencing the course of Tuberculosis include malnutrition, extremes of age, alcohol dependence, diabetes mellitus, therapeutic immunosuppression and Vit D deficiency.

The most serious complications of TB meningitis include hydrocephalus, stroke and tuberculoma formation. The incidence of TB meningitis and stroke is higher in children than in adults. Children may develop hemiplegia as a consequence of TB meningitis induced vasculitis and stroke [14].

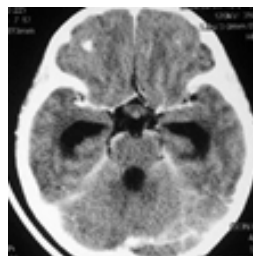
### 4.3. CSF picture in TB meningitis

1. Lymphocyte predominance (60-400/mm<sup>3</sup>)
2. Increased protein level (0.8 to 4 gms/L)
3. Decreased glucose level (<50% of serum levels but not as low as in pyogenic meningitis)
4. Demonstration of MTB in CSF smear or culture
5. Antibody titres
6. Interferon gamma release assays include TB Gold and T-Spot TB and are based on the detection of interferon gamma in response to antigens in MTB. Serum interferon gamma levels are not affected by BCG. 17-45% of patients with TB meningitis have a positive response to Purified Protein Derivative.

### 4.4. Radiology in TB Meningitis

40-60% of patients with TB meningitis have abnormal chest X-Rays. Every patient with TB meningitis should undergo a contrast enhanced imaging within 48 hrs of initiation of ATT. CT and MR images may show evidence of cerebral ischemia or infarction, meningeal enhancement and of hydrocephalus. Characteristically we see: [15]

1. Enhancing exudate in basal cisterns
2. Ventriculomegaly
3. Basal Ganglia infarcts
4. Gyral enhancement pattern



**Figure 1:** CECT showing enhancing basal exudates

### 4.5. Outcome

In about 50% of patients TB meningitis leads on to death or disability. Patients may develop a paradoxical worsening of their clinical state after initiation of ATT. It is recommended that steroids be used at initiation of ATT even in HIV positive patients. This ‘Paradoxical

reaction' is related to the hosts immune response. Steroids are commonly used. Other immunomodulatory drugs like Thalidomide also have a role in alleviation of this condition [16]. Biomarkers may be used as a marker of neurological injury in TBM. The markers which have been used include S 100 B, Neuron Specific Enolase and Glial Fibrillary Acidic Protein.

#### **4.6. Grading severity of TB meningitis**

TB meningitis is generally graded by the severity of neurological involvement. At the lower end of severity we have patients who are alert and oriented and without a neurological deficit. The next group is patients with a GCS ranging from 11 to 14 who may or may not have focal neurological deficits. The most serious patients have a GCS of 10 or less. The mortality rate in TB meningitis in patients who have an altered sensorium varies from 10.5 to 57.1% in various studies. In those who have a normal sensorium, the mortality figures quoted vary from 0 to 12.5%.

One of the validated grading systems of clinical severity in TB meningitis is the Vellore grading system described by Palur.

#### **4.7. The Vellore/Palur Grading system**

Grade 1- Patients with no deficits and a normal sensorium.

Grade 2- Patients with a normal sensorium who have focal neurological deficits.

Grade 3- Patients with an altered sensorium with or without focal deficits.

Grade 4- Moribund or deeply comatose patients.

Cranial nerve palsies occur in 20-30% of patients. The most commonly affected nerve is the 6th cranial nerve.

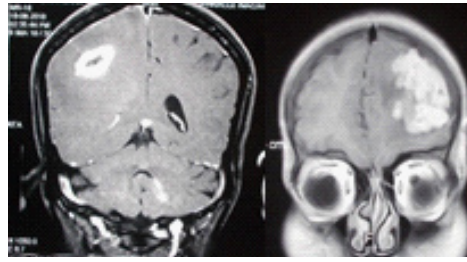
Visual loss in TB meningitis may be attributable to optochiasmatic arachnoiditis, by compression of the optic chiasm by third ventricular enlargement or by the occurrence and enlargement of tubercles in the optic nerves. Fundus examination may reveal papilloedema, single or multiple choroid tubercles may be present.

### **5. Intracisternal Tuberculomas**

These form from Tubercular exudates in the cisterns and often occur paradoxically after initiation of treatment for TB meningitis.



## 6. Brain Tuberculomas



**Figure 2:** MRI scans showing supratentorial tuberculomas

CNS tuberculosis develops in approximately 1% of all patients with active *Mycobacterium Tuberculosis* infection.

### 6.1. Pathogenesis

Tuberculomas and TB meningitis both develop consequent to hematogenous dissemination of MTB in patients with Pulmonary Tuberculosis. Rarely there may be direct contamination from the paranasal sinuses. Hematogenous seeding results in the formation of a sub-pial or subependymal focus in the brain. These foci may rupture resulting in subarachnoid dissemination and TB meningitis. Tuberculomas generally form when the tubercular focus does not rupture, but is contained by the body's immune system. These tubercles however grow to produce mass lesions. Tuberculomas can also occur in patients with Tubercular meningitis. While intraparenchymal tuberculomas are the result of direct hematogenous seeding and establishment of a microfocus at a blocked arteriole level, basal and cisternal tuberculomas are secondary to TB meningitis. The incidence of Tuberculomas in TB meningitis is around 10%. Tuberculomas are multiple in about a third of patients [14]. Adult patients usually suffer supratentorial lesions while children have lesions in the posterior fossa.

In developed countries Tuberculomas are rare and constitute only 0.15% of ICSOL's. In the developing nations however 20 to 30% of ICSOL's may be tuberculomas. Tuberculomas can occur in any part of the brain. Brain tuberculomas which have a propensity to occur in the posterior fossa especially in children [14] are rarely a cause of obstructive hydrocephalus. In the supratentorial compartment there is a predilection for intra-axial tuberculomas to occur in the Frontal and Parietal lobes. Tuberculomas may present as intrinsic brain stem masses [15]. Isolated brain stem tuberculomas constitute only 5% of intracranial tuberculomas. Tubercular lesions may also occur in the subarachnoid, subdural or epidural spaces.

The spinal cord is another location where tuberculomas can occur [16]. They manifest like any other intramedullary spinal cord mass. Intramedullary tuberculomas constitute 2 in 1000 cases of CNS tuberculosis. The commonest site is the thoracic cord.

Sellar region tuberculomas comprise some of the rarer differential diagnoses of pituitary region tumours.

Intra-cisternal tuberculomas develop in patients with TB meningitis who have exudates in the basal cisterns. Surgical intervention may be required when there paradoxical growth after initiation of ATT.

## **6.2. Pathology**

Pathologically a tuberculoma is a conglomerate mass of tissue made up of small tubercles. Tubercles are usually conglomerate. There is a central core of epitheloid cells (altered monocytes) surrounded by lymphocytes.

## **6.3. Radiology**

### **6.1.1. CT scan features**

Single or multiple low or high-density round or lobulated masses with irregular walls. Homogenous enhancement on contrast. Variable perilesional edema (depending upon age of lesion). ‘Target Sign’ (17)- A spot of calcification surrounded by a ring of enhancement.

### **6.1.2. MRI features**

Intracisternal tuberculomas appear as multiple coalescing contrast enhancing lesions. Intraparenchymal tuberculomas are usually hypo or hyperintense. They may have central hypodense areas corresponding to caseous necrosis and may show ring enhancement. MR spectroscopy usually shows a lactate peak.

### **6.1.3. Clinical features**

The clinical presentation of tuberculomas is with headache, seizures, focal neurological deficits or papilledema. The neurological deficits may be severe, with altered mental status and hemiplegia. Hydrocephalus may be present.

## **7. Hydrocephalus**

Hydrocephalus is one of the commonest complications of TB meningitis. Hydrocephalus usually occurs in TBM after the initiation of ATT. The incidence of Hydrocephalus in children with TB meningitis is almost 90%. 12% of adults with TB meningitis develop hydrocephalus. The onset of symptoms is typically 4 to 6 weeks after the initiation of treatment. These patients benefit from early CSF diversion. Complications are however frequent.

### **7.1. Pathogenesis**

Hydrocephalus in TBM may be purely obstructive, purely communicating or combined. The aetiology of hydrocephalus in TB meningitis is typically multifactorial. Thick gelatinous exudates develop, involving the cisternal spaces and the basal subarachnoid compartments.

This results in a communicating hydrocephalus. Blockage of the exit foramina of the fourth ventricle by exudates or Leptomeningeal scarring produces a panventricular obstructive hydrocephalus. Occlusion of either Foramen of Monro may result in a monoventricular dilatation. The aqueduct of Sylvius may be occluded by tuberculomas or by adhesive ependymitis to produce triventricular obstructive hydrocephalus. Strangulation of the brainstem by basal exudates may also result in aqueductal blockage. Another possible contributory factor for hydrocephalus is the increase in CSF production consequent to inflammation of the ependyma and of the choroid plexus.

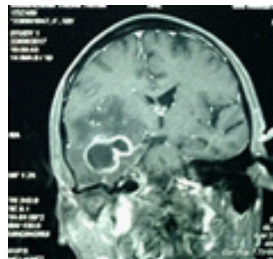
## 7.2. CT findings

These include periventricular lucency, basal exudates, infarcts and a rising Evan's ratio.

## 8. Calvarial Tuberculosis

Usually seen in children and may form collar stud abscesses. These respond to ATT.

## 9. Tubercular Brain Abscess



**Figure 3:** MRI scan showing right temporal TB abscess

Tubercular abscesses are often larger than tuberculomas and have a more acute presentation. Abscesses are more common in HIV afflicted individuals. While around 6% of HIV -ve patients with CNS tuberculosis have brain abscesses, nearly 20% of HIV positive patients suffering from CNS TB have brain abscesses.

### Pathogenesis:

These abscesses are characterised by a thick wall with an encapsulated collection of pus. The abscess wall is generally thicker than in the case of pyogenic abscess. The pus can be demonstrated to contain viable tubercle bacilli. Histopathology reveals the absence of granuloma formation. The aetiopathological difference between Tuberculomas and Tubercular Brain abscess is the host's immune response. HIV induced suppression of cell mediated immunity increases the chance of formation of a tubercular abscess.

## 10. Optochiasmatic Tuberculoma

This is a complication of TB meningitis [18].

## 11. Sellar Tuberculomas

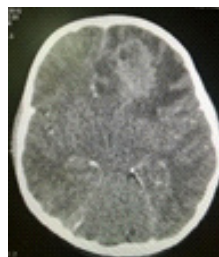Tuberculomas or tubercular abscesses may occur in the sellar region. The commoner causes of lesions in the sella include Pituitary Adenomas, Craniopharyngiomas and Rathkes cleft cysts. Colloid cysts, metastases and arachnoid cysts may also rarely occur.

## 12. Stroke in TB meningitis

Stroke in tuberculosis may occur due to vasculitis, vasospasm, endovascular thrombosis or by vascular entrapment in basal exudates. Early infarcts are believed to be due to spasm while later deficits represent vessel entrapment or thrombosis. Hemorrhagic infarctions are relatively rare but may occur. 15-57% of patients with TB meningitis develop infarctions of which a significant majority are subclinical.

### 12.1. Pathogenesis

The commonest vessels involved are the Medial Striate, the Thalamotuberal and the Thalamostriate. The so called tubercular zone for infarcts includes the Caudate, the anterior Thalamus and the anterior limb and genu of the internal capsule. Major vessels may sometimes be involved to produce cortical stroke. The proximal MCA, ACA, PCA, Supraclinoidal ICA and Basilar may be involved in tubercular arteritis. Vessels may be embedded in exudates or stretched by hydrocephalus. Activation of cytokines including TNF alpha, VEGF and MMP's has been incriminated. Steroids (dexamethasone) and aspirin have not been conclusively shown to be of benefit in the alleviation of arteritis. However some beneficial effects have been described [18, 19]. Tubercular arachnoiditis and pachymeningitis is rare in children.



**Figure 4:** CECT showing left frontal tuberculoma with surrounding edema

In a setting of immune compromise the differential diagnosis of CNS mass lesions include other infections like Toxoplasmosis and malignancies like Lymphoma. The CSF picture also gets confounded. The HIV viral load and a declining CD4 T lymphocyte count correspond with a flare up or new onset CNS TB. Highly active antiretroviral therapy on the other hand decreases the risk of Tuberculosis exacerbations [20]. Patients who have undergone solid organ transplantation with the necessary post-transplant immunosuppression are also at a higher

risk of developing TB meningitis.

Drug interactions between Antitubercular drugs and HART (Highly active antiretroviral therapy) have to be kept in mind and the timing of initiation of HART and ATT need to be tailored to individual patients. The occurrence of IRIS (immune reconstitution inflammatory syndrome) will merit special treatment.

Therapeutic immunosuppression in solid organ transplant recipients and the use of immunomodulatory biologicals in rheumatoid arthritis may result in potentially catastrophic exacerbation of CNS TB.

## **14. Other sequelae**

Although the disease is curable and complete eradication is possible with ATT the residual scarring of the CNS can produce various sequelae. Ventricular and ependymal involvement may cause obstructive hydrocephalus. Cortical scarring may lead to scar epilepsy. Rarely deep seated scarring in the thalamic region can lead to abnormal involuntary movements like dystonia.

## **15. Management of CNS Tuberculosis**

### **15.1. Pharmacotherapy**

Medical management of Tuberculomas include antiseizure medications, dexamethasone, other anti-oedema measures as appropriate and antitubercular drugs. INH, Rifampicin and Pyrazinamide have good CNS penetration and are bactericidal. Conventionally, SHRZ is administered. The total duration of therapy is 18 months. Short term intensive therapy regimes over six months have also been reported as successful. However intensive short course regimes have been described.

**Drug resistance:** The problem of emerging drug resistance, with Drug Resistant (DR or Resistant to one first line drug), Multidrug resistant (MDR or Resistant to INH and Rifampicin), Extensively drug resistant (XDR), Extremely drug resistant (XXDR), super XDR and Totally drug resistant (TDR) variants poses fresh and sinister challenges as does the entity of patient intolerance to ATT. Patient intolerance to first line ATT is often related to deranged liver functions. One of the established dictums is that a single new antitubercular drug should never be added to a failing regime of ATT. Drug resistance (MDR and XDR) may be considered in those with a prior history of tuberculosis, in those who have had exposure to drug resistant tuberculosis and in those with poor clinical response to ATT.

**Paradoxical reaction:** Patients with TB meningitis may manifest enlargement of existing lesions or the appearance of new ones while on ATT. This phenomenon, known as the 'Paradoxical Reaction' needs to be differentiated from treatment failure. Paradoxical reac-

tions occur in about a third of TB meningitis patients on ATT. Female gender, the existence of concomitant HIV and a relatively rapid onset of disease are all predictive of a higher risk of paradoxical progression. Paradoxical enlargement of tuberculomas responds to the addition of Dexamethasone to the ongoing antitubercular drug regime [21]. Dexamethasone decreases mortality but does not affect neurological outcomes (21). Thalidomide may be considered in children with Tubercular abscesses and TB related optochiasmatic arachnoiditis.

## 15.2. Host Directed Therapies

Much of the damage in CNS tuberculosis is mediated by host responses. The relative immunologic impunity enjoyed by the bacillus is also a potential target for modulation. Tailored host genotype specific therapies have been designed to harness host responses effectively to control the bacillus and will be part of therapeutic strategies of the future. Drugs directed at the host may disrupt macrophage host signalling pathways, deprive the pathogen of nutrients, promote autophagy or activate antimicrobial killing mechanisms.

Drugs which have been proposed to modulate host responses include Vit D, Imantinib, Cyclic amp inhibitors like Cilostazol, Pentoxifyline and Sildenafil, eicosanoids like Aspirin, Oxyphenbutazole and PGE2, Statins, Metformin and autophagy inducing drugs like Rapamycin. Drugs which augment host responses and those that mitigate the response of the host are both used. Amongst the advantages of host directed therapy is the action against resistant strain, synergy with antimicrobials and activity against non replicating MTB. Overall, the chances of disease recurrence are decreased.

Host directed therapies are important in the context of evolution of resistant strains.

There is some controversy on whether tubercle granuloma formation protects the host or the organism. The granulomas have macrophages and T and B lymphocytes with fibrous encapsulation. They may act as a mechanical and functional barrier to bacillary dissemination. On the other hand they may allow indolent bacilli to survive for prolonged periods. [20,21,22,23]

## 16. Role of Surgery

Tuberculosis therapy although mostly medical does require surgical intervention in some cases.

The indications for surgery are:

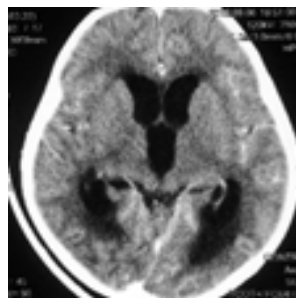
1. to control raised ICP rapidly
2. to relieve hydrocephalus

3. to resect mass lesions
4. to provide tissue diagnosis
5. In lesions recalcitrant to ATT and
6. in the spine to decompress neural elements and stabilise the spine.

### 16.1. Hydrocephalus

Hydrocephalus is the commonest cause of increased ICP in CNS tuberculosis. Increased intracranial tension in CNS Tuberculosis may also occur with mass producing tuberculomas which act as SOLs, with brain oedema which is potentially multifactorial. Cerebral infarctions which swell and venous thrombosis are other rarer causes.

Medical management of hydrocephalus in TBM with Dexamethasone, acetazolamide and frusemide along with repeated ventricular taps can help in alleviation and avoidance of surgery in 70% of cases of TBM



**Figure 5:** CT scan showing post TB meningitis hydrocephalus

### 16.2. CSF diversion procedures

Options for CSF diversion in hydrocephalus due to TBM include ventriculoperitoneal shunts, Thecoperitoneal shunts and Endoscopic Third Ventriculostomy.

VP shunts in TBM have a higher than expected incidence of complications [24,25,26,27]. Repeated lumbar punctures and External ventricular drain placement have been suggested as options to try and avoid a shunt [24,25,26,27]. In patients with poor grades, a trial of external ventricular drainage and assessment of benefit will help in the decision to place a permanent shunt.

### 16.3. Ventriculoperitoneal Shunts

Shunts in TB meningitis are prone to blockage by the high protein content and because of exudates encrusting the catheter tip. The fear of dissemination of Tuberculosis as a consequence of VP shunting is probably unfounded [28].

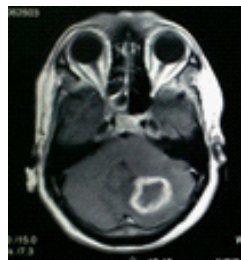#### 16.4. Endoscopic Third Ventriculostomy (ETV)

ETV is typically performed through a single burr hole in line with the Foramen of Monro and the Interpeduncular cistern. Fenestration is between the mamillary bodies and the infundibular recess at a point anterior to the basilar artery where the floor is thin and transparent. The stoma is usually enlarged with a Fogarty catheter. A Lillequist membrane, if present, should also be fenestrated. Endoscopic Third Ventriculostomy has been proposed as an option [28]. However, the Third Ventricular floor is often thick and opaque especially in the acute phase of TBM posing technical challenges in safe fenestration of the ventricular floor. An opaque ventricular floor markedly increases the risk of catastrophic vascular injury. The potential for vascular injury to the Basilar artery or its branches is only partially addressed by the use of intraoperative doppler or by neuro-navigation. The ideal patients for ETV are those in the chronic phase of TB meningitis who are well nourished and with a thin and transparent third ventricular floor. Malnourished patients in the acute phase, with cisternal exudates and a thick opaque ventricular floor may be considered for ventriculoperitoneal shunting. It is often difficult to evaluate stoma patency after ventricular floor fenestration. Resolution of periventricular lucency, widening of subarachnoid spaces and a decrease in the ventricular size are all features of a patent diversion. However, a delayed absorption of CSF in these patients due to arachnoidal thickening may result in a relatively slow or tardy response. Demonstration of a flow void across the ventricular floor in MR ventriculography is conclusive evidence [28]. Ventriculography however is invasive. CISS MRI is also sensitive to CSF flow. Cine phase contrast MRI is the most commonly used modality for demonstrating fenestration patency [24,25,26,27,28,29]. In most of our patients we therefore prefer to use a the classical ventriculo-peritoneal shunts.

#### 16.5. Theco-peritoneal shunt

Theco-peritoneal shunting is an option in treating communicating variety of hydrocephalus. A combination of ETV with a theco-peritoneal shunt is sometimes used in patients with obstructive hydrocephalus in TBM. In infants, choroid plexus coagulation may be used as an additional and complementary surgical modality [24,25,26,27].

#### 16.6. Management of Tuberculomas and Tuberculous abscesses



**Figure 6:** MRI showing tuberculoma of the left cerebellar hemisphere



Tuberculomas need surgery when they are large and cause mass effect on the underlying normal brain. The lesion with the usually extensive perilesional edema can cause significant midline shift leading to altered sensorium and impending herniation. Lesions in the cerebellar hemispheres should have a lower threshold for surgery if they cause mass effect on the fourth ventricle and are significant in size. Tubercular abscesses are managed by aspiration and excision when feasible along with antitubercular treatment. Complete excision is not a goal and indeed is impossible in eloquent areas. However partial or sub-total resection to relieve mass effect and adequate ATT usually give good results.

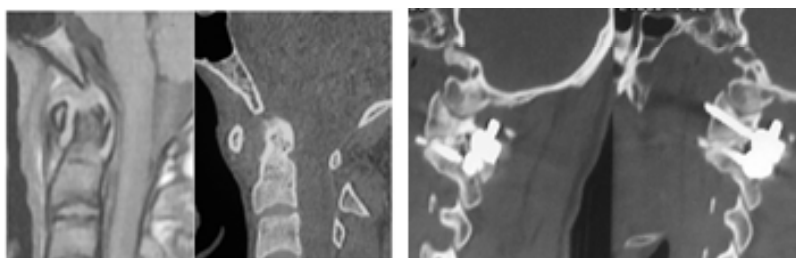
### 16.7. Management of Optochiasmatic arachnoiditis

This usually occurs in patients who have tubercular exudates in the basal cisterns. These patients may have paradoxical vision loss after initiation of antitubercular therapy regimes. Some of these patients benefit from surgical intervention [30,31,32].

### 16.8. Spinal Tuberculosis

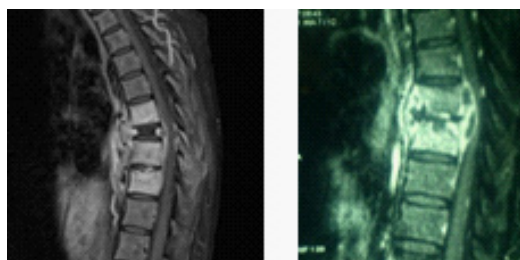Spinal Tuberculosis includes both the spectrum of spino-osseous Tuberculosis which produces clinical syndromes by spinal collapse and spinal cord or cauda equina compression and tuberculosis which affects the neural structures directly.

The clinical syndromes in spino-osseous TB are outside the purview of CNS tuberculosis.



**Figure 7:** Atlanto axial TB and surgical treatment with C1 C2 fusion

The neurological syndromes consequent to vertebral involvement however are often devastating often producing mixed syndromes of myelo radicular compromise. Vertebral tuberculosis which affects the disc space and contiguous end plates initially often respond to rest and ATT. However structural instability with imminent collapse and consequent neurological devastation merits surgical stabilisation which has a high degree of success.



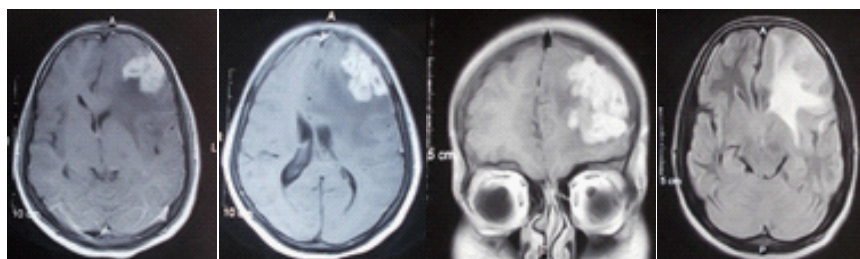
**Figure 8:** MRI showing TB of dorsal spine. Destruction of vertebra and kyphosis with para vertebral abscess

Spinal intradural tuberculomas including intramedullary and intradural extramedullary variants account for 2.5% of all CNS TB. Spinal intramedullary tuberculomas are usually solitary but may occasionally be multiple. Dorsal involvement is most common. However cervical lesions have been well described [33,34]. The commonest presentations are spastic or flaccid paraplegia along with bladder and bowel involvement. Differential diagnoses include astrocytomas, ependymomas and hemangioblastomas of the spinal cord. The MRI picture in spinal intramedullary tuberculomas varies depending on the age of the lesion. They appear hypo to isointense on T1 weighted images and hyperintense on T2 weighted images. The hyperintensity on T2 weighted sequences becomes duller in mature tuberculomas as the cellularity increases. Liquefaction of the core adds brightness on T2 sequences. A target sign [35] with sharp borders is highly suggestive. Post gadolinium there is ring like or nodular enhancement. Around a quarter of healed tuberculomas show evidence of calcification.

Spinal intramedullary tuberculomas are well circumscribed and amenable to surgical excision [33]. Antitubercular treatment along with steroids is given to all patients whether or not they are subject to surgery.

### Case discussion 1

This relates to a 10 year old girl with left frontal tuberculoma. The patient had progressively worsening headaches which progressed to deficits. She became hemiparetic on the right side and had features of raised ICP on examination as in presence of papilloedema. Her MRI of the brain showed a large conglomerate lesion in the left frontal region with edema and mass effect suggestive of TB. She underwent surgical excision of the lesion in view of progressively increased ICP and made excellent recovery with ATT.



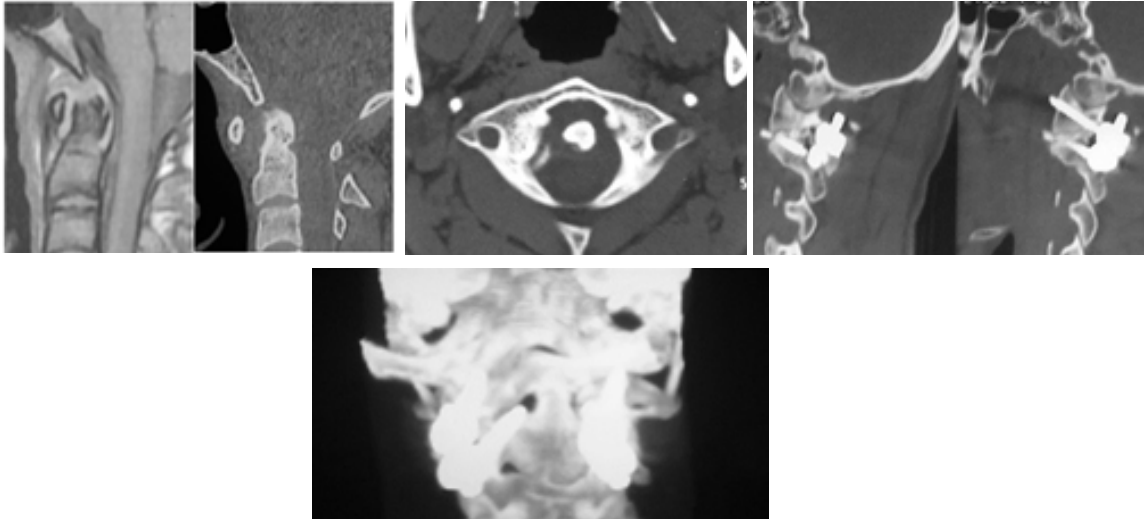
MRI scans showing the tuberculoma and adjoining extensive edema.



Post op image of the patient showing complete recovery with no neurological deficits (The Surgery was performed by the First Author)

## Case discussion 2

This is a case of a young gentle man with neck pain who became increasingly weak leading to quadriparesis. Imaging revealed an atlanto axial dislocation with increased ADI. MRI revealed contrast enhancement suggestive of granulation along the odontoid and the C1C2 joints. There was cord compression on account of the AAD and inflammatory mass. The patient was operated and C1C2 lateral mass fixation done with decompression. With ATT subsequently, the patient made good recovery.



Imaging showing the AAD with MRI evidence of TB granulation around the odontoid. Post op scans showing the lateral mass screws and 3d recon. (The Surgery was performed by the Firs Author)

## 17. Reference

1. Donoghue HD, Spigelman M, Greemblatt CL, Lev MaorG, Bar-Gal GK et al: Tuberculosis from prehistory to Robert Koch as revealed by ancient DNA. *Lancet Infect Dis*: 2004 Sep 4 (9): 584-92
2. Zumla A, George A, Sharma V, Herbert N, Baroness Masham. WHO's 2013 global report of tuberculosis: Successes, threats and opportunities. *Lancet*. 2013 Nov 30; 382 (9907): 1765-7
3. Martineau AR. Old Wine in new bottles: Vit D in the treatment and prevention of tuberculosis: *Proc Nutr Soc*. 2012 Feb;71 (1): 183-201s
4. Vynnycky E, Fine PE. The natural history of tuberculosis: the implications of age dependent risks of disease; the role of reinfection. *Epidemiol Infect*. 1997bOct; 119 (2): 183-201
5. Moller M, die Wit E, Hoal EG. Past, present and future directions in human genetic susceptibility to tuberculosis. *FEMS Immunol Med Microbio*. 2010 Feb: 58 (1): 3-26
6. Donald PR, Schaaf HS, Schoeman JF. Tubercular meningitis and military tuberculosis: the Rich focus revisited. *J Infect*. 2005 Apr; 50 (3): 193-5
7. Rubin LL, Staddon JM. The cell biology of the blood brain barrier. *Annu Rev Neurosci*. 1999: 22;11-28
8. Ransohoff RM, Kivisakh P, Kidd G. Three or more routes for Leukocyte migration into the central nervous system. *Nat Rev Immunol*. 2003 Jul; 3(7):569-81
9. Thwaites GE, Nguyen DB, Nguyen HD, Huang TQ et al. Dexamethasone for the treatment of tubercular meningitis in adolescents and adults. *N Engl J Med*. 2004. Oct: 351 (17): 1741-51
10. Galea L, Bechmann I, Perry VH. What is immune privilege (not)? *Trends Immunol*. 2007 Jan; 28 (1): 12-8

11. Lopez B, Aquilar D, Oronzo H, Burger M, Espicia C et al: A marked difference in pathogenesis and immune response induced by different Mycobacterium Tuberculosis Genotypes. *Clin Exp Immunol* 2003 Jul; 133 (1): 30-7
12. Kalita J, Prasad S, Misra UK. Predictors of paradoxical tuberculoma in tuberculous meningitis. *Int J Tuberc Lung Dis.* 2014 Apr; 18 (4) 486-91
13. Prasad K, Singh MB. Corticosteroids for managing tubercular meningitis. *Cochrane Database Syst Rev*, 2008 Jan 23; (1): CD 002244
14. Thwaites GE, van Tearn R, Schoeman J. Tuberculous meningitis; more questions; still too few answers. *Lancet Neurol.* 2013 Oct; 12 (16): 999-1010
15. DeLance AR, Safae M, MC O, Clark AJ, Kaur G et al. Tuberculoma of the Central Nervous System. *J Clin Neurosci.* 2013; 20 (10): 1333-41
16. Tawares JL, Wangoo A, Dilworth P, Marshal B, Koteche S, Shaw RJ. Thalidomide reduces tumor necrosis factor- alpha production by human alveolar macrophages. *Respir Med.* 1997 Jan; 91 (1) 31-9
17. Arseni C. Two hundred and one cases of intracranial tuberculoma treated surgically. *J Neurol Neurosurg Psychiatry.* 1958. Nov; 21 (4): 308-11
18. Deretic V, Saitoh T, Akira S, Autophagy in infection, inflammation and immunity. *Nat Rev Immunol.* 2013 Oct; (10) 722-37
19. Andronikou S, Weiselthaler N. Modern imaging of tuberculosis in children: Thoracic, CNS and abdominal tuberculosis. *Pediatr Radiol* 2004, Nov, 34 (11): 861-75
20. Sharma SK, Mohan R, Kadhivaran T. HIV- TB coinfection. Epidemiology, diagnosis and amp; management. *Indian J Med Res.* 2005 Apr; 121 (4): 550-67
21. Thwaites GE, Nguyen DB, Nguyen HD, Hoang TQ et al. Dexamethasone for the treatment of Tuberculous meningitis in adolescents and adults. *N Engl J Med.* 2004. Oct 21. 351 (17) 1741-51
22. Wallis RS, Hafner R. Advancing host directed therapy for tuberculosis. *Nat Rev Immunol.* 2015 Apr. 15 (4) 255-63
23. Kim SH, Kim YS. Immunologic paradox in the diagnosis of tuberculous meningitis. *CI Vaccine Immunol* 2009 Dec 16 (12): 1847-9
24. Bhagwati SN. Ventriculo Atrial shunts in TB meningitis with hydrocephalus. *J Neurosurg.* 1971 Sep; 35 (3): 309-13
25. Sil K, Chatterjee S. Shunting in tuberculous meningitis. *Childs Nerv Syst* 2008 Sep; 24 (9) 1029-32 (119-25)
26. Rajshekhar V. Management of hydrocephalus in patients with hydrocephalus. *Neurol India.* 2009 Jul-Aug; 57 (4) :368-74
27. Figagi AA, Fieggen AG, Peter JC. Endoscopic third ventriculostomy in tuberculous meningitis. *Childs Nerv Syst* 2008 Sep; 24 (9): 1029-32 (119-25)
28. Warf BC. Comparison of endoscopic third ventriculostomy alone and combined with choroid plexus cauterisation in infants younger than one year of age: A prospective study in 550 African children. *J Neurosurg* 2005 Dec; 103 (6 suppl) 475- 81
29. Joseph VB, Raghuram L, Korah IP, Chacko AG. MR ventriculography for the study of CSF flow. *AJNR* 2003 Mar; 24 (3): 373-81
30. Traub M, Colchester AC, Kingsley DP, Swarsh M. Tuberculosis of the central nervous system. *Q J Med* 1984 Winter; 53 (209) 81-100

31. Akhadar A, El Hassani MY, Chakkir N, Jidane M. Optochiasmatic tuberculoma- complication of tubercular meningitis. Report of a case and review of literature. *Journal of Neuroradiology*. 2001; 28 (2): 137-142
32. Sinha MK, Garg RK, Anuragda HK, Agarwal A, Parihar A, Mandhani PA. Paradoxical vision loss associated with optochiasmatic tuberculoma in TB meningitis. A report of 8 patients. *J Infect*. 2010 Jun; 60 (6): 456-66
33. Chagla AS, Udayakumaran S, Balasubramaniam S. Cervical intramedullary tuberculoma in an infant. Case illustration. *J Neurosurg* 2007 Mar; 106(3 suppl):243-243  
Bargallo J, Bold TD, Ernst JD. Who benefits from granulomas; Mycobacteria or Host? *Cell* 2009 Jan 9; 136 (1) 17-9
34. Yen HL, Lee RJ, Chen HJ. Multiple tuberculomas in the brain and spinal cord: a case report. *Spine*. 2003 Dec 1 ;25 (23) E 499-502
35. Beremguer J, Garcia-Barrionvero J, UbedaB, BargalloN, Cardinal C, Mercader JM. The Target sign, Is it a specific sign of CNS tuberculoma? *Neuroradiology* 1996. Aug; 38(6) 547-50